

第33回日本形成外科学会基礎学術集会

/IPSRC

The 33rd Research Council Meeting of Japan Society of Plastic and Reconstructive Surgery/
The International Plastic Surgery Research Council (IPSRC)



The 9th Annual Congress of International Society of Plastic and Regenerative Surgeons: ISPRES
The Aesthetic and Antiaging Tokyo: TAAT

会期

2024年10月17日(木)～19日(土)

日本語プログラム

17日(木)～18日(金)

英語プログラム

17日(木)～19日(土)

会場

ヒルトン東京 お台場

〒135-8625 東京都港区台場 1-9-1 TEL : 03-5500-5500

会長

吉村 浩太郎 自治医科大学形成外科学講座

事務局長

素輪 善弘 自治医科大学形成外科学講座



運営事務局 株式会社MAコンベンションコンサルティング

〒102-0083 東京都千代田区麹町4-7 麹町パークサイドビル402



TEL

03-5275-1191

FAX

03-5275-1192

E-mail

contact-keisei2024@macc.jp

Number of
Blood Processing
Orders

84,186

(cumulative*)

Number of
Adipose Stem Cell
Culturing Orders

8,359

(cumulative*)

Number of
Partner Medical
Institutions

1,865

(cumulative*)

CellSource

Your Choice for Regenerative Medicine

* As of the end of April 2024

Please refer to the information below for company details, available via the QR code.



セルソース株式会社 CellSource Co., Ltd.

11F, SHIBUYA CAST., 1-23-21 Shibuya, Shibuya-ku,
Tokyo 150-0002 Japan

<https://www.cellsource.co.jp/en/>

Company Details



日本形成外科学会基礎学術集会 会長

第1回	1992年	弘前	弘前大学	形成外科	菅原 光雄
第2回	1993年	仙台	東北大学	形成外科	藤田 晋也
第3回	1994年	横浜	北里大学	形成外科	塩谷 信幸
第4回	1995年	倉敷	川崎医科大学	形成外科	森口 隆彦
第5回	1996年	長崎	長崎大学	形成外科	藤井 徹
第6回	1997年	大宮	埼玉医科大学総合医療センター	形成外科	原科 孝雄
第7回	1998年	高松	香川医科大学	形成外科	秦 維郎
第8回	1999年	東京	杏林大学	形成外科	尾郷 賢
第9回	2000年	名古屋	名古屋大学	形成外科	鳥居 修平
第10回	2001年	東京	東邦大学	形成外科	丸山 優
第11回	2002年	仙台	東北大学	形成外科	山田 敦
第12回	2003年	東京	慶應義塾大学	形成外科	中島 龍夫
第13回	2004年	浦安	順天堂大学	形成外科	梁井 皎
第14回	2005年	東京	千葉大学	形成外科	一瀬 正治
第15回	2006年	大宮	埼玉医科大学	形成外科	中塚 貴志
第16回	2007年	神戸	神戸大学	形成外科	田原 真也
第17回	2008年	東京	日本医科大学	形成外科	百束 比古
第18回	2009年	東京	聖マリアンナ大学	形成外科	熊谷 憲夫
第19回	2010年	横浜	横浜市立大学	形成外科	鳥飼 勝行
第20回	2011年	東京	東京医科大学	形成外科	渡辺 克益
第21回	2012年	福島	福島県立医科大学	形成外科	上田 和毅
第22回	2013年	新潟	新潟大学	形成外科	柴田 実
第23回	2014年	松本	信州大学	形成外科	松尾 清
第24回	2015年	森岡	岩手医科大学	形成外科	小林 誠一郎
第25回	2016年	大阪	関西医科大学	形成外科	楠本 健司
第26回	2017年	大阪	近畿大学	形成外科	磯貝 典孝
第27回	2018年	東京	日本大学	形成外科	仲沢 弘明
第28回	2019年	仙台	東北大学	形成外科	館 正弘
第29回	2020年	横浜	横浜市立大学	形成外科	前川 二郎
第30回	2021年	東京	北里大学	形成外科	武田 啓
第31回	2022年	岡山	岡山大学	形成外科	木股 敬裕
第32回	2023年	東京	埼玉医科大学総合医療センター	形成外科	三鍋 俊春
第33回	2024年	東京	自治医科大学	形成外科	吉村 浩太郎
第34回	2025年	鹿児島	昭和大学	形成外科	門松 香一
第35回	2026年	那覇	東京医科大学	形成外科	松村 一
第36回	2027年	未定	筑波大学	形成外科	関堂 充

一般社団法人日本形成外科学会 理事・監事

理事長：貴志 和生

理事：上村 哲司 岡崎 睦 小山 明彦 覚道奈津子 久保 盾貴
 小室 裕造 櫻井 裕之 櫻庭 実 鳥山 和宏 野口 昌彦
 橋本 一郎 松村 一 三川 信之 宮脇 剛司
 監事：梶川 明義 関堂 充

一般社団法人日本形成外科学会 名誉会員

朝戸 裕貴	磯貝 典孝	一瀬 正治	内沼 栄樹	大浦 武彦	大慈弥裕之
小川 豊	尾郷 賢	鬼塚 卓弥	上石 弘	亀井 譲	川上 重彦
木股 敬裕	清川 兼輔	楠本 健司	熊谷 憲夫	栗原 邦弘	小林誠一郎
塩谷 信幸	柴田 実	鈴木 茂彦	添田 周吾	館 正弘	谷野隆三郎
田中 克己	田原 真也	鳥居 修平	仲沢 弘明	中塚 貴志	中西 秀樹
西村 善彦	野崎 幹弘	原科 孝雄	波利井清紀	百束 比古	平野 明喜
平林 慎一	平山 峻	藤井 徹	藤野 豊美	保阪 善昭	細川 互
前川 二郎	松尾 清	丸山 優	森口 隆彦	山田 敦	渡辺 克益

一般社団法人日本形成外科学会 特別会員

内田 満 金子 剛 光嶋 勲 佐藤 兼重 松本 吉郎 吉村 陽子
 吉本 信也

一般社団法人日本形成外科学会 海外在住名誉会員

Whitaker, Linton Andin John Butler Mulliken Aufricht, G. Fogh-Anderson, Poul
 Fara, Miroslav Henry K, Kawamoto Jr.

一般社団法人日本形成外科学会 外国会員

J. D. Lew	J. Schrudde	D. C. Dibbell	R. C. Schults
J. G. McCarthy	L. O. Vasconez	H. Washio	G. I. Taylor
O. P. Maxwell	N. B. S. Tanner	L. N. Sekhar	G. Foucher
F. Nahai	D. J. Smith Jr.	J. A. Lilja	陳 明庭
J. P. Vacanti	B. S. Baik	Prakob Thongphiew	Beyong Yun Park
金 炳黙			

一般社団法人日本形成外科学会 評議員

赤松 正	秋田 新介	秋元 正宇	朝村 真一	東 隆一	安倍 吉郎
荒田 順	飯田 拓也	石田 勝大	伊藤 史子	伊藤 奈央	伊東 大
伊藤 文人	井上 義一	今井 啓道	上田 晃一	上村 哲司	宇佐美泰徳
梅澤 裕己	漆館 聡志	戎谷 昭吾	大浦 紀彦	大城 貴史	大守 誠
岡崎 睦	岡本 年弘	小川 令	荻野 晶弘	奥本 隆行	尾崎 峰
小野 真平	小山 明彦	垣淵 正男	覚道奈津子	檜村 勉	檜山 和也
梶川 明義	片平 次郎	勝部 元紀	加藤 久和	門田 英輝	門松 香一
河合建一郎	久徳 茂雄	貴志 和生	北山 晋也	久保 盾貴	窪田 吉孝
倉片 優	畔 熱行	桑原 理充	河野 太郎	小久保健一	小宮 貴子
小室 明人	小室 裕造	近藤 昭二	五石 圭一	齊藤 晋	榊原 俊介
櫻井 裕之	櫻庭 実	佐々木 薫	佐武 利彦	佐藤 伸弘	品岡 玲
島田 賢一	清水 史明	清水 雄介	杉本 孝之	清家 志円	関 征央
関堂 充	副島 一孝	素輪 善弘	高木 誠司	高木 信介	多久嶋亮彦
竹内 正樹	武田 啓	田中 克己	田中顕太郎	田中 里佳	田邊 毅
田港見布江	大安 剛裕	津下 到	寺尾 保信	寺師 浩人	時岡 一幸
土佐 泰祥	富田 興一	富塚 陽介	鳥谷部莊八	鳥山 和宏	中川 雅裕
永竿 智久	永松 将吾	西村 礼司	塗 隆志	根本 充	野口 昌彦
野村 正	橋川 和信	橋本 一郎	羽多野隆治	浜島 昭人	林 明照
林 礼人	林 利彦	林 稔	林田 健志	原岡 剛一	兵藤伊久夫
樋口 慎一	日原 正勝	福田 憲翁	藤岡 正樹	藤原 雅雄	舟山 恵美
古川 洋志	本多 孝之	前田 拓	松崎 恭一	松田 健	松峯 元
松村 一	松本 洋	水野 博司	三川 信之	三鍋 俊春	宮本 慎平
宮本 純平	宮脇 剛司	元村 尚嗣	森 秀樹	森 弘樹	森岡 康祐
守永 圭吾	森本 尚樹	矢澤 真樹	矢野 智之	八巻 隆	山下 修二
山下 昌信	山中 浩気	山本 直人	山本 有平	杠 俊介	吉村浩太郎
四ッ柳高敏	力丸 英明	渡辺あずさ			

一般社団法人日本形成外科学会 理事長指名議員

青木 恵美	岸邊 美幸	黒木 知明	権太 浩一	高須 啓之	辻 依子
中井 國博	成島 三長	沼尻 敏明	馬場 香子	藤井 美樹	牧口 貴哉
増口 信一	松井 瑞子	宮内 律子	百澤 明	八木俊路朗	吉龍 澄子
若槻 華子	渡邊 理子				

一般社団法人 日本形成外科学会 各種委員会

(2023 年度・2024 年度)

(1) 財 務 委 員 会【 6 名】

岡崎 睦（委員長） 赤松 正、多久嶋亮彦、武田 啓、前田 拓、松田 健

(2) 専門医認定委員会【24名】+担当理事1名

奥本 隆行（委員長） 漆舘 聡志、大浦 紀彦、荻野 晶弘、小野 真平、檜山 和也
岡崎 睦（担当理事） 門田 英輝、門松 香一、河野 太郎、齊藤 晋、佐武 利彦
高木 誠司、富田 興一、中川 雅裕、永竿 智久、塗 隆志
野村 正、橋川 和信、林 礼人、舟山 恵美、水野 博司
山下 修二、山下 昌信、力丸 英明

(3) 専門医生涯教育委員会【13名】

野口 昌彦（委員長） 秋元 正宇、大守 誠、奥本 隆行、片平 次郎、小室 明人
竹内 正樹、土佐 泰祥、羽多野隆治、浜島 昭人、福田 憲翁
三川 信之、森本 尚樹

(4) 専門医試験問題作成委員会【25名】+担当理事1名

門田 英輝（委員長） 飯田 拓也、石田 勝大、伊東 大、伊藤 文人、宇佐美泰徳
宮脇 剛司（担当理事） 戎谷 昭吾、大守 誠、尾崎 峰、上菌 健一、北山 晋也
窪田 吉孝、黒木 知明、小久保健一、齊藤 晋、富田 興一
中井 國博、永松 将吾、浜島 昭人、林 稔、舟山 恵美
牧口 貴哉、松井 瑞子、宮本 純平、守永 圭吾

(5) 認定施設認定委員会【16名】

小室 裕造（委員長） 秋元 正宇、朝村 真一、今井 啓道、垣淵 正男、櫻庭 実、
品岡 玲、清水 雄介、土佐 泰祥、兵藤伊久夫、古川 洋志、
松田 健、宮本 慎平、元村 尚嗣、森 秀樹、四ッ柳高敏

(6) 指導医認定委員会【 6 名】

宮脇 剛司（委員長） 安倍 吉郎、伊東 大、田中 里佳、西本 聡、林 利彦

(7) 学 術 委 員 会【18名】

松村 一（委員長） 青木 昂平、小川 令、小山 明彦、檜山 和也、加藤 達也
小久保健一、清水 雄介、土佐 泰祥、成島 三長、野村 正
林 利彦、林田 健志、松峯 元、三川 信之、宮本 純平
八巻 隆、吉龍 澄子

(8) ガイドライン委員会【15名】

鳥山 和宏（委員長） 青木 恵美、朝村 真一、漆舘 聡志、大城 貴史、大守 誠
小林 眞司、権太 浩一、佐久間 恒、佐武 利彦、時岡 一幸
西関 修、森 秀樹、八木俊路朗、杠 俊介

(9)-1 日形会誌編集委員会【42名】

櫻庭 実（委員長） 浅野 裕子、朝村 真一、東 隆一、荒田 順、宇佐美泰徳
漆舘 聡志、戎谷 昭吾、大守 誠、小野 真平、覚道奈津子
檜山 和也、久徳 茂雄、窪田 吉孝、桑原 理充、榊原 俊介
佐藤 伸弘、関 征央、副島 一孝、高須 啓之、時岡 一幸
富田 興一、鳥谷部莊八、中井 國博、永竿 智久、塗 隆志
羽多野隆治、林 利彦、樋口 慎一、兵藤伊久夫、藤岡 正樹
牧口 貴哉、松崎 恭一、松峯 元、宮本 純平、森 秀樹
守永 圭吾、森本 尚樹、安永 能周、山中 浩気、山本 直人
吉龍 澄子

(9)-2 Journal of Plastic and Reconstructive Surgery 編集委員会【55名】+担当理事1名

多久嶋亮彦（委員長） 安倍 吉郎、荒田 順、荒牧 典子、飯田 拓也、上村 哲司
小室 裕造（担当理事） 大浦 紀彦、大城 貴史、大塚 尚治、小川 令、覚道奈津子
加藤 久和、門田 英輝、河合建一郎、木股 敬裕、久保 盾貴
窪田 吉孝、権太 浩一、齊藤 晋、坂本 道治、櫻庭 実
佐藤 伸弘、清水 史明、副島 一孝、素輪 善弘、高成 啓介
田中 一郎、田中 克己、田中 里佳、津下 到、土佐 泰祥
富田 興一、鳥山 和宏、中塚 貴志、沼尻 敏明、橋川 和信
橋本 一郎、林 明照、藤井 美樹、藤岡 正樹、藤原 敏宏
古川 洋志、堀 圭二郎、本多 孝之、前田 大介、松崎 恭一
松末 武雄、松村 一、水野 博司、元村 尚嗣、森本 尚樹
八巻 隆、山田 潔、山本 匠、吉村浩太郎

(10) 渉外・広報委員会【15名】

小山 明彦（委員長） 今井 啓道、漆舘 聡志、岡本 年弘、小川 令、樫村 勉
岸邊 美幸、坂本 好昭、関 征央、鳥山 和宏、西本 聡
橋川 和信、原岡 剛一、松本 洋、森岡 康祐

(10)－(i) 形成外科キャンペーンワーキンググループ【18名】+担当理事1名

清水 雄介（委員長） 安倍 吉郎、漆舘 聡志、奥本 隆行、片平 次郎、小林 尚史
小山 明彦（担当理事） 品岡 玲、島田 賢一、大安 剛裕、高木 誠司、辻 依子
鳥山 和宏、中川 雅裕、永松 将吾、福田 憲翁、牧口 貴哉
松井 瑞子、松本 洋

(11) 国際委員会【14名】+担当理事1名

小川 令（委員長） 秋田 新介、浅野 裕子、今井 啓介、小野 真平、貴志 和生
松村 一（担当理事） 河野 太郎、関 征央、素輪 善弘、田中 里佳、橋本 一郎
水野 博司、矢野 智之、吉村浩太郎

(12) 社会保険委員会【29名】+担当理事1名、顧問2名

島田 賢一（委員長） 秋元 正宇、飯田 拓也、伊藤 奈央、伊藤 文人、大城 貴史
上村 哲司（担当理事） 荻野 浩希、尾崎 峰、垣淵 正男、勝部 元紀、加藤 久和
金子 剛（顧問） 畔 熱行、佐武 利彦、清家 志円、高木 信介、田邊 毅
関堂 充（顧問） 土佐 泰祥、永松 将吾、二ノ宮邦稔、沼尻 敏明、野村 正
日原 正勝、本多 孝之、前田 拓、松田 健、矢澤 真樹
山本 直人、杠 俊介、渡辺あずさ

(13) 倫理委員会【7名】+外部委員3名

上村 哲司（委員長） 東 隆一、五石 圭一、副島 一孝、田中 克己、四ッ柳高敏
力丸 英明
（外部委員） 大磯義一郎、北河 隆之、松村 由美

(11)－(i) 遺伝性疾患関連WG【5名】+外部委員1名

野口 昌彦（委員長） 上田 晃一、小林 眞司、田中 克己、楊井 哲
（外部委員） 高木紀美代

(14) 制度検討委員会【7名】

久保 盾貴（委員長） 伊藤 奈央、垣淵 正男、櫻井 裕之、清家 志円、田中 克己、
森本 尚樹

(15) 企画調査委員会【14名】+担当理事1名

林 礼人（委員長） 小川 令、荻野 晶弘、小野 真平、岸邊 美幸、北山 晋也
櫻井 裕之（担当理事） 小林 尚史、品岡 玲、高木 信介、田邊 毅、田港見布江
成島 三長、松本 健吾、宮内 律子

(16) データベース委員会【15名】+担当理事1名

元村 尚嗣（委員長） 赤松 正、秋田 新介、秋元 正宇、朝村 真一、今井 啓道
櫻庭 実（担当理事） 五石 圭一、近藤 昭二、佐武 利彦、素輪 善弘、大安 剛裕
富塚 陽介、塗 隆志、根本 充、羽多野隆治

(17) 将来計画委員会【12名】+担当理事1名

垣淵 正男（委員長） 東 隆一、岡本 年弘、岸邊 美幸、佐藤 誠、西村 礼司
櫻井 裕之（担当理事） 馬場 香子、林 礼人、林田 健志、本多 孝之、水野 博司
力丸 英明

(18) 医療安全推進委員会【6名】

鳥山 和宏（委員長） 田中 克己、田港見布江、林田 健志、増口 信一、四ッ柳高敏

(19) 皮膚腫瘍外科分野指導医認定委員会【15名】+担当理事1名

古川 洋志（委員長） 荻野 晶弘、加藤 久和、木村 中、桑原 理充、田中顕太郎
小山 明彦（担当理事） 野村 正、林 礼人、林 利彦、藤岡 正樹、藤原 雅雄
前田 拓、牧口 貴哉、森 秀樹、吉龍 澄子

(20) 小児形成外科分野指導医認定委員会【13名】

野口 昌彦（委員長） 久徳 茂雄、小林 眞司、齊藤 晋、佐々木 薫、杉本 孝之
高木 信介、時岡 一幸、永竿 智久、羽多野隆治、藤原 雅雄
本多 孝之、渡辺あずさ

(21) 再建・マイクロサージャリー分野指導医認定委員会【13名】+担当理事1名

中川 雅裕（委員長） 伊東 大、黒木 知明、清水 史明、高須 啓之、田中顕太郎
櫻庭 実（担当理事） 津下 到、寺尾 保信、鳥谷部莊八、中井 國博、林 利彦
日原 正勝、山本 直人

(22) レーザー分野指導医認定委員会【10名】+担当理事1名

河野 太郎（委員長） 大城 貴史、王丸 陽光、西村 礼司、野村 正、羽多野隆治
覚道奈津子（担当理事） 古川 洋志、堀 圭二郎、百澤 明、若槻 華子

(23) キャリア支援委員会【19名】

覚道奈津子（委員長） 伊藤 史子、岡本 年弘、垣淵 正男、檜村 勉、片平 次郎
岸邊 美幸、小宮 貴子、佐々木 薫、田中 里佳、辻 依子
寺師 浩人、永松 将吾、馬場 香子、三川 信之、森本 尚樹
若槻 華子、渡辺あずさ、渡邊 理子

(24) ブレストインプラントガイドライン管理委員会【10名】+担当理事1名

森 弘樹（委員長） 梅澤 裕己、窪田 吉孝、小宮 貴子、佐武 利彦、田港見布江
久保 盾貴（担当理事） 寺尾 保信、富田 興一、牧口 貴哉、三鍋 俊春

(25) 美容医療に関する委員会【12名】+担当理事1名

原岡 剛一（委員長） 井上 義一、尾崎 峰、勝部 元紀、門松 香一、倉片 優
小室 裕造（担当理事） 黒木 知明、櫻井 裕之、清水 雄介、武田 啓、水野 博司
力丸 英明

(26) 動画コンテンツ検討委員会【14名】

三川 信之（委員長） 東 隆一、小野 真平、梶田 大樹、片平 次郎、島田 賢一
永松 将吾、橋川 和信、橋本 一郎、樋口 慎一、松田 健
松峯 元、松本 洋、山中 浩気

(27) C S T 委員会【14名】

三川 信之（委員長） 秋田 新介、井上 義一、今井 啓道、今西 宣晶、葛城 遼平
清水 史明、津下 到、寺師 浩人、中川 雅裕、沼尻 敏明
松本 洋、三鍋 俊春、元村 尚嗣

(27)－(i) 顔面移植WG【14名】+担当理事1名

橋川 和信（委員長） 安倍 吉郎、石田 勝大、井上 義一、小野 真平、坂本 好昭
三川 信之（担当理事） 櫻庭 実、清水 史明、根本 仁、林 礼人、原岡 剛一
日原 正勝、元村 尚嗣、山路 佳久

(28) 形成外科ロボット手術検討委員会【35名】

上村 哲司（委員長） 赤松 正、浅野 裕子、井上 義一、梅本 泰孝、大河内真之
小野 真平、樫村 勉、加藤 久和、門田 英輝、金山 幸司
岸 慶太、北 幸紘、坂原 大亮、佐武 利彦、素輪 善弘
高成 啓介、田代 絢亮、堂後 京子、丹羽 幸司、沼尻 敏明
根本 仁、橋川 和信、東野 琢也、松村 一、三上 太郎
宮本 慎平、村井 信幸、村木 健二、森 裕晃、矢澤 真樹
矢野 智之、山下 修二、山本 直人、吉田 周平

(29) 専門医制度委員会【10名】

貴志 和生（委員長） 岡崎 睦、奥本 隆行、門田 英輝、久保 盾貴、小室 裕造
櫻井 裕之、野口 昌彦、橋本 一郎、森本 尚樹

会長挨拶

会長 吉村 浩太郎

自治医科大学形成外科学講座 教授



このたび、日本形成外科学会（JSPRS）の基礎学術集会を担当することになりました。研究は、医療の発展のためには欠かせないものです。研究のヒントは臨床から生まれ、研究の成果は臨床に還元されます。Inspired from Bed, Explore and Innovate at Lab という英語のサブタイトルを掲げました。

今回は、挑戦的な試みとして、米国 Plastic Surgery Research Council (PSRC) や欧州 European Plastic Surgery Research Council (EPSRC) の基礎学会と合同開催 International Plastic Surgery Research Council (IPSRC) をすることになります。海外から50名を超える著名な招待演者が現地参加を予定しております。会場は、両国際空港（成田国際空港、羽田空港）からのアクセスの良いお台場の、ヒルトン東京お台場です。国内からでも飛行機で東京に来られる方には、羽田空港から10分の至便な会場です。

さらに、現在のトピックである再生医療を扱う国際形成再生外科学会（ISPRES）の年次集会と美容・抗加齢に関するイベント（TAAT）を同時に3日間の予定で開催いたします。International Society of Plastic Regenerative Surgeons (ISPRES) というのは、脂肪移植、幹細胞、再生医療の臨床をメインとした形成外科医だけの学会で、米国形成外科学会（ASPS）の連携学会です。ISPRES と TAAT では、アジア、米国、欧州のエキスパートを交えて、教育セミナーやシンポジウムだけでなく、一般演題も含めて、最新の臨床技術の情報交換の場となります。

7会場のうち、4会場は国際学会会場として原則英語ですが、同時ライブ配信と同時通訳が入ります。4会場はライブ配信も行いますので、ご自分のスマホで言語を選んで、聞くことが可能です。スマホのイヤホン忘れずにご持参ください。ご自分のパソコンやスマホのアプリから、テレビを見る要領でチャンネルを変えながら各会場をご覧いただくことも可能ですし、そこから質問をしていただくことも可能です。ご自宅からでも海外からでも、簡単にご参加いただくことが可能となっております。

残りの3会場は、日本語会場で、通常のエデュケーション、研究シンポジウムや各委員会プログラム、ガイドラインプログラム、専門医の共通講習、スポンサープログラムも組まれます。育児をする参加者のために、託児所も3日間ホテル内の別フロアで完備しております。

今回の3イベント同時開催では、形成外科のこれからを作る国際的イノベーション、再生医療、美容、アンチエイジングと高い関心を集める分野に焦点を当て、記念すべきスタートとなるように期待しております。2023年にアジア9か国（日本、韓国、台湾、フィリピン、タイ、マレーシア、インドネシア、シンガポール、パキスタン）の形成外科学会加盟で発足した APRAS（アジア形成外科学会連盟）のセッションも、3つのイベントすべてで実施されます。

本学術集会の開催趣旨をお汲み取りいただき、演題募集要項の内容にて、是非ともご支援・ご協力を賜りますようお願い申し上げます。末筆ながら、皆様方のますますのご発展とご健康を心よりお祈り申し上げます。

2024年4月



同時通訳付きの国際学会として開催します。

英語の苦手な方でもすべて同時通訳がありますので、気軽に楽しめます。スマホのイヤホンをお忘れなく！
数十名の国際的に著名な形成外科医が集まりますので、交流するチャンスです。



ペーパーレスのデジタルイベントです

首から下げる参加章以外は原則としてデータのみです。パソコンとスマホ、イヤホンが重要になります。プログラムや抄録もパソコンのPDFやスマホのアプリになります。ライブ配信もそこからご覧いただけます。



脂肪移植の国際学会(ISPRES)、美容と抗加齢のイベント(TAAT)も同時開催です。

研究に興味のない方でもお楽しみいただけます。やはり同時通訳がありますので安心です。



英語プログラムはライブ配信です

Zoom Events の1つの画面からマルチチャンネルでご覧いただけます。

50%
OFF

専攻医は半額です。

国際学会のため参加費が通常より高いですが、専攻医は半額です。日本語プログラムだけの方も半額です。



ネクタイ不要です。

研究者は世界中、カジュアルな服装です。気軽にご来場ください。

詳しくはHP(<https://www.ipsrc.org/jp/>)をご覧ください。

開催概要

大会名称

第33回日本形成外科学会基礎学術集会

The 33rd Research Council Meeting of Japan Society of Plastic and Reconstructive Surgery

IPSRC(国際形成基礎学術集会)

The 1st International Plastic Surgery Research Council (IPSRC)

併催

ISPRES(国際形成再生外科学会年次学術集会)

The 9th Annual Congress of International Society of Plastic and Regenerative Surgeons (ISPRES)

TAAT(東京美容抗加齢集会)

The 1st Aesthetic and Antiaging Tokyo (TAAT)

テーマ

Inspired from Bed, Explore and Innovate at Lab

開催日

2024年10月17日(木)～19日(土)

日本語プログラム

17日(木)～18日(金)

英語プログラム

17日(木)～19日(土)

会場

ヒルトン東京 お台場

〒135-8625 東京都港区台場1-9-1 TEL: 03-5500-5500

会長

吉村 浩太郎

自治医科大学形成外科学講座

事務局長

素輪 善弘

自治医科大学形成外科学講座

運営事務局

株式会社MAコンベンションコンサルティング

〒102-0083 東京都千代田区麹町4-7 麹町パークサイドビル402

TEL: 03-5275-1191 FAX: 03-5275-1192 E-mail: contact-keisei2024@macc.jp



電車をご利用の場合

- 新交通ゆりかもめ「台場駅」直結
- りんかい線「東京テレポート駅」徒歩約10分



空港リムジンバス(有料)

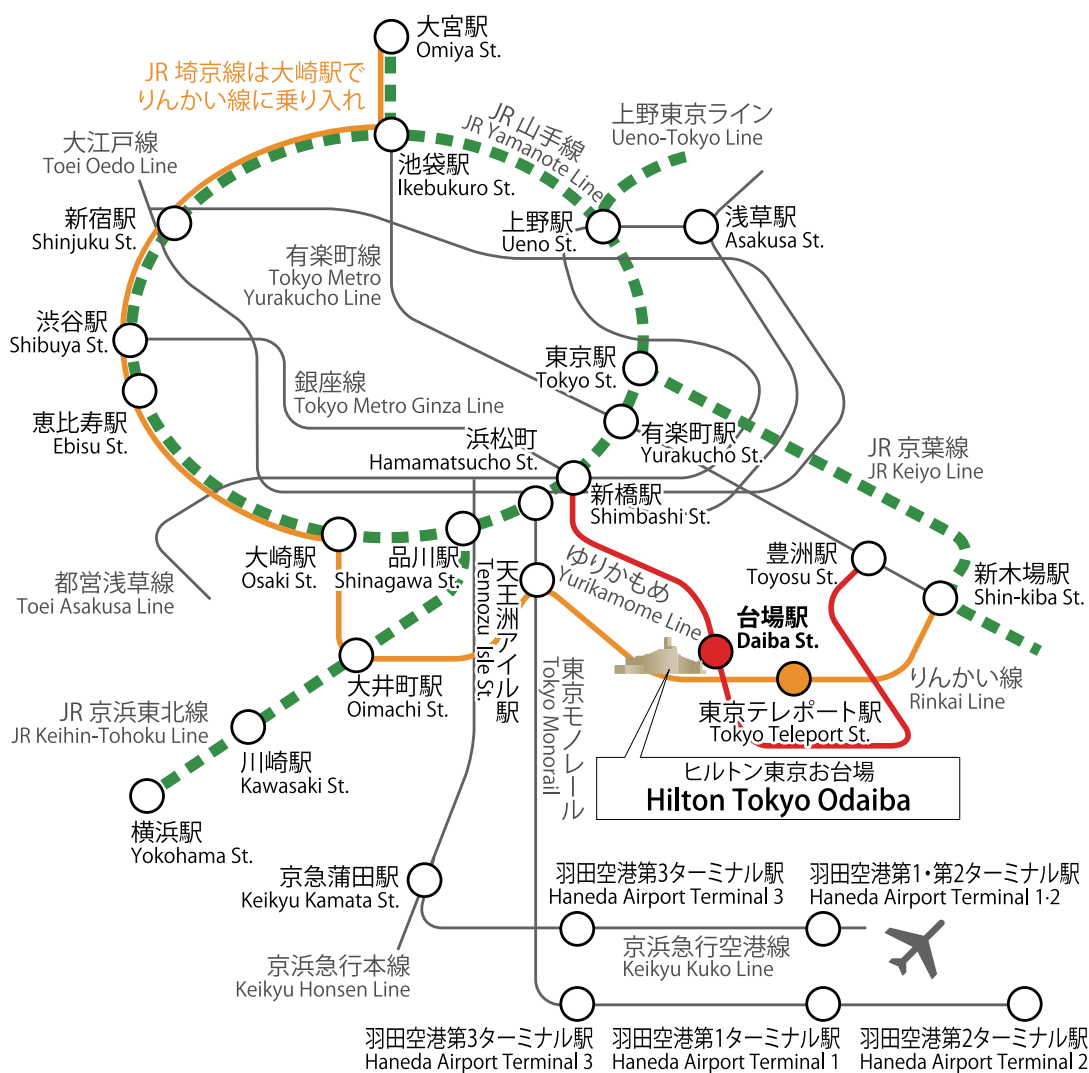- 東京国際空港(羽田)より約20分
- 成田国際空港(成田)より約75分



お台場レインボーバス(有料)

- 東京国際空港(羽田)より約20分
- 成田国際空港(成田)より約75分
- JR品川駅より約17分

交通案内図



タクシーをご利用の場合

JR 新橋駅から	約 15 分
JR 品川駅から	約 20 分
JR 東京駅から	約 20 分
銀座駅から	約 20 分
羽田空港から（高速道路利用）	約 15 分

お台場レインボーバスをご利用の場合

品川駅港南口（東口）～ヒルトン東京お台場 …… 約 30 分

参加登録

		早期割引登録	通常参加登録
JSPRS 会員， JSAS 会員 ¹⁾	標準登録 (現地参加・ライブ配信・オンデマンド配信)	4万円	4万5千円
	オンデマンド配信のみ	3万5千円	3万5千円
	国内セッションのみ参加 (現地参加のみ)	1万8千円	2万円
非会員	標準登録 (現地参加・ライブ配信・オンデマンド配信)	5万5千円	6万円
	オンデマンド配信のみ	5万円	5万円
	国内セッションのみ参加 (現地参加のみ)	2万5千円	3万円
形成外科専攻医 ¹⁾ メディカルスタッフ (要証明書添付*)	標準登録 (現地参加・ライブ配信・オンデマンド配信)	2万円	2万円
	オンデマンド配信のみ	1万5千円	1万5千円

1) 学会員は、参加登録の際に会員番号が必要になりますので、ご用意ください。

* 形成外科専攻医・メディカルスタッフの方は、所定の身分証明書の添付が必要となります。
ご準備のうえ参加登録を開始してください。
形成外科専攻医・メディカルスタッフ 証明書
https://gakkai.macc.jp/jsprs-kiso/2024/jp/doc/ipsrc2024_certificate.pdf

参加登録期間

早期割引登録 : 2024年6月1日(土) ～ 2024年9月30日(月)
通常参加登録 : 2024年10月1日(火) ～ 2024年10月31日(木)

参加登録ページ

インターネットを用いた「オンライン登録(クレジットカード決済)」でのみ受付いたします。
<https://gakkai.macc.jp/jsprs-kiso/2024/jp/>

演題登録

演題募集は終了しました。

たくさんのご応募ありがとうございました。

一般演題では、最優秀演題セッションが4つのトラック(JPSRC、IPSRC、ISPRES、TAAT)すべてにあります。それぞれのセッションで、座長2名と審査員3名の計5名で審査を行い、最優秀演題を表彰します。

プログラム

7会場のうち、3会場は日本語プログラム、4会場は国際プログラムとなります。日本語プログラムは、会場開催のみで、ライブ配信はございません。国際学会の会場は原則英語となりますが、同時ライブ配信と同時通訳が入ります。また、ライブ配信では、ご自分のスマホやパソコンで言語を選んで、聞くことが可能です。

会場	10月17日(木) 9:00-18:00	10月18日(金) 9:00-18:00	10月19日(土) 9:00-18:00	言語(日本語・英語)	内 容	同時通訳	ライブ配信	オンデマンド配信
1	基礎1	基礎1		日	研究、学会企画	—	—	+
2	基礎2	基礎2		日	研究、学会企画	—	—	+
3	IPSRC2	IPSRC2		英	研究	日	+	+
5	基礎3	基礎3		日	研究、学会企画	—	—	+
6	IPSRC1	IPSRC1	IPSRC1	英	研究	日	+	+
7	ISPRES	ISPRES	ISPRES	英	脂肪と幹細胞	日/中	+	+
8	TAAT	TAAT	TAAT	英	美容と抗加齢	日/中	+	+



見逃し配信もあります(日本語、英語7会場全て):

すべてのセッションは質疑も含めて、10月31日まで制限なく視聴が可能です。録画やダウンロードはできません。領域講習受講も可能です(見逃し受講による単位取得にはレポートの提出要)。



各会場別のプログラム

具体的なプログラム内容の詳細はこちらの Zoom Events からご覧ください(メールアドレスの認証が必要です)。参加登録後は、送られてくる本番用Zoom Eventsにご自分のアカウントで入場することで、すべてのライブ視聴、見逃し視聴が可能になります。

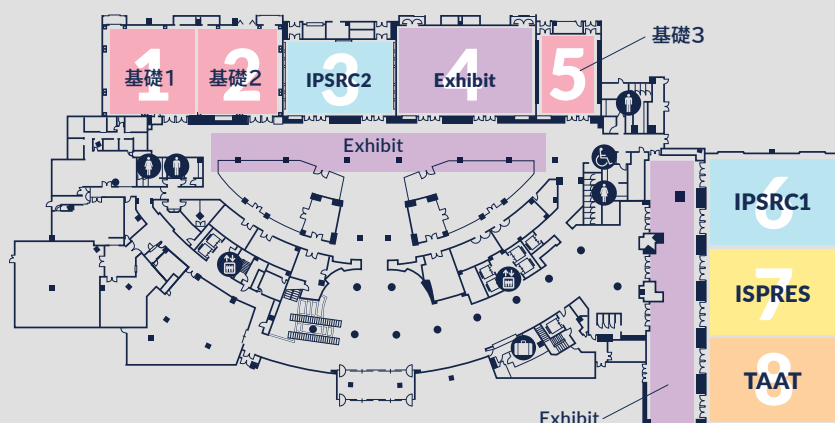
フロアプラン

ヒルトン東京お台場 / 1階

〒135-8625 東京都港区台場1-9-1

TEL: 03-5500-5500

7つのプログラム会場、1つの展示会場は、すべて宴会場フロア(1階)です。



基礎学術集会に参加される方へ

1) 参加受付

- ・参加受付は、すべてオンライン登録とさせていただきます。学会ホームページより、オンライン参加登録・決済を完了してください。会場では参加登録を行いませんので、ご注意ください。
- ・参加登録完了後、自動配信メールが送信されます。メールに記載の QR コード（参加章引換券）を印刷もしくはスマートフォン等にダウンロードして、当日会場にお持ちください。受付で QR コードを使って、参加章を印刷します。メールが届かない場合は、ホームページよりお問合せください。

2) 現地会場への入場

- ・①国内プログラムのみの参加登録、②日英プログラム参加登録（標準登録）、のどちらかによって、参加章とストラップの色が異なります。①の場合は、英語プログラムの第3、6、7、8会場への現地入場はできません。

3) オンライン会場への入場

- ・①の方も②の方も、Zoom Events にご自分のアカウントで入場することで、デジタルプログラムを利用できます。バーチャル展示会場や E ポスターもご覧いただけます。
- ・この**本番用の Zoom Events リンク**は、標準登録の方は <https://bit.ly/47GLSmC>、国内プログラムのみの登録の方は <https://bit.ly/3XYmeqd> から入場可能です(入場には、必ず参加登録で使用了 E メールアドレスを Zoom ID か E メール認証に使用してください。そうでないと、入れません。)."オンデマンド配信のみ"で参加登録した方には、リンクを 10 月 19 日正午にお送りします。
- ・下記の QR コードからも同じく入場が可能です。1 アカウントにつき、同時に 1 つのデバイスでしか入場ができなくなっております。お早目の参加登録と Zoom Events 入場で、事前の確認をお願いいたします。登録種類が異なると、ご自分のアカウントでは入場できませんのでご注意ください。オンデマンド配信のみの参加登録の方は、別途専用リンクが送られることになっております。



参加登録前



標準参加登録後



国内のみ参加登録

4) ライブ配信、同時通訳の視聴

- ・②日英プログラム参加登録（標準登録）の場合は、ご自分のスマホあるいは PC を使って、上記の本番用 Zoom Events にご自分のアカウントで入場することで、英語プログラムの第3、6、7、8会場のライブ配信と同時通訳の視聴が可能です。同時通訳は、音声あるいは字幕で利用することが可能です。くれぐれも**イヤホンをお忘れずにお持ちください。**

5) 共通講習、領域講習の現地受講

・各講習のスケジュールはオンラインプログラム（PDF や Zoom Events）で確認してください。現地受講完了の後、出口で IC カードリーダーに会員カードをかざして、受講登録を行ってください。分野指導医セミナーでは、入室・退室時（2 回）出席確認が必要になりますので、ご注意ください。

6) オンデマンド配信（10 月 22 日（火）より 10 月 31 日（木）まで利用可能）

および共通・領域講習の受講

・①国内プログラムのみの参加登録の方は、Zoom Events にご自分のアカウントで入場することで、国内プログラムのオンデマンド配信の視聴が可能です。各セッションの内容説明の中に、録画映像へのリンクがあり、そちらをクリックすることにより視聴が可能です。

・②日英プログラム参加登録（標準登録）の方は、本番用 Zoom Events にご自分のアカウントで入場することで、日英プログラムのオンデマンド配信の視聴が可能です。“**オンデマンド配信のみ**”で参加登録した方には、リンクを 10 月 19 日正午にお送りします。

・**領域講習**；現地受講とは異なり、対象のセッションをオンライン視聴後に、**受講フォーム**をダウンロードして、学習内容を E メールで提出する（提出先：keisei-office@jichi.ac.jp）が必要になります。

・**共通講習**：学術集会ホームページより、共通講習の視聴サイトにお進みください。参加登録時にご登録いただいたログイン ID とパスワードが必要となります。単位取得のためには、対象セッションを最後まで視聴し、設問回答（5 問 5 択に 80%以上正解すること）をもって単位を付与いたします（※設問は合格するまで何度でもご回答いただけます）。

ポケットーク同時翻訳の使い方


(英語プログラム：第3, 6, 7, 8会場)

1. 準備

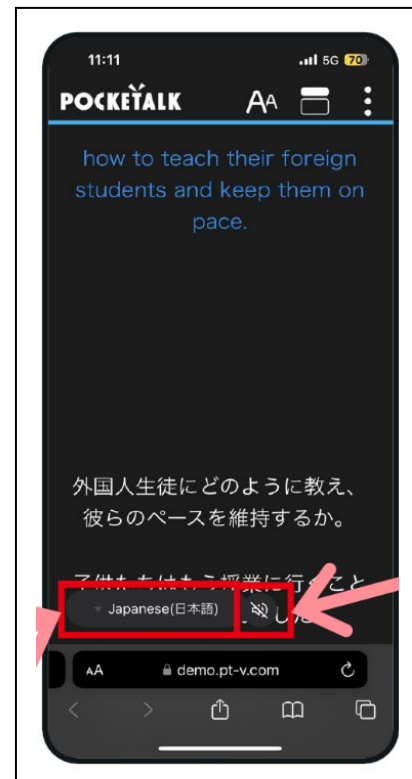
スマートフォンとイヤホンを用意してください。現地参加の場合も、ライブ配信の視聴も同じです。オンデマンド配信では利用できません（Zoom の字幕による同時通訳が利用できます）。

2. 利用方法

①**QR コードのスキャン**：プロジェクターに表示される QR コードをお手持ちのスマートフォンでスキャンします。スキャン後、自動的にスマートフォンのブラウザが開き、ポケットークの画面になります。



②**言語と音声の選択**：最下部で言語の選択と音声の ON/OFF ボタンを選択してください。言語は数十か国語から選択可能です。



③**同時通訳の聴取**：発表者が話す内容がポケットークを通じてリアルタイムで通訳されます。スマホの画面に翻訳テキストを表示することも可能ですし、イヤホンを使って翻訳音声のを聴くことも可能です。

座長および演者の方へ

1. 座長の方へ

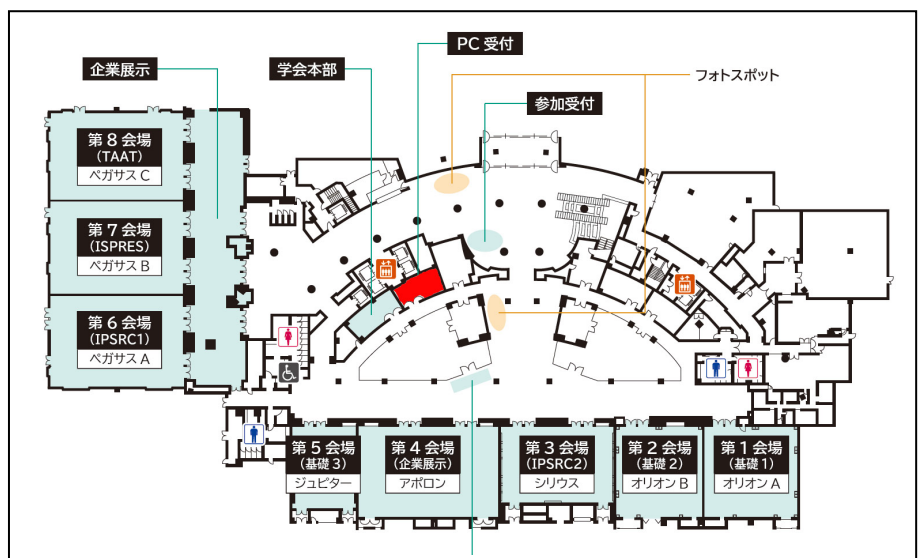
- ・発表順、各演者の発表順、発表内容を事前にご確認ください。ご不明の点があれば、事務局にご連絡ください。国際セッションの座長は外国人 1 名、日本人 1 名の 2 名です。
- ・一般演題セッションの発表時間は、日英ともに各自 **7 分+質疑 3 分**です。Keynote lecture は、15 分発表+質疑 5 分です（ごく一部に 25 分発表+質疑 5 分があります）。
- ・当日は、座長受付はありません。セッション開始 15 分前までに会場内の次座長席にご着席いただき、進行係と打ち合わせをしてください。**PC トラブルなど必要によっては、発表順を変更したり、欠演扱いとして進行してください。**くれぐれも、**定刻どおりのセッション進行にご協力ください。**

2. 演者の方へ（PC 発表）

- ・参加受付後、ご発表セッション開始予定時刻の 30 分前までに、PC（Windows、Mac とも可能）をお持ち込みの上、PC 受付を行ってください。PC の作動と出力は、演者の責任の下でご確認ください。
- ・各自 PowerPoint（同等のアプリケーション）で、ご発表ください。発表スライドは、16：9 です。4:3 の場合はスクリーンの両サイドが黒くなります。PowerPoint の「発表者ツール」機能は使用できません。
- ・ビデオや音声の使用は可能ですが、ご自身の PC で問題なく機能することを事前に確認してください。
- ・**出力は HDMI 端子のみとなります**ので、ご注意ください。PC に HDMI 端子が無い場合は、必ず変換アダプターをご用意ください。
- ・ご発表セッション開始 10 分前までに、会場内左手前方の AV 担当に PC と電源ケーブルを預けて、「次演者席」にご着席ください。本番で PC の作動に不良がある場合は、欠演になることがありますので、ご了承ください。
- ・**利益相反については、発表内の第 2 スライドで必ず開示してください。**

3. PC 受付について 1 階「董」の部屋（フロアマップをご覧ください）

10 月 17 日(木) 8:20～17:30
10 月 18 日(金) 8:20～17:30
10 月 19 日(土) 8:20～17:30



日本語プログラム – 10 月 17 日（木）

	第 1 会場（ Room 1 ）	第 2 会場（ Room 2 ）	第 5 会場（ Room 5 ）
9:00			
	09:00-10:30 シンポジウム 1 【領域講習】 Bench to Bedside:慢性創傷への新しいアプローチ！	09:00-10:10 一般演題 2 皮弁・マイクロサージャリー 座長：高成啓介	
10:00			
	休憩（20 分）		
11:00	10:50-12:10 一般演題 1 腫瘍・移植ほか 座長：金山幸司	10:10-12:10 シンポジウム 2 【領域講習】 外科医による大型研究資金獲得-死の谷を越えるコツ	10:00-11:40 一般演題 6 血管・リンパ管 座長：品岡 玲
12:00			11:40-12:10 協賛ミニセミナー 1 共催：アツヴィ合同会社
	休憩（10 分）	休憩（10 分）	
13:00	12:20-13:20 ランチョンセミナー 1 共催：マーベラスビューティージャパン株式会社	12:20-13:20 ランチョンセミナー 2 共催：PRSS Japan 株式会社	
	13:20-14:00 教育講演 1 木股敬裕/ Why, What が生み出す研究・臨床、そして自游	13:20-14:20 共通講習 1 (医療倫理) 児玉 聡/現代社会の医療倫理	
14:00	休憩（10 分）		13:50-14:20 協賛ミニセミナー 2 共催：株式会社セルバンク
	14:10-15:40 シンポジウム 3 【領域講習】 形成外科医が基礎研究を始めるための第一歩-研究室立ち上げノウハウ	休憩（10 分）	14:20-14:50 協賛ミニセミナー 3 共催：Dermato Plastica Beauty, Co. LTD
15:00		14:30-15:40 一般演題 3 皮膚創傷治癒 1 座長：坂本道治	休憩（10 分）
	休憩（10 分）		15:00-17:00 ガイドライン委員会企画 【領域講習】 乳房再建 リンパ浮腫
16:00	15:50-17:20 皮膚腫瘍外科分野指導医シンポジウム 【領域講習】	15:40-16:50 一般演題 4 皮膚創傷治癒 2 座長：堂後京子	
17:00		16:50-17:50 一般演題 5 皮膚創傷治癒 3 座長：藤原敏宏	17:00-18:00 分野指導医教育セミナー 1 小児形成外科
18:00	18:30-19:30: 第 3 会場でカクテル懇親会（Gala cocktail networking party）		

Day 1 (Oct 17, Thurs)

	IPSRC 1 (Room 6)	IPSRC 2 (Room 3)	ISPRES (Room 7)	TAAT (Room 8)
9:00	09:00-10:30 Keynote lectures Nerve/ Muscle 1 Yuan-Yu Hsueh/ Christine Radtke/ Alison Snyder-Warwick/ Amy Moore	09:00-10:40 Free papers Skin/Burn/Wound Healing 1 Moderators: David Brown/ Hajime Matsumura	09:00-10:00 Free papers Reconstruction/ regeneration Moderators: Stefania de Fazio/ Shimpei Ono Coffee break (10 min)	09:00-10:30 Free papers Surgical procedures Moderators: Tim Papadopoulos/ Asahi Rintaro
10:00	Coffee break (20 min)		10:10-11:10 Keynote lectures Reconstruction/ regeneration 1 Moderators: Marco Klinger/ Tomoyuki Yano	
11:00	10:50-11:40 Keynote lectures Nerve/ Muscle 2 Jason Ko/ Paul Cederna	10:40-12:20 Free papers Skin/Burn/Wound Healing 2 Moderators: Yuan-Yu Hsueh/ Rica Tanaka	11:10-11:40 Sponsored miniseminar (Brexogen) Taemin Kim/ Eray Copcu Coffee break (10 min)	10:30-12:20 Keynote lectures Facelift Lee Pu/ Tim Papadopoulos/ Woffles Wu/ Chia Chi Kao/ Giovanni Botti
12:00	11:40-12:20 Keynote lectures Lymphedema Babak Mehrara/ Al Hassanein Coffee break (10 min)	Coffee break (10 min)	11:50-12:20 Sponsored miniseminar (Dermato Plastic Beauty) Tsai-ming Lin Coffee break (10 min)	Coffee break (10 min)
13:00	12:30-13:30 Luncheon session (Simultaneous screening of Room 7)	12:30-13:30 Lunch time break (No program)	12:30-13:30 Luncheon session Regeneration Keynote lectures Roger Khouri/ Tim Papadopoulos	12:30-13:30 Sponsored Luncheon seminar (Metras, Inc.) John Paul C. Pareja
14:00	13:30-14:50 Free papers Vascular/ Lymphatic biology and diseases Moderators: Al Hassanein/ Mitsunaga Narushima Coffee break (10 min)	13:30-15:10 Keynote lectures Tissue Engineering Michael Findlay/ Wei Liu/ David Brown/ Junji Fukuda/ William Kuzon Coffee break (10 min)	Coffee break (20 min) 13:50-14:50 Keynote lectures Grafting methods Peter Rubin/ Nobert Pallua/ Chenggang Yi	13:30-14:30 Keynote lectures JSAS session Ayaka Nishikawa/ Yoshio Ikeda/ Masanori Ohashi Coffee break (10 min)
15:00	15:00-16:40 Keynote lectures APRAS symposium Nurul-Syazana Mohamad-Shah/ Yuan-Yu Hsueh/ Kotaro Yoshimura/ Seung-Kyu Han		14:50-15:30 Keynote lectures Grafting methods Patrick Tonnard 15:30-16:10 Keynote lectures Cryopreservation Peter Rubin/ Lee Pu Coffee break (10 min)	14:40-16:20 Keynote lectures APRAS symposium Adrian Ooi/ Hyungjoon Seo/ Ken Arashiro/ Taejoo Ahn/ Woffles Wu
16:00		15:20-17:20 Free papers Regenerative Medicine Moderators: Wei Liu/ Fumiaki Shimizu		
17:00	16:40-18:00 Free papers APRAS paper award session Moderators: Christine Radtke/ Hisashi Motomura	Preparation for Gala cocktail	16:20-17:40 Free papers Research Moderators: Dennis Orgill/ Rei Ogawa	16:20-17:30 Free papers APRAS paper award session Moderators: Hyungjoon Seo/ Joseph Anthony
18:00	18:30-19:30 Gala cocktail networking party (Room 3)			

日本語プログラム – 10 月 18 日（金）

	第1会場（Room 1）	第2会場（Room 2）	第5会場（Room 5）
9:00			
	09:00-10:30 シンポジウム 4 【領域講習】 科学的に抗加齢医療を読み解く	09:00-10:30 ロボット手術委員会企画 【領域講習】 Robotic surgery は、乳房再建手術に還元されるか！？－その問題点と展望－	
10:00			
	休憩（10 分）	休憩（10 分）	
11:00	10:40-12:10 一般演題 7 顔面骨・手の外科・乳房 座長：松峯 元	10:40-12:10 シンポジウム 5 【領域講習】 形成外科領域における AI/データサイエンスを駆使した治療学	
12:00			11:10-12:10 協賛ミニセミナー 4 共催：株式会社ベアーメディック
	休憩（10 分）	休憩（10 分）	
13:00	12:20-13:20 ランチョンセミナー 3 共催：株式会社ドクターズ・キッツ	12:20-13:20 ランチョンセミナー 4 共催：株式会社バイオマスター	
		休憩（10 分）	
14:00	13:20-14:00 教育講演 2 貴志和生/ なぜ形成外科医が基礎研究をするべきか？	13:30-14:50 最優秀一般演題セッション 座長：菅 浩隆/ 林田健志 審査員：岡部圭介、庄司未樹、渋谷陽一郎	13:20-14:20 分野指導医教育セミナー 2 レーザー
	休憩（10 分）		
15:00	14:10-15:10 キャリア支援委員会企画 【領域講習】 ～形成外科のキャリアパス～	14:50-15:50 共通講習 2 (感染対策) 矢野(五味)晴美/ 教育科学に基づいた感染症診療と教育-AI 時代のベストプラクティス	14:20-15:20 分野指導医教育セミナー 3 皮膚腫瘍外科
			休憩（10 分）
16:00	15:10-16:40 一般演題 8 AI ほか 座長：清水史明	15:50-16:40 一般演題 9 再生医療 座長：覚道奈津子	15:30-16:30 分野指導医教育セミナー 4 再建・マイクロサージャリー
17:00	16:40-17:40 編集委員会企画 【領域講習】 AI を用いた論文執筆の現状と問題点	16:40-17:30 一般演題 10 レーザー 座長：野村 正	16:30-17:30 CST 委員会企画 シンポジウム 【領域講習】
18:00			

Day 2 (Oct 18, Fri)

	IPSRC 1 (Room 6)	IPSRC 2 (Room 3)	ISPRES (Room 7)	TAAT (Room 8)
9:00				
09:00-11:00	Keynote lectures General 1 David Mathes/ Christopher Forrest/ Theodore Kung/ Justin Sacks/ Gregory Evans	09:00-10:20 Free papers Aesthetic/ Gender/ Cancer Moderators: Justin Lee/ Taku Maeda	09:00-10:00 Free papers Stem cells/ Tissue Engineering Moderators: Ewa Siolo/ Masao Kakibuchi	09:00-10:50 Keynote lectures Japan-China-Korea Joint Session: Cutting Edge of Aesthetic Medicine Bin Zhang/ Hideaki Sato/ Hong-Ki Lee/ Zhan Wang/ Akiko Imaizumi
10:00		10:20-11:40 Keynote lectures Scar/ Mechano-biology Wei Liu/ Rei Ogawa/ Geoffrey Gurtner/ Dennis Orgill	10:00-12:20 Best free papers Sydney Coleman award session Moderators: Stefania de Fazio/ Hiroshi Mizuno	Coffee break (10 min)
11:00	11:00-12:20 Free papers Nerve Moderators: Jason Ko/ Ayato Hayashi	11:40-12:10 Sponsored miniseminar (DPB) Tsai-Ming Lin		11:00-12:20 Keynote lectures Breast Sherri Roberts/ Giovanni Botti/ Roger Khouri/ Peter Rubin
12:00	Coffee break (10 min)	Coffee break (20 min)	Coffee break (10 min)	Coffee break (10 min)
12:30-13:30	Luncheon Keynote lectures Gender Affirming Michael Neumeister/ Justin Lee/ William Kuzon	12:30-13:30 Luncheon session (Simultaneous screening of Room 6)	12:30-13:30 Luncheon Keynote lectures Reconstruction & Regeneration 2 Ewa Siolo/ Roger Khouri/ Marita Eisenmann-Klein	12:30-13:30 Sponsored luncheon seminar (J. Hewitt Inc.) Giovanni Salti/ Minori Ueno/ Junko Seike
13:00				
13:30-14:50	Keynote lectures General 2 Geoffrey Gurtner/ Gregory Evans/ Timothy King/ Geoffrey Gurtner	13:30-14:40 Free papers Patient Safety/Education/ Leadership Moderators: Justin Sacks/Takuya Iida	13:30-15:10 Keynote lectures APRAS symposium Alfred Callanta/ Kwangsik Kook/ Kotaro Yoshimura/ Tsai-Ming Lin/ Jae-Ho Jeong	13:30-15:00 Keynote lectures Body contouring Peter Rubin/ Chris Patronella/ Tim Papadopoulos/ Chris Patronella
14:00	Coffee break (10 min)	Coffee break (10 min)		
15:00	15:00-16:50 Free papers Innovation/ Commercialization/ Technology Moderators: Timothy King/ Masao Kakibuchi	14:50-17:50 Japan symposium Cell therapies in Japan Rica Tanaka/ Hideyuki Takahashi/ Kazuo Ohnishi/ Masukazu Inoie/ Yasuyuki Mitani/ Kazunori Shimomura	15:10-16:10 Free papers APRAS paper award session Moderators: Aris Sterodimas/ Shinsuke Akita	15:00-16:20 Keynote lectures Laser and energy devices Nariaki Miyata/ Patrick Huang/ Peter Peng/ Taro Kono
16:00			Coffee break (10 min)	
17:00	16:50-17:50 Free papers Breast Moderators: Michael Findlay/ Tomoyuki Yano		16:20-17:40 Keynote lectures Regeneration Dennis Orgill/ Marita Eisenmann-Klein/ Nelson Piccolo	16:20-17:40 Free papers TAAT best paper session Moderators: Weigang Cao/ Harunosuke Kato
18:00				

Day 3 (Oct 19, Sat)

	IPSRC 1 (Room 6)	ISPRES (Room 7)	TAAT (Room 8)
9:00	09:00-09:40 Free papers Others Moderators: Shailesh Agarwal/ Yusuke Shimizu Keynote lectures Shailesh Agarwal	09:00-10:20 Free papers Moderators: Nobert Pallua/ Ken Arashiro	09:00-10:20 Keynote lectures
10:00	09:40-10:20 Keynote lectures Stem cells 1 Christina Camargo/ Indranil Sinha	Keynote lectures Body contouring Aris Sterodimas/ Weigang Cao	Face 1 Tim Papadopoulos/ Woffles Wu/ Chia Chi Kao/ Hyungjoon Seo
11:00	10:20-11:20 Free papers Skin/Burn/Wound Healing 3 Moderators: Geoffrey Gurtner/ Michiharu Sakamoto Keynote Rica Tanaka	10:20-12:20 Keynote lectures Face Weigang Cao/ Lee Pu/ Aris Sterodimas/ Valerio Cervelli/ Ewa Siolo/ Marco Klinger	10:20-11:20 Keynote lectures Face 2 Taejoo Ahn/ Chia Chi Kao/ Giovanni Botti
12:00	11:20-12:20 Keynote lectures Fat Paul Cederna/ Summer Hanson/ Feng Lu/		11:20-12:20 Keynote lectures BTX and HA injection Nobutaka Furuyama/ Woffles Wu/ Nariaki Miyata
	Coffee break (10 min)	Coffee break (10 min)	Coffee break (10 min)
13:00	12:30-13:30 Luncheon session Keynote lectures Stem cells 2 Geoffrey Gurtner/ Emi Nishimura	12:30-13:30 Luncheon session (Simultaneous screening of Room 6)	12:30-13:30 Lunch time break
14:00	13:30-14:50 Free papers Craniofacial/Others Moderators: William Kuzon/ Ataru Sunaga	13:30-14:50 Free papers Moderators: Nelson Piccolo/ Koichi Tomita Keynote lectures Breast 1 Marco Klinger/ Amin Kalaaji/ Gino Rigotti	13:30-14:50 Keynote lectures Facial rejuvenation (Non-surgery) 1 Giovanni Salti/ Patrick Huang
15:00	14:50-17:30 Free papers IPSRC best paper session Moderators: Dennis Orgill/ Yoshihiro Sowa	15:10-16:30 Keynote lectures Breast 2 Valerio Cervelli/ Gino Rigotti/ Marita Eisenmann-Klein/ Roger Khouri	14:50-16:10 Keynote lectures Facial rejuvenation (Non-surgery) 2 Patrick Tonnard/ Giovanni Salti/ Peter Peng
16:00			
17:00		16:30-17:50 Free papers Face Moderators: Ewa Siolo/ Natsuko Kakudo	16:10-17:20 Free papers Non-surgery Moderators: Peter Peng/ Taro Kono
18:00			

日本語 プログラム

日本語プログラム委員

前田拓(北海道大学)
庄司未樹(東北大学)
堂後京子(帝京大学)
松峯元(東京女子医科大学)
岡部圭介(慶應義塾大学)
高成啓介(愛知県がんセンター)
富田興一(近畿大学)

覚道奈津子(関西医科大学)
藤原敏宏(川西市立総合医療センター)
坂本道治(京都大学)
品岡玲(岡山大学)
清水史明(大分大学)
田中里佳(順天堂大学)
素輪善弘(自治医科大学)

金山幸司(東京大学)
林田健志(島根大学)
渋谷陽一郎(筑波大学)
馬場香子(北里大学)
須永中(自治医科大学)
菅浩隆(帝京大学)

教育講演(基礎研究)

貴志和生 / 慶應義塾大学
木股敬裕 / 岡山大学



貴志和生



木股敬裕

専門医共通講習

- ① 医療倫理 児玉聡 / 京都大学
- ② 感染対策

矢野(五味)晴美 / 国際医療福祉大学



児玉聡



矢野(五味)晴美

シンポジウム(公募、一部指定)

① Bench to Bedside:慢性創傷への新しいアプローチ!

田中里佳 / 順天堂大学
榊原俊介 / 神戸大学
坂本道治 / 京都大学
大谷直矢 / 大阪大学
澤良木詠一 / 京都大学



田中里佳



榊原俊介



坂本道治



大谷直矢



澤良木詠一

② 外科医による大型研究資金獲得-死の谷を越えるコツ

森本尚樹 / 京都大学
小川令 / 日本医科大学
門田英輝 / 九州大学
清水雄介 / 琉球大学
尾崎峰 / 杏林大学



森本尚樹



小川令



門田英輝



清水雄介



尾崎峰

③ 形成外科医が基礎研究を始めるための第一歩-研究室立ち上げノウハウ

松峯元 / 東京女子医科大学
覚道奈津子 / 関西医科大学
前田拓 / 北海道大学
渋谷陽一郎 / 筑波大学
小野田聡 / 富山大学



松峯元



覚道奈津子



前田拓



渋谷陽一郎



小野田聡

④ 科学的に抗加齢医療を読み解く

中西真 / 東京大学
高谷健人 / 慶應義塾大学
吉田周平 / 広島大学
古川聖美 / 順天堂大学
上原幸 / 大分大学



中西真



高谷健人



吉田周平



古川聖美



上原幸

⑤ 形成外科領域におけるAI/データサイエンスを駆使した治療学

松本健吾 / 大分岡病院
森田大貴 / 東海大学
中村優 / 城本クリニック
永竿智久 / 香川大学
西堀公治 / 西堀形成外科



松本健吾



森田大貴



中村優



永竿智久



西堀公治

委員会企画

① ロボット手術委員会企画

〈Robotic surgeryは、乳房再建手術に還元されるか!?—その問題点と展望—〉

福岡英祐 / 亀田総合病院
佐武利彦 / 富山大学
浅野裕子 / 亀田総合病院
堂後京子 / 帝京大学
秋田新介 / 千葉大学



福岡英祐



佐武利彦



浅野裕子



堂後京子



秋田新介

② 編集委員会企画

〈AIを用いた論文執筆の現状と問題点〉

櫻庭実 / 岩手医科大学
館一史 / 東北医科大学
中村知繁 / 順天堂大学
岡田達也 / Seekl(株式会社 杏林舎)



櫻庭実



館一史



中村知繁



岡田達也

③ キャリア支援委員会企画

〈日形会キャリア支援委員会企画シンポジウム～形成外科のキャリアパス～〉

浜島昭人 / 群馬県立小児医療センター
横山才也 / 銀座すみれの花クリニック
倉元有木子 / 三井記念病院
福地優衣 / 獨協医科大学埼玉医療センター
矢内香織 / 順天堂大学



浜島昭人



横山才也



倉元有木子



福地優衣



矢内香織

④ CST委員会企画

〈日形会CST委員会企画シンポジウム〉

今西宣晶 / 慶應義塾大学
津下到 / 京都大学
秋田新介 / 千葉大学
今井啓道 / 東北大学
鈴木崇根 / 千葉大学



今西宣晶



津下到



秋田新介



今井啓道



鈴木崇根

⑤ ガイドライン委員会企画

〈患者向けガイドブック 乳房再建とリンパ浮腫乳房再建〉

【乳房再建】

佐武利彦 / 富山大学
庄司未樹 / 東北大学
奥村誠子 / 愛知県がんセンター
棚倉健太 / 三井記念病院
武藤真由 / Lala プレスト・リコンストラクション・クリニック横浜
小宮貴子 / 東京医科大学病院



佐武利彦



庄司未樹



奥村誠子



棚倉健太



武藤真由



小宮貴子

【リンパ浮腫】

佐久間恒 / 東京歯科大学市川総合病院
秋田新介 / 千葉大学
安永能周 / 静岡県立静岡がんセンター
塗隆志 / 大阪医科大学
関征央 / がん研有明病院
成島三長 / 三重大学



佐久間恒



秋田新介



安永能周



塗隆志



関征央



成島三長

分野別指導医セミナー

① 皮膚腫瘍外科分野指導医シンポジウム

古川洋志 / 愛知医科大学
桑原理充 / 奈良県立医科大学
藤岡正樹 / 国立病院機構長崎医療センター
吉龍澄子 / 国立病院機構大阪医療センター
木村中 / 函館厚生院函館中央病院
森秀樹 / 愛媛大学



古川洋志



桑原理充




藤岡正樹



吉龍澄子



木村中



森秀樹

② 皮膚腫瘍外科セミナー

前田拓 / 北海道大学
牧口貴哉 / 群馬大学



前田拓



牧口貴哉

③ 小児形成外科セミナー

坂原大亮 / 大阪市立総合医療センター
武内俊樹 / 慶應義塾大学



坂原大亮



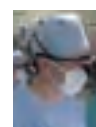武内俊樹

④ 再建・マイクロサージャリーセミナー

林利彦 / 旭川医科大学
鳥谷部荘八 / 仙台医療センター



林利彦



鳥谷部荘八

⑤ レーザーセミナー

若槻華子 / 新潟大学
大城貴史 / 大城クリニック



若槻華子



大城貴史

10月17日 – 第1会場 (Room 1)

	テーマ・座長	演者・演題名
9:00		
10:00	09:00-10:30 シンポジウム 1 【領域講習】 座長：岡崎睦/島田賢一	Bench to Bedside:慢性創傷への新しいアプローチ！ 榊原俊介「青色光がヒト皮膚に与える影響」 田中里佳「細胞生物学的アプローチで慢性創傷の新・治療を創出する」 大谷直矢「体内水素発生能を有するシリコン製剤の圧迫損傷に対する予防・治療効果」 坂本道治「乾燥同種培養表皮による潰瘍治療」 (特別発言) 澤良木詠一「慢性創傷へのアプローチ：シルクエラスチンスポンジの慢性創傷に対する有効性」
	休憩 (20 分)	
11:00	10:50-12:10 一般演題 1 腫瘍・移植ほか 座長：金山幸司	J71 中尾仁美「当院当科で過去 3 年間に取扱った脂肪腫 100 例の統計」 J47 石原良平「酸化セルロース貼付剤 (吸収性局所止血剤) を用いた、安全で確実なリンパ節摘出術の検討」 J31 古賀一史「ガイドラインが推奨するマージン以上で切除したにも関わらず再発した悪性黒色腫の 3 例」 J15 京野香織「当科における基底細胞癌治療の変遷と切除マージン 2mm 以下の症例の術後経過に関する検討」 J16 佐々木雄輝「メラノーマに対する腫瘍溶解性ウイルスと抗 PD-1 抗体の併用療法によるリンパ系の免疫賦活化に関する検証」 J65 窪田吉孝「脂肪移植のための染色体別エピジェネティクス修飾の可視化」 J50 森脇裕太「局所的な乏毛・無毛モデルの開発」 J42 原 幸司「脂肪組織由来幹細胞 (ADSC) バンク設立を目指して」
12:00	休憩 (10 分)	
13:00	12:20-13:20 ランチョンセミナー 1 座長：佐藤英明	佐藤英明 切らないスキントイトニング治療の最新事情～低侵襲 RF 治療器を用いたアプローチ～ 共催：マーベラスビューティージャパン株式会社
14:00	13:20-14:00 教育講演 1 座長：宮脇剛司	木股敬裕 Why, What が生み出す研究・臨床、そして自游
	休憩 (10 分)	
15:00	14:10-15:40 シンポジウム 3 【領域講習】 座長：橋本一郎/小室裕造	形成外科医が基礎研究を始めるための第一歩-研究室立ち上げノウハウ 松峯元「Re: ゼロから始める基礎研究」 覚道奈津子「ゼロから始める形成外科医の基礎研究：研究において大事な 4 つの要素」 前田拓「形成外科医として臨床家として基礎研究を考え・繋げる」 小野田聡「新設医局におけるゼロからの研究室立ち上げの為のアプローチ」 渋谷陽一郎「研究室留学から学ぶ - 当施設における研究室立ち上げまでの経験から-」
	休憩 (10 分)	
16:00	15:50-17:20 皮膚腫瘍外科 分野指導医 シンポジウム 【領域講習】 座長：古川洋志	古川洋志 (Keynote Speech)「皮膚腫瘍外科分野指導医になろう！」 桑原理充「怪しいと思ったら～正しく診断し適切に評価しよう」 藤岡正樹「ガイドライン等を参考に過不足のない切除を」 吉龍澄子「病理の伝票にどう書こう？ 正しい検体の提出できますか？」 木村中「皮膚腫瘍 (皮膚がん) 切除後の再建 - 植皮か皮弁か - 私の経験」 森秀樹「予後のお話は？ 最新の免疫治療の適応を知っておこう」
17:00		
18:00		

10月17日 – 第2会場 (Room 2)

	テーマ・座長	演者・演題名
9:00	09:00-10:10 一般演題 2 皮弁・マイクロ サージャリー 座長：高成啓介	J25 十九浦礼子「ハンスフリー吸引管～助手なしの血管吻合もこれでスムーズに～」 J61 上敏明「鼻中隔における血行動態の観察とその臨床応用」 J46 羽賀義剛「マウスリンパ節付随免疫皮弁モデルを用いた新しいがん免疫療法に向けて」 J94 古谷春乃「3次元CG画像生成ソフトウェア Viewtify」 J38 美波直岐「新鮮凍結死体を用いた腓骨動脈皮弁後のドナー部閉創に有用な穿通枝動脈皮弁の検討」 J56 坂田光崇「AR マイクロサージャリートレーニングシステムを用いた術者視線解析と熟練医暗黙知の抽出」 J59 橋田周治「裸眼立体視を用いた乳房再建術前・術中支援システム」
10:00	10:10-12:10 シンポジウム 2 【領域講習】 座長：久保盾貴/中川雅裕	外科医による大型研究資金獲得-死の谷を越えるコツ 森本尚樹「現状の課題と最終目標を整理する」 小川令「形成外科医が大型研究費を取るために大切なこと」 門田英輝「はじめてのクラウドファンディング-その仕組みと成功への鍵ー」 尾崎 峰「静脈奇形に対する硬化剤の医師主導治験」 清水雄介「医療機器開発・再生医療事業を通じた外部資金獲得ーゼロから始めるためのポイントー」
11:00	休憩（10分）	
12:00	12:20-13:20 ランチョンセミナー 2 座長：三鍋俊春	棚倉健太 Motiva を使用して1年、今思うこと 共催：PRSS Japan 株式会社
13:00	13:20-14:20 共通講習 (医療倫理) 座長：田中克己	児玉 聡 現代社会の医療倫理
14:00	休憩（10分）	
15:00	14:30-15:40 一般演題 3 皮膚創傷治癒 1 座長：坂本道治	J27 牧野愛子「光超音波イメージングを用いたケロイド血管新生の解析」 J40 今井利郎「バトロキシピンがマウス熱傷に与える影響の解析」 J18 石井 陸「羊膜由来間葉系幹細胞の抗菌活性と感染性糖尿病性潰瘍モデルマウスにおける効果」 J69 森永絵理「糖尿病性潰瘍に対する有効な治療法としてのマイクロニードルの可能性」 J39 宮下采子「脱分化脂肪細胞 (DFAT) 含浸真空凍結乾燥人工真皮の in vitro 評価」 J62 土佐真美子「空間トランスクリプトームによるケロイド病態解析」 J43 石井愛「皮膚伸展刺激および RhoA 経路の阻害による線維芽細胞のアポトーシス動態と増殖能の検討」
16:00	15:40-16:50 一般演題 4 皮膚創傷治癒 2 座長：堂後京子	J79 今川孝太郎「ラット皮弁虚血再灌流障害モデルによるバトロキシピンの皮弁壊死抑制効果の検討」 J49 末吉 遊「PGA 不織布による組織修復促進の検討」 J17 細見謙登「線維化を制御するイモリ免疫細胞の可能性」 J82 岡野純子「難治性感染症に対する新規治療法の開発」 J34 黒田友集「慢性創傷洗浄にふさわしい石鹸はなにか」 J36 中村遼太「シングルセル解析を用いたケロイドの形成機構の解明を目指して」 J91 大山拓人「創部から分泌された滲出液内の創傷治癒に関わる細胞間ネットワーク因子の定量化の試み」
17:00	16:50-17:50 一般演題 5 皮膚創傷治癒 3 座長：藤原敏宏	J05 松田識郁「Burn wound conversion 研究のための新しいマウス熱傷モデル」 J06 島田和樹「オートロジェルシステム®と既存 PRP 療法の創傷治癒における比較検討」 J35 松添晴加「ケロイドの痒みに着目した組織学的解析および Substance P 遺伝子発現解析」 J13 橋本 葵「陰圧閉鎖療法 (NPWT) を用いた植皮固定至適圧の検討」 J44 高清水一慶「in vivo におけるミトコンドリア移植の創傷治癒効果について」
18:00		

10月17日 – 第5会場 (Room 5)

	テーマ・座長	演者・演題名	
9:00			
10:00			
10:00-11:40	一般演題 6 血管・リンパ管 座長：品岡 玲	J41 十九浦礼子「開創型ハンズフリー吸引管～重症リンパ浮腫での LVA をもっと手軽に～」 J63 藤井奈穂「乳児血管腫に対するプロプラノロール投与終了後に再増大を認めた症例の検討」 J74 桑原征宏「ペルフルブタンによる造影超音波と ICG 血管造影を併用したリンパ管-静脈吻合の術前評価」 J29 徐 東経「活性化大網を用いたリンパ浮腫治療における大網皮弁の分子生物学的側面に対する研究」 J58 辻本悠貴「ラット上腸間膜リンパ管を用いた人工リンパ管生体内挙動評価モデルの開発」 J03 西岡俊彦「補体欠損リンパ浮腫モデルでは CD4 ⁺ T 細胞の浸潤が増加する」 J89 玉懸美菜実「Vascular Malformations における PIK 3 CA 遺伝子変異の検討」 J23 畔 熱行「電圧印加型冷蔵庫を用いたラット血管の非凍結保存による組織保存期間の延長効果」	
11:40-12:10	協賛ミニセミナー 1 座長：森 弘樹	浅野裕子 ナトレル ブレスト・インプラントを用いた乳房増大術 ／共催：アッヴィ合同会社(アラガン・エステティックス)	
13:00			
13:50-14:20	協賛ミニセミナー 2 座長：北條元治	清水絢也 細胞医療のための特定細胞加工事業者の取り組み ／共催：セルバンク株式会社	
14:20-14:50	協賛ミニセミナー 3 座長：水野博司	Haw Torng Advancing fat grafting: How MAFT and the MAFT-GUN revolutionized my practice ／共催：Demato Plastic Beauty, Co Ltd.	
15:00	休憩（10 分）		
15:00-17:00	ガイドライン委員会 企画 【領域講習】 座長：鳥山和宏/杠 俊介	乳房再建	佐武利彦「乳房再建ガイドブックの概要」 庄司未樹「乳房再建とは/ 乳がん治療と乳房再建」 奥村誠子「人工物再建」 棚倉健太「自家組織再建」 武藤真由「脂肪注入」 小宮貴子「乳頭乳輪再建」
16:00		リンパ浮腫	佐久間恒「リンパ浮腫ガイドブックの概要」 秋田新介「リンパ浮腫とは/診断総論」 安永能周「診断各論」 成島三長「外科的治療総論/複合的治療」 関征央「外科的治療各論」 関征央「合併症の治療」
17:00-18:00	分野指導医 教育セミナー 1 座長：野口昌彦	小児形成外科 坂原大亮「クラニオフェイシャルサージェリーの基礎～頭蓋縫合早期癒合を中心に～」 武内俊樹「頭蓋縫合早期癒合症の分子機構と神経発達」	
18:00			

10月18日 – 第1会場 (Room 1)

	テーマ・座長	演者・演題名
9:00		
10:00	09:00-10:30 シンポジウム 4 【領域講習】 座長：武田 啓/関堂 充	科学的に抗加齢医療を読み解く 中西真 (Keynote) 「老化細胞を標的として加齢病態を改善する」 高谷健人 「老化線維芽細胞除去を介した「真の」皮膚抗老化治療の可能性」 古川聖美 「末梢血生体外増幅単核球を用いた毛髪再生への取り組み」 吉田周平 「加齢による下肢浮腫とリンパ管の機能低下の検討」 上原幸 「加齢と爪甲変形についての検討」
	休憩 (10 分)	
11:00	10:40-12:10 一般演題 7 顔面骨・ 手の外科・乳房 座長：松峯 元	J57 小柳俊彰 「先天性眼瞼下垂の筋膜移植術、筋膜の成長期を含めた経時的变化～眼瞼・眉毛位置計測ソフトを用いて～」 J70 安藤暢浩 「Shear wave elastography を用いた頭蓋内圧の非侵襲的な測定法の研究」 J73 勝部元紀 「唇裂患者における外鼻の左右差 ～相同モデルを用いた 3 次元形態解析～」 J66 深沢克康 「手の外科領域における光超音波イメージングの実際と展望」 J68 牧野潤 「VY 前進皮弁及び Minced skin graft を用いた簡便な乳輪乳頭形成術」 J55 古屋香葉子 「アレイ小型デュロメータを用いた再建乳房の硬さ三次元マッピングシステム」 J51 松永拓 「人工物乳房再建におけるバイオフィーム解析 -textured type vs smooth type-」 J88 角田祐衣 「光超音波イメージング装置を用いた脂肪注入後の再建乳房の血管構造の解析」
12:00	休憩 (10 分)	
13:00	12:20-13:20 ランチョンセミナー 3 座長：松村 一	河野太郎 ピコ秒レーザーを用いた色素性疾患の治療戦略 共催：株式会社ドクターズ・キット
14:00	13:20-14:00 教育講演 2 座長：朝戸裕貴	貴志和生 なぜ形成外科医が基礎研究をするべきか？
	休憩 (10 分)	
15:00	14:10-15:10 キャリア支援 委員会企画 【領域講習】 座長：三川信之/小宮貴子	日形成外科学会キャリア支援委員会企画シンポジウム ～形成外科のキャリアパス～ 浜島昭人 「キャリアの節目：入局、専門医、管理職」 横山才也 「これからのキャリア形成」 倉元有木子 「子育てと再建女医としてのキャリア」 福地優衣 「出産と専門医試験の両立」 矢内香織 「キャリア支援委員会を活用して能動的にキャリア形成しよう！」
16:00	15:10-16:40 一般演題 8 AI ほか 座長：清水史明	J54 西條優作 「Group A Streptococcus Necrotizing Soft Tissue Infection の早期は白血球が上昇しにくい」 J21 安藤優希 「持続灌流併用局所陰圧閉鎖療法併用における担体として用いた人工真皮内の micrograft の組織学的評価」 J85 長島隼人 「多血小板血漿 (PRP) の透過率による品質管理方法の開発」 J53 浅倉辰則 「間葉系幹細胞に対してセルネストが与える影響」 J08 遊佐優 「生体吸収性マグネシウム骨接合材開発に向けたプレシャイト皮膜処理の有用性の検討」 J77 渡邊英孝 「ソース症候群の DNA メチル化解析で IGF2-DMR0 が IGF2 P0 特異的 enhancer であり、過成長に関与する可能性を示した」 J28 徐東経 「マウス後肢リンパ浮腫の新たな評価法としての 3D スキャナーの潜在力」 J93 矢野智之 「患者向け顔面神経麻痺顔面スコアリングおよびリハビリテーションアプリの開発」 J84 伊藤賢奎 「ABCC11 遺伝子の SNP 保有率と腋臭症発症因子の関連性に関する臨床研究」
17:00	16:40-17:40 編集委員会企画 【領域講習】 座長：櫻庭 実	AI を用いた論文執筆の現状と問題点 舘一史 「AI チャットボットの使用経験とリスク」 櫻庭実 「医学雑誌投稿規定から見た AI と論文執筆」 中村知繁 「生成 AI が研究と学術執筆に与える影響」 岡田達也 「JPRS における生成 AI の利用制限の解説」
18:00		

10月18日 – 第2会場 (Room 2)

	テーマ・座長	演者・演題名
9:00		
10:00	09:00-10:30 ロボット手術 委員会企画 【領域講習】 座長：上村哲司/ 檉村 勉	Robotic surgery は、乳房再建手術に還元されるか！？－その問題点と展望－ 福間英祐 (Keynote) 「乳腺外科 (乳輪温存乳房切除術に限る) における内視鏡手術とその適応拡大であるロボット手術に関して」 佐武利彦 「Robotic Surgery を乳房再建術に還元するための薬事・保険収載の出口戦略」 浅野裕子 「内視鏡下 TE/SBI 挿入について」 堂後京子 「内視鏡補助下広背筋弁挙上の実際と課題、Robotic surgery への展望」 秋田新介 「内視鏡補助下広背筋脂肪弁」
	休憩 (10 分)	
11:00	10:40-12:10 シンポジウム 5 【領域講習】 座長：西本 聡/秋元正宇	形成外科領域における AI/データサイエンスを駆使した治療学 松本健吾 「糖尿病足病変を画像診断する人工知能の開発研究」 中村 優 「AI を利用した画像診断モデルの NEXT PHASE～どこでつかうか、なんのためにつかうか～」 森田大貴 「形成外科領域における人工知能技術の導入～顔面骨 CT 画像の解析～」 永竿智久 「胸郭変形症の手術に伴う、乳房の形態変化を予測する技術の開発」 西堀公治 「アザ診断治療に対し AI 深層学習を用いた「脈管系疾患・色素性疾患」の診断補助の可能性」
12:00	休憩 (10 分)	
13:00	12:20-13:20 ランチョンセミナー 4 座長：関堂 充	これから始める形成外科領域での再生医療 海野早織 「細胞加工施設を自施設内に併設する再生医療」 渋谷陽一郎 「細胞加工デバイスを用いた再生医療」 浅野裕子 「細胞加工を細胞培養加工施設へ委託する再生医療」 共催：株式会社バイオマスター
	休憩 (10 分)	
14:00	13:30-14:50 最優秀一般演題 セッション 座長：菅 浩隆/林田健志	J45 高清水一慶 「アカハライモリの熱傷モデルを用いた“傷上皮”と炎症の関係」 J22 馬場香子 「臍帯・臍帯血由来材料による組織形成能の検討－15 年間の総括－」 J87 熊切将宜 「ヒト標本を用いた初期眼瞼発生時期の検討」 J96 齋藤夏美 「糖尿病難治性潰瘍マウスモデルに対するヒト脂肪組織常在性の血管内皮前駆細胞の投与効果」 J30 太田智之 「培養軟骨の移植後骨化抑制法の確立と RNA シークエンス解析によるメカニズム解明」 審査集計 (審査員: 座長 + 岡部圭介、庄司未樹、渋谷陽一郎) 表彰式
15:00	14:50-15:50 共通講習 (感染対策) 座長：門松香一	矢野(五味)晴美 教育科学に基づいた感染症診療と教育－AI 時代のベストプラクティス
16:00	15:50-16:40 一般演題 9 再生医療 座長：覚道奈津子	J83 長崎敬仁 「免疫不全マウスを用いた人工真皮移植モデルでのヒト DFAT の創傷治癒促進効果の検証」 J48 杉本佳香 「骨分化誘導時におけるエクソソーム量の変化について、ヒト腸骨由来間葉系細胞由来の培養上清での検討」 J90 荻野秀一 「強化型人工脂肪を用いた脂肪再生」 J24 森山和の 「日本の社会における再生医療に関する意識調査」
17:00	16:40-17:30 一般演題 10 レーザー 座長：野村 正	J20 青井則之 「Scaffold としての特性を用いたヒアルロン酸注入療法」 J14 森久陽一郎 「乳児血管腫のレーザー治療効果に対する客観的評価方法の確立と従来の視覚評価法との比較検討」 J92 杉野宏子 「ナノサイズ微細水粒子 AIR(アイル)とヒト脂肪由来幹細胞培養上清液による女性の脱毛進行予防効果の検討」 J26 前田珠未 「AI を使用した鼻形成術 ～CT 画像より鼻軟骨の位置を特定する～」 J12 坂本好昭 「Buccal fat pad の解剖学的検討」
18:00		

10月18日 – 第5会場 (Room 5)

	テーマ・座長	演者・演題名
9:00		
10:00		
11:00		
11:10-12:10	協賛セミナー 4 座長：素輪善弘	矢野智之 いまさら訊けない優しくて簡単な自家組織乳房再建 ／共催：株式会社ベアーメディック
12:00		
13:00		
13:20-14:20	分野指導医 教育セミナー 2 座長：河野太郎	レーザー 大城貴史「太田母斑、異所性蒙古斑などの真皮メラノサイトーシスに対するレーザー治療」 若槻華子「レーザー基礎」
14:00		
14:20-15:20	分野指導医 教育セミナー 3 座長：古川洋志	皮膚腫瘍外科 前田 拓「最新の皮膚悪性腫瘍治療指針：NCCN・皮膚悪性腫瘍診療ガイドラインを読み解く」 牧口貴哉「腫瘍切除後の口唇・口唇周囲広範欠損に対する再建」
15:00		
休憩（10分）		
15:30-16:30	分野指導医 教育セミナー 4 座長：伊東 大	再建・マイクロサージャリー 林 利彦「下顎再建を行うための基礎知識」 鳥谷部荘八「形成外科医が知っておくべき重度四肢外傷」
16:00		
16:30-17:30	CST 委員会企画 シンポジウム 【領域講習】 座長：三鍋俊春/ 三川信之	CST 今西宣晶「慶應義塾大学での CST と形成外科領域の問題点」 津下 到「ガイドライン発行後の形成外科領域 CST の全レビュー」 秋田新介「CST 報告書の書き方について」 今井啓道「形成外科が進むべき CST の方向性」 鈴木崇根「忘れてはいけない倫理的側面 –CST 参加者心得–」
17:00		
18:00		

Organizing committee

Kotaro Yoshimura (Japan)
Arin Greene (USA)
William Kuzon (USA)
Christine Radtke (Austria)
Rei Ogawa (Japan)
Rica Tanaka (Japan)

Program committee

Paul Cederna (USA)
Michael Findlay (Australia)
Summer Hanson (USA)
Al Hassanein (USA)
Yuan-Yu Hsueh (Taiwan)
Justine Lee (USA)
Feng Lu (China)
Amy Moore (USA)
Dennis Orgill (USA)
Justin Sacks (USA)

Indranil Sinha (USA)
Shinsuke Akita (Japan)
Yuko Asano (Japan)
Shimpei Ono (Japan)
Kazuo Kishi (Japan)
Yukio Seki (Japan)
Yoshihiro Sowa (Japan)
Hiroshi Mizuo (Japan)
Tomoyuki Yano (Japan)
Alison Snyder-Warwick (USA)

Shailesh Agarwal (USA)
David Brown (USA)
Timothy King (USA)
Wei Liu (China)
Hirotaka Suga (Japan)

招待演者



Geoffrey C. Gurtner (USA)



William Kuzon (USA)



Paul Cederna (USA)



Dennis Orgill (USA)



Peter J. Rubin (USA)



Emi Nishimura (Japan)



Yuan-Yu Hsueh (Taiwan)



Rica Tanaka (Japan)



Al Hassanein (USA)



David Mathes (USA)



Gregory Evans (USA)



Justine Lee (USA)



Michael Findlay (Australia)



Summer Hanson (USA)



Feng Lu (China)



Justin Sacks (USA)



Amy Moore (USA)



Babak Mehrara (USA)



Christina Camargo (Brazil)



Christine Radtke (Austria)



Christopher Forrest (Canada)



Jason Ko (USA)



Rei Ogawa (Japan)



Shailesh Agarwal (USA)



Theodore Kung (USA)



Wei Liu (China)



Indranil Sinha (USA)



Chenggang Yi (China)



Seung-Kyu Han (Korea)



Alison Snyder-Warwick (USA)



Timothy King (USA)



David Brown (USA)



Junji Fukuda (Japan)



Hideyuki Takahashi (Japan)



Kazunori Shimomura (Japan)



Kazuo Ohnishi (Japan)



Yasuyuki Mitani (Japan)



Masukazu Inoie (Japan)



Michael Neumeister (USA)

プログラム

- 1) Keynote speeches: Stem cells, Scar/mechano-biology, Nerve/Muscle, Lymphedema, Tissue engineering, Gender-affirmation, Adipose, etc.
- 2) Symposium: Cell therapies in Japan
- 3) APRAS symposium
- 4) Free paper sessions (IPSRC Award selection)

Day 1 (Oct 17, Thurs) / IPSRC1 (Room 6) [赤線付セッションは領域講習]

Session / Moderators		Speakers / Talk topics
9:00	09:00-10:30 Keynote lectures Nerve/ Muscle Moderators: William Kuzon/ Ayato Hayashi	<ul style="list-style-type: none"> ● Yuan-Yu Hsueh Distal Nerve Electrical Stimulation Facilitates Direct Muscle Neurotization And Functional Recoveries By Neuromuscular Junction Regeneration ● Christine Radtke Update and new developments in peripheral nerve repair ● Alison Snyder-Warwick (Virtual live) Pearls for optimal facial (re)animation ● Amy Moore (Virtual live) The use of electrical stimulation to improve function after nerve injury
Coffee break (20 min)		
11:00	10:50-11:40 Keynote lectures Nerve/ Muscle Moderators: Gregory Evans/ Yukio Seki	<ul style="list-style-type: none"> ● Jason Ko Targeted muscle reinnervation (TMR): From a "crazy idea" to a surgical revolution ● Paul Cederna (30 min) Cyborgs: The future is now
12:00	11:40-12:20 Keynote lectures Lymphedema Moderators: Gregory Evans/ Yukio Seki	<ul style="list-style-type: none"> ● Babak Mehrara (Virtual live) Pathophysiology of lymphedema ● Al Hassanein Novel approaches to lymphedema prevention
Coffee break (10 min)		
13:00	12:30-13:30 Luncheon session (Simultaneous screening of Room 7)	Keynote lectures Regeneration <ul style="list-style-type: none"> ● Roger Khouri (30 min) Regenerative procedures that morph tissue to reconstruct without incisions ● Tim Papadopoulos The secret life of fat: The science behind the most misunderstood body organ
14:00	13:30-14:50 Free papers Vascular/Lymphatic Biology and Diseases Moderators: Al Hassanein/ Mitsunaga Narushima	<ul style="list-style-type: none"> ● P56 Shinsuke Akita (Japan) Calcification of Achilles tendon in Werner syndrome ● PA1 Wataru Otsuka (Japan)[<i>Online</i>] Smooth Muscle Cell Regeneration within Human Lymphatics and Long-Term Follow-up After LVA ● P79 Shinsuke Akita (Japan) Eyelid in Morbihan disease is pathologically chronic lymphedema and super-microsurgical treatment can reduce the risk of the recurrence after skin excision ● P87 Joceline Theda Kadarman (Japan) Different Timing of Nanofibrillar Collagen Scaffold Implantation Affects the Lymphangiogenesis in Splinted Hindlimb Lymphedema Mouse Model ● P21 Yuki Matsuoaka (Japan) Characterization of vasospasm in femoral arteries of arteriosclerotic model rats: Induction of vasospasm and negative effect of the vasodilator treatment on the spasm releasing ● P78 Hsiang-Wei Hu (Taiwan) "Cytokine analysis of secondary lymphedema in patient with gynecologic cancer. A case-control study"
15:00	Coffee break (10 min)	
16:00	15:00-16:40 Keynote lectures APRAS symposium Moderators: Justin Sacks/ Rica Tanaka	<ul style="list-style-type: none"> ● Nurul-Syazana Mohamad-Shah (Virtual live) Novelty in genetics and histological discovery of non-syndromic cleft lip and/or palate in Malay population ● Rei Ogawa The latest in keloid and hypertrophic scar pathophysiology and treatment strategies ● Yuan-Yu Hsueh Electric stimulation preserves regenerative microenvironment of denervated neuromuscular junction by satellite cell differentiation ● Kotaro Yoshimura Radiation kills stem cells, Stem cells rescue radiation damage. ● Seung-Kyu Han Facial reconstruction utilizing micronized adipose tissue niche following skin cancer excision
17:00	16:40-18:00 Free papers APRAS symposium (APRAS award) Moderators: Christine Radtke/ Hisashi Motomura	<ul style="list-style-type: none"> ● P80 Jeong Yeop Ryu (Korea) Risk of Congestive Heart Failure and Mortality Following Lymphovenous Anastomosis: A Nationwide Population-based Retrospective Cohort Study ● P35 Yushi Suzuki (Japan) Investigation of Lymphatic flow dynamics using photoacoustic imaging system ● P25 Yoshihiro Toyohara (Japan) Effects of Prophylactic Systemic Administration of Adipose Stem Cells on Late Radiation Skin Injury ● P17 Bihang Zhang (Japan) Therapeutic Potential of Follicular Epithelial Cells Derived from Different Portions of Hair Follicle for Wound Healing and Epithelization ● P84 Sangchul Hyun (Japan) Efficacy of treating diabetic chronic ulcers using adipose-derived stem cell-conditioned medium ● P49 Kentaro Kosaka (Japan) iPSC-derived megakaryocytes and platelets accelerate wound healing and angiogenesis.
18:00	Awarding ceremony/ Memorial photo	

Day 1 (Oct 17, Thurs) / IPSRC 2 (Room 3) [赤線付セッションは領域講習]

	Session / Moderators	Speakers / Talk topics
9:00		
09:00-10:40	Free papers Skin/Burn/Wound Healing 1 Moderators: David Brown/ Hajime Matsumura	<ul style="list-style-type: none"> P09 Lionico, A Marquez (Philippines) Chilling in the Tropics: Management and Outcome of a Frostbite injury secondary to Refrigerant Burn, a case report P19 Mayu Hosio (Japan) The m6A-RNA epitranscriptomic pathway-pharmacological targeting of METTL3 to inhibit scarring. PA8 Julia Bartkova (Czech Republic) Age-Based Epidemiological Insights into Burn Injuries: Distinguishing Patterns in Pediatric and Adult Cohorts P48 Arisa Kita (Japan) Mechanisms of Cartilage Degeneration Post Autologous Costal Cartilage Transplantation in Microtia Treatment P97 Katsumi Ebisawa (Japan) Effects of Plasma-activated Lactate Ringer's Solution (PAL) on Mice Skin P41 Keisuke Okabe (Japan) Investigation of keloid pathogenesis focusing on mechanical stress P20 Kuo-Shu Hung (Taiwan) Therapeutic effects of high fluence light emitting diode-red light on burn hypertrophic scars P23 Makoto Shiraishi (Japan) Preliminary Elucidation of Generative Artificial Intelligence Chatbots in Interpreting Clinical Images of Pressure Injuries P62 Jesse Chou (USA) Social Determinants of Health Associated with Prolonged Time to Treatment for Non-Traumatic Upper Extremity Conditions
10:00		
10:40-12:20	Free papers Skin/Burn/Wound Healing 2 Moderators: Yuan-Yu Hsueh/ Rica Tanaka	<ul style="list-style-type: none"> P42 Arisa Tani (Japan) A clinical trial for quantifying wound healing regulatory factors in acute and chronic wounds P33 Rieko Shimizu (Japan) Alteration of Inflammatory Response by Subcutaneous Transplantation of Burned and Frostbitten Skin P16 Poh-ching Tan (China) Mechanical stretching can modify the papillary dermis pattern and papillary fibroblast characteristics during skin regeneration PA7 Julia Bartkova (Czech Republic) An Analysis of Independent Risk Factors Related to Burn Mortality in Adults. Is There a Correlation Between Patient Volume and Mortality? P55 Hang Dong (Japan) Generation of self-assembled 3D human dermal tissue from fibroblasts P91 Long Nguyen (Japan) Unveiling the three-dimensional vascular architecture of keloids using tissue-clearing techniques P31 Shi Xiong (China) The Mechanism Study of ADSC Derived Exosomes LncRNA Promote Skin Closure P69 Eri Toyohara (Japan) Gelsolin released from macrophages is required for fibroblast migration during skin wound healing
11:00		
12:00		
Coffee break (10 min)		
12:30-13:30	Lunch time break	(No program)
13:00		
13:30-15:10	Keynote lectures Tissue Engineering Moderators: Seung-Kyu Han/ Naoki Morimoto	<ul style="list-style-type: none"> ● Michael Findlay Absorbable devices and biomaterials in breast reconstruction ● Wei Liu Tendon engineering translation: From animal model to clinical treatment ● David Brown Enhancer-based gene therapy for digit regeneration ● Junji Fukuda Three-dimensional culture for hair regenerative medicine ● William Kuzon Tissue engineering research: The end of the beginning or the beginning of the end?
14:00		
15:00		
Coffee break (10 min)		
15:20-17:20	Free papers Regenerative medicine Moderators: Wei Liu/ Fumiaki Shimizu	<ul style="list-style-type: none"> ● P71 Karen Sugai (Japan) Recent evaluation of cell assisted lipotransfer for soft tissue augmentation in our institution ● P30 Sakurako Kunieda (Japan) Systematic analysis of beneficial effects of platelet lysates on human adipose-derived stem cells ● P77 Nur Azida Mohd Nasir (Malaysia)[Online] Mechanical isolation of adipose derived stem cells from fresh and cryopreserved: A Comparative analysis ● P82 Hsiao-Chen Lee (Taiwan) Achieving the Balance in Autologous Fat Transplantation: Harmonizing Volumization and Rejuvenation ● P74 Yoichiro Shibuya (Japan) "Using adipose-derived stem cells and its derivatives to promote regenerative medicine" ● P67 Kei Koizumi (Japan) Regenerative effects of adipose-derived stem and its-extracellular vesicles on skin injury models ● P89 Noriko Aramaki-Hattori (Japan) The role of versikine/versican in dermal papilla ● P68 Kei Koizumi (Japan) Regenerative effects of hiPSC-derived peripheral neuron/nerve progenitor on a nerve injury model ● P57 Audry-Yun-Xuan Chan (Taiwan) Preliminary Outcome of Herbal Extract Promotes Hair Regeneration by Enhancing M1/M2 Macrophage ● P11 Shuang-Bai Zhou (China) Clinical study on autologous concentrated growth factors promoting skin regeneration
16:00		
17:00		

Day 2 (Oct 18, Fri) / IPSRC 1 (Room 6) [赤線付セッションは領域講習]

	Session / Moderators	Speakers / Talk topics
9:00		
10:00	09:00-11:00 <u>Keynote lectures</u> General 1 Moderators: Al Hassanein/ Keisuke Imai	<ul style="list-style-type: none"> ● David Mathes Data driven optimization for microsurgical breast reconstruction ● Christopher Forrest (Virtual live) Surgical simulation and application of robotics in cleft and craniofacial surgery ● Theodore Kung (Virtual live) Regenerative peripheral nerve interface surgery for prosthetic control and postamputation pain ● David Mathes The future of tolerance for vascularized composite allotransplantation ● Justin Sacks Past, present, future microvascular anastomosis ● Gregory Evans Making the cut – establishing a career in plastic surgery
11:00	11:00-12:20 <u>Free papers</u> Nerve Moderators: Jason Ko/ Ayato Hayashi	<ul style="list-style-type: none"> ● PA0 Toshiro Mese (Japan)[Online] Pain surgery using nerve flaps: ultra-micromorphological changes and clinical applications ● P02 Shih-Heng Chen (Taiwan) Aligned core-shell fibrous nerve wrap containing Bletilla striata polysaccharide improves functional outcomes of peripheral nerve repair ● P13 Yu-Wen Lin (Taiwan) Application of ultrahigh frequency transcutaneous electrical nerve stimulation for alleviation of neuropathic pain and neuroinflammation modulation in rat sciatic nerve chronic constriction injury ● P24 Stanley Szu han Chen (Taiwan) Adipose-derived stem cells via therapeutic modulation of neuroinflammation to recover peripheral compressive neuropathy ● P93 Tina Tian (USA) Electrical stimulation and its effects on sympathetic regeneration after peripheral nerve injury ● P85 Seiji Sawai (Japan) Micronized cellular adipose matrix (MCAM) promotes the therapeutic effect of an artificial nerve conduit in peripheral nerve gap injury
12:00	Coffee break (10 min)	
13:00	12:30-13:30 Luncheon <u>Keynote lectures</u> Microsurgery/ Gender affirming Moderators: David Mathes/ Akira Momosawa	Microsurgery <ul style="list-style-type: none"> ● Michael Neumeister (Virtual live) Prefabrication of flaps in microsurgery Gender affirming <ul style="list-style-type: none"> ● Justin Lee Facial gender-affirming surgery ● William Kuzon Science vs. politics in transgender care
14:00	13:30-14:50 <u>Keynote lectures</u> General 2 Moderators: David Mathes/ Hiroyuki Sakurai	<ul style="list-style-type: none"> ● Geoffrey Gurtner Entrepreneurship: Getting Real About “Bench to Bedside” ● Gregory Evans Artificial Intelligence in Breast Surgery ● Timothy King Ethical considerations of artificial intelligence in surgical innovation ● Geoffrey Gurtner Understanding the foreign body response: Implications for ALCL and BIA
15:00	Coffee break (10 min)	
16:00	15:00-16:50 <u>Free papers</u> Innovation/ Commercialization/ Technology Moderators: Timothy King/ Masao Kakibuchi	<ul style="list-style-type: none"> ● PB3 Seung Han Song (Korea) Evolution of eyelid surgery with innovative AI tools ● P06 Itaru Tsuge (Japan) "Non-invasive visualization of the midline-crossing arterial variation in the deep inferior epigastric artery perforator flap using photoacoustic tomography" ● P81 Chia-Chun Lee (Taiwan) Macro-, Micro-, and Nano-Fat Grafting: Art, Philosophy, and Clinical Decision-Making ● P64 Kohei Mitsui (Japan)[Online] "Realization of XR technology applications in plastic and reconstructive surgery" ● P50 Yuichi Hatsuoka (Japan) Utilizing Virtual Reality for Suture Technique Education: Potential as an Auxiliary Tool for Independent Learning in Medical Students ● P70 Marika Otaki (Japan) Pathological Analysis of Unstained Mouse Skin Tissue ● PA6 Prasetyanugraheni Kreshanti (Indonesia) Development and Evaluation of Novel Interlocking Three-Dimensional Plate 2.0 System for Managing Mandibular Fractures ● P65 Tatsuya Kato (Japan) Observation the skin at the site of pressure ulcers predilection using the sheet-type sensor
17:00	16:50-17:50 <u>Free papers</u> Breast Moderators: Michael Findlay/ Tomoyuki Yano	<ul style="list-style-type: none"> ● PB1 Nicole Sanchez (USA) [Online] Effect of Inframammary Fold Skin Dome on Dehiscence Rates in Breast Reduction Surgery ● P10 Jeffrey M Rafael (Philippines) [Online] A rare encounter: Breast implant capsular contracture immediately preceded by herpes zoster, a case report ● P53 Benedetta Agnelli (Italy) Nipple-Sparing Mastectomy in Patients with Prior Breast Surgery: The Role of Autonomization in Preserving NAC Viability ● PB0 Nicole Sanchez (USA) [Online] Development of a 3D-Printed Chest Wall for DIEP Flap Anastomoses: Integrating Radiology Imaging, 3D Printing, and Special Effects Artistry for Hyper-Realistic Medical Simulation ● P59 Bolun Li (Japan) "The Investigation of Therapeutic or Preventive Effects of Adipose Derived Stem Cells on Radiation Induced Capsular Contraction Around Implant in Mouse Model"
18:00		

Day 2 (Oct 18, Fri) / IPSRC 2 (Room 3) [赤線付セッションは領域講習]

	Session / Moderators	Speakers / Talk topics
9:00		
09:00-10:20	Free papers Aesthetic/ Gender/ Cancer Moderators: Justin Lee/ Taku Maeda	<ul style="list-style-type: none"> P92 Dina M Badawi (Egypt) Optimizing scarless double chin treatment: Systematic plan through combining surgical, energy based, and manual techniques PB4 James Moore (USA) Carcinogenesis within free Latissimus-Dorsi flap donor site. A case report and literature review. P26 Tomoyuki Ito (Japan) Effects of PRP with basic fibroblast growth factor on human adipose tissue P46 Kuangyun Tang (China) A prospective and randomized study comparing ultrasound-guided real time injection to conventional blind injection of botulinum neurotoxin for glabellar wrinkles P96 Luis Antezana (USA) Institutional Experience of Female Perineal Reconstruction Post-EMPD - A Rare Entity's Reconstructive Challenge P05 Antoinette Nguyen (USA) Evaluating the Impact of Facial Feminization Surgery on Transgender and Gender Non-Conforming Individuals: A Prospective Cohort Study P18 Jinho Lee (Korea) Subfascial breast augmentation in transfemale patient: A report of cases P52 Austin Chen (USA) Fat Grafting for Facial Rejuvenation: A Systematic Review of Validated Patient-Reported Outcomes
10:00		
10:20-11:40	Keynote lectures Scar/ Mechano-biology Moderators: Summer Hanson/ Naoki Morimoto	<ul style="list-style-type: none"> Wei Liu Early wound intervention: a new concept in topical management of scars Rei Ogawa Mechanobiology and mechanotherapy for wound healing and scarring Geoffrey Gurtner Mechanical signaling in tissue injury Dennis Orgill Mechanical forces in wound healing
11:00		
11:40-12:10	Sponsored mini-seminar (DPB) Moderators: Eray Copcu	<ul style="list-style-type: none"> Tsai-Ming Lin Regenerative surgery breakthroughs: Fat grafting, stem cells, SVFs, and exosomes: Techniques, applications, and future prospects
12:00		
Coffee break (20 min)		
12:30-13:30	Luncheon session (Simultaneous screening of Room 6)	Microsurgery <ul style="list-style-type: none"> Michael Neumeister (Virtual live) Prefabrication of flaps in microsurgery Gender affirming <ul style="list-style-type: none"> Justin Lee Facial gender-affirming surgery William Kuzon Science vs. politics in transgender care
13:00		
13:30-14:40	Free papers Patient Safety/Education /Leadership Moderators: Justin Sacks/ Takuya Iida	<ul style="list-style-type: none"> P15 Satoshi Onoda (Japan) Super Microsurgical Education Using Papers with Online Video Clips P88 Cole Holan (USA) Weekday Timing and Surgical Outcomes: The Impact of Surgery Day on DIEP Flap Success P63 Toko Miyazaki (Japan) Handcrafted Artificial Vessels for Supermicrosurgical Training PA5 Jasmine Athiyya Wibowo (Indonesia) Live-Streaming Using Modified Head-Mounted Smartphone as An Assisting Learning Tools For Fisher Unilateral Cleft Lip Repair.
14:00		
Coffee break (10 min)		
14:50-17:50	Japan symposium Cell therapies in Japan Moderators: Peter Rubin/ Yusuke Shimizu	<ul style="list-style-type: none"> Rica Tanaka (Re Eir) "Simple, Effective and Safe" peripheral blood vascular stem cell therapy for tissue regeneration Hideyuki Takahashi (PuREC) Bone and Cartilage Regeneration with Extremely Purified MSC "REC" Kazuo Ohnishi (Cell Source) Early clinical applications of adipose-derived stem cells in Japan Masukazu Inoie (J-TEC) Current situation and challenges of regenerative medical products approved in Japan Yasuyuki Mitani (S-Quatre) Stem cells from human exfoliated deciduous teeth (SHED) for treating various intractable diseases Kazunori Shimomura (To-cell) Cartilage repair using mesenchymal stem cells
15:00		
16:00		
17:00		<ul style="list-style-type: none"> Panel discussion
18:00		

Day 3 (Oct 19, Sat) / PSRC 1 (Room 6) [赤線付セッションは領域講習]

Session / Moderators		Speakers / Talk topics
9:00	09:00-9:40 Free papers Others Keynote lectures Moderators: Shailesh Agarwal/ Yusuke Shimizu	<ul style="list-style-type: none"> P45 Risako Ito (Japan) First Attempt at Assessing the Effects of Animal-Assisted Therapy (AAT) on Plastic Surgery Patients P34 Kazufumi Tachi (Japan) Development of an AI-Powered System for Automatic Four-Class Classification and Area Measurement of Skin Ulcers ● Shailesh Agarwal Closed-loop cellular therapies for tissue engineering
10:00	9:40-10:20 Keynote lectures Stem cells 1 Moderators: Shailesh Agarwal/Yusuke Shimizu	<ul style="list-style-type: none"> ● Christina Camargo (Virtual live) Use of ASC in enterocutaneous fistula- Animal model ● Indranil Sinha (Virtual live) Scaffolds and stem cells for the treatment of volumetric muscle loss
11:00	10:20-11:20 Free papers/Keynote Skin/Burn/ Wound Healing 3 Moderators: Geoffrey Gurtner/ Michiharu Sakamoto	<ul style="list-style-type: none"> P29 Qiannan Zhao (Japan) Self-assembling MSC-sheet promotes wound healing increasing M2 macrophage polarization P54 Shigeki Sakai (Japan) Embryonic macrophages involved in skin regeneration ● Rica Tanaka Understanding impaired diabetic wound healing in cellular/molecular level
12:00	11:20-12:20 Keynote lectures Fat Moderators: Roger Khouri/ Hiroshi Mizuno	<ul style="list-style-type: none"> ● Paul Cederna The impact of autogenous fat grafting of neural regeneration ● Summer Hanson Autologous fat grafting in regenerative medicine: a natural scaffold for immunoengineering ● Feng Lu Clinical, histologic, and transcriptomic evaluation of sequential fat grafting for morphea
Coffee break (10 min)		
13:00	12:30-13:30 Luncheon session Keynote lectures Stem cells 2 Moderators: Dennis Orgill/ Rei Ogawa	<ul style="list-style-type: none"> ● Geoffrey Gurtner (30 min) Stem cells in wound healing and technologies for stem cell delivery to wounds ● Emi Nishimura (30 min) Stem cell fate determination and dynamics for regeneration and aging -Lessons from biology for better medicine-
14:00	13:30-14:50 Free papers Craniofacial/ Others Moderators: William Kuzon/ Ataru Sunaga	<ul style="list-style-type: none"> P66 Yoshitaka Kubota (Japan) Visualization of Chromosome-Specific Epigenetic Modifications for Fat Transplantation P07 Itaru Tsuge (Japan) Real-time navigation for thinning of anterolateral thigh flap using photoacoustic imaging and projection mapping P76 Kyoichi Murakami (Japan) The Sweat Secretion in the Pedicled Volar Skin Flaps in Rats P86 Motoki Katsube (Japan) Comparative study of fetal facial shape between Japanese and North American populations P28 Damian Palafox (Mexico) Fat Grafting for the Treatment of Velopharyngeal Insufficiency Secondary to Isolated and Syndromic Cleft Palate P94 Akishige Hokugo (USA) Sustained BMP-2 Release by Peptide Amphiphilic Nanofibers Enhances Craniomaxillofacial Bone Regeneration by Mitigating Early Inflammatory Response PA4 Takashi Kurabayashi (Japan) Correlation Between Microtia Ear Deformity and Middle Ear Development in 3D CT Scans. P14 Daisuke Mito (Japan) Research on the Optimization and Evaluation of an Autofluorescence Point-of-Care Device for Bacterial Species Identification
15:00	14:50-17:30 Free papers IPSRC best paper session Moderators: Dennis Orgill/ Yoshihiro Sowa	<ul style="list-style-type: none"> P90 Erika Guilpain Kusajima (Japan) Potential benefit of vascularized lymph node transfer on cancer progression P43 Yukari Nakajima (Japan) Exploration of Regenerative Factors in Murine Fetal Skin Wounds P40 Toko Oida (Japan) Relationship between epidermal keratinocyte division and Keratin17 in skin texture formation PA9 Khaled Alameddine (USA) AI-Driven Age Estimation for Evaluating Non-Surgical Facial Rejuvenation Techniques P58 Riho Takayanagi (Japan) Single cell analysis toward further investigation of the pathogenesis of keloids. P60 Guangpeng Xia (Japan) A Novel Diagnostic Approach for Keloids Using Proton Nuclear Magnetic Resonance with Time-frequency Analysis of Serum P47 Kento Hosomi (Japan) The possibility of phagocytes playing a role to control wound healing process in newts P27 Shengzhou Shan (China) Mechano-induced arachidonic acid metabolism promotes keratinocyte proliferation during skin expansion P12 Yi-Syuan Shin (Taiwan) Development of Automated Assessment and Classification of Open Wound using Deep Learning Approaches
16:00		Awarding ceremony/ Memorial photo
17:00		

Organizing committee

Peter Rubin (USA)
Kotaro Yoshimura (Japan)
Nelson Piccolo (Brazil)

Program committee

Weigang Cao (China)
Valerio Cervelli (Italy)
Amin Kalaaji (Norway)
Lee Pu (USA)
Chenggang Yi (China)
Michele Zocchi (Italy)
Nelson Piccolo (Brazil)

Aris Sterodimas (Greece)
Stefania de Fazio (Italy)
Dennis Orgill (USA)

招待演者



Kotaro
Yoshimura
(Japan)



Valerio
Cervelli
(Italy)



Dennis Orgill
(USA)



Peter J. Rubin
(USA)



Roger Khouri
(USA)



Nelson Piccolo
(Brazil)



Lee Pu (USA)



Aris
Sterodimas
(Greece)



Patrick
Tonnard
(Belgium)



Stefania de
Fazio (Italy)



Tim
Papadopoulos
(Australia)



Michele
Zocchi (Italy)



Marita
Eisenmann-Klein
(Germany)



Weigang Cao
(China)



Feng Lu
(China)



Alfred
Callanta
(Philippines)



Amin Kalaaji
(Norway)



Tsai-Ming Lin
(Taiwan)



Nobert Pallua
(Germany)



Eray Copcu
(Turkey)



Gino Rigotti
(Italy)



Kwangsik Kook
(Korea)



Chenggang Yi
(China)



Marco Klinger
(Italy)



Massimiliano
Branbilla
(Italy)

プログラム

- 1) Keynote speeches: Fat grafting and methods, Innovation, Reconstruction, Regeneration, Fat for the face, Fat for the breast, Body contouring, Cryopreservation, etc.
- 2) APRAS symposium
- 3) Free paper sessions (Sydney Coleman Award selection)

ISPRES Day 1 (Oct 17, Thurs, Room 7) [赤線付セッションは領域講習]

	Session / Moderators	Speakers / Talk topics
9:00	09:00-10:00 Free papers Reconstruction/ regeneration Moderators: Stefania de Fazio/ Ono Shimpei	<ul style="list-style-type: none"> R20 Cynthia I Euan Vazquez (USA) Fat tissue: a decisive treatment for the management of complicated wounds in a high morbidity patient. R05 Hasim Eray Copcu (Turkey) Activated Fat Grafting: A Novel Approach for Enhanced Fat Graft Retention and Natural Long-Term Results R45 Olivier Amar (UK) Cryopreservation of Adipose tissue: Changing the paradigm of regenerative medicine R48 Liu Chengsheng (China) Exploration of Injection Levels for Autologous Fat Transplantation Breast Augmentation Surgery
10:00	Coffee break (10 min)	
10:10-11:10	Keynote lectures Reconstruction/ regeneration 1 Moderators: Marco Klingner/ Tomoyuki Yano	<ul style="list-style-type: none"> Massimiliano Brambilla Fat graft for treatment of genital lichen sclerosis: safety, efficacy and long term follow up Nelson Piccolo Fat grafting for regeneration of the external female genitalia and vaginal laxity Stefania de Fazio Labia maiora: Regenerative and reconstructive genital plastic and aesthetic surgery
11:10-11:40	Sponsored mini-seminar (Brexogen) Moderator: Sue Kim	<ul style="list-style-type: none"> Taemin Kim Advances in regenerative medicine: therapeutic potential of cargo-controlled iMSC derived exosome Eray Copcu Unlocking the cellular symphony: P-exosomes from iPSCs-derived MSCs- Paradigm shift in regenerative medicine and surgery
	Coffee break (10 min)	
11:50-12:20	Sponsored mini-seminar (DPB) Moderator: Norbert Pallua	<ul style="list-style-type: none"> Tsai-ming Lin Pioneering precision: 15 Years of MAFT technique with over 6500 clinical cases - Insights and innovations from the inventor of MAFT-GUN
	Coffee break (10 min)	
12:30-13:30	Luncheon session Keynote lectures Regeneration Moderators: Peter Rubin/ Hajime Matsumura	<ul style="list-style-type: none"> Roger Khouri (30 min) Regenerative procedures that morph tissue to reconstruct without incisions Tim Papadopoulos The secret life of fat: The science behind the most misunderstood body organ Discussion
	Coffee break (20 min)	
13:50-14:50	Keynote lectures Grafting methods Moderators: Valerio Cervelli/Yuko Asano	<ul style="list-style-type: none"> Peter Rubin Human subject variation in fat graft survival Nobert Pallua The lipoconcentrate- an Approach to Improve the Outcome of Regenerative Plastic Surgery Treatments Chenggang Yi How to improve the effect of fat grafting and avoid the risk of vascular thrombosis
14:50-15:30	Keynote lectures Grafting methods Moderators: Valerio Cervelli/ Yuko Asano	<ul style="list-style-type: none"> Patrick Tonnard (Virtual live) How does nanofat work? A quantum biology hypothesis Patrick Tonnard (Virtual live) Nanofat microneedling as a routine anti-aging treatment in facial rejuvenation surgery
15:30-16:10	Keynote lectures Cryo-preservation Moderators: Lee Pu/ Yoshimichi Imai	<ul style="list-style-type: none"> Peter Rubin Cryopreservation of adipose tissue Lee Pu An update on cryopreservation of adipose tissue
	Coffee break (10 min)	
16:20-17:40	Free papers Research Moderators: Dennis Orgill/ Rei Ogawa	<ul style="list-style-type: none"> R41 Khaled Alameddine (USA) AI-Driven Age Estimation for Evaluating Non-Surgical Facial Rejuvenation Techniques R39 Koji Nishihori (Japan) Possibility of using AI deep learning to assist in the diagnosis of vascular and pigmentary disorders R07 Jiahao He (China) Mechanical stretch promotes hypertrophic scar formation by stimulating Schwann cells cholesterol biosynthesis R26 Kento Takaya (Japan) Challenges to Complete Skin Regeneration; Regulation of AMPK and Rac1 Activity Promotes Wound Healing via Induction of Actin Cable Formation R03 Yukun Liu (China) Targeting SIRT4/TET2 Signaling Alleviates Human Keratinocyte Senescence by Reducing 5-hmC Loss R25 Qi Shen (Japan) Optimization of an adeno-associated viral vector for keratinocytes in vivo
18:00		

ISPRES Day 2 (Oct 18, Fri, Room 7) [赤線付セッションは領域講習]

Session / Moderators		Speakers / Talk topics
9:00	09:00-10:00 Free papers Stem cells/ Tissue engineering Moderators: Eva Siolo/ Masao Kakibuchi	<ul style="list-style-type: none"> R04 Hasim Eray Copcu (Turkey) Examining Long-Term Responses of Diverse Human Body Systems and Disorders to Mechanically Obtained Fat-Derived Stromal Cells R28 Benedetta Agnelli (Italy) Frozen Assets: A Comprehensive Review of Adipose Tissue Cryopreservation Techniques and Our Personal Experience R34 Emiliano Bernuzzi (Italy) Innovative Solutions in Scalp Wound Reconstruction: Experience with NovoSorb® BTM R30 Andrew Salzberg (USA) THE "EMPANADA" REGENERATIVE IMPLANT FOR DIRECT TO IMPLANT BREAST RECONSTRUCTION
10:00	10:00-12:20 Best free papers Sydney Coleman award session Moderators: Stefania de Fazio/ Hiroshi Mizuno	<ul style="list-style-type: none"> R31 Jianbo Sang (China) Exploring Strategies to Enhance Fat Retention Rates-A Case Study on Breast Fat Grafting R02 Viacheslav Vasilyev (Russia) Management of radiation injury of the rectum with adipose-derived biomaterials injection. 10-year experience. R35 Ki Yong Hong (Korea) Superior retention of aged fat graft by supplementing young adipose-derived stromal cells in a murine model R27 Yoshitaka Kubota (Japan) Gene Therapy Using Adipocytes R18 Břetislav Lipový (Czech Republic) "Innovative approach to total skin substitute with 4th generation biomaterials" R16 Chang Cheng Chang (Taiwan) Exosomes Combined with Polymer Dots Dressings and 755 nm picosecond laser accelerate wound Healing in Nude Mice R17 Tung Dinh Nguyen (Vietnam) Using Bilateral Pedicled Transverse Rectus Musculocutaneous Flap and Fat Grafting for Autologous Breast Augmentation R06 Hasim Eray Copcu (Turkey) "Autologization of Exosome Therapies using De-Parenchymized Adipose Tissue Extracellular Matrix: A Novel Approach for Controlled Regenerative Medicine" R21 Cynthia I Euan Vazquez (USA) Advanced adipose-derived stem cell protein extracts (AAPE) as an alternative regenerative treatment option for bedridden patients. R38 Yu Chi Wang (Taiwan) Metabolic Control in Adipose-Derived Stem Cell Modulation of Dendritic Cell Maturation via Notch Activation Pathway R49 Christopher Khorsandi (USA) AlloClac, A novel Ready to Use Human Adipose Allograft: Characteristics and Biocompatibility <p>Awarding ceremony/ Memorial photo</p>
Coffee break (10 min)		
13:00	12:30-13:30 Luncheon session Keynote lectures Reconstruction & Regeneration 2 Moderators: Lee Pu/ Taku Maeda	<ul style="list-style-type: none"> Ewa Siolo Current trends in using fat grafting in nasal reconstruction & aesthetics Roger Khouri Regenerative Hand Surgery Marita Eisenmann-Klein Adipose tissue derived stem cells for chronic wounds (interdisciplinary with vascular surgeons)
14:00	13:30-15:10 Keynote lectures APRAS symposium Moderators: Florencio Lucero/ Yuko Asano	<ul style="list-style-type: none"> Alfred Callanta Unexpected remission: Psoriasis alleviation following full face fat grafting Kwangsik Kook Fat grafting SVF cells injection for scleroderma Kotaro Yoshimura Natural breast reconstruction with fat and hybrid Tsai-Ming Lin Rejuvenation of lower eyelids: from mission impossible to the power of fat grafting and stem cells Jae-Ho Jeong Bone tissue engineering within closed biologic space using SVF cells and bone substitutes
16:00	15:10-16:10 Free papers APRAS award session Moderators: Aris Sterodimas/ Shinsuke Akita	<ul style="list-style-type: none"> R46 Ki-Tae Kim (Korea) Extensive scar reconstruction with fat grafting and microcoring technology. R22 Jinho Lee (Korea) Use of resected fatty tissues and SMAS tissues auto-grafting in facial rejuvenation R19 Sakurako Murata (Japan) Latissimus Dorsi and Immediate Fat Transfer (LIFT) for Breast Reconstruction after Mastectomy: A Case Series R32 Wen-Hui Chen (Taiwan) Strategy for Treating Gummy Smile: A Simple and Powerful Resolution with Fat Grafting R13 Yuko Asano (Japan) Innovative Cultured Cell-Assisted Lipotransfer for Breast Reconstruction
Coffee break (10 min)		
17:00	16:20-17:40 Keynote lectures Regeneration Moderators: Summer Hanson/ Hiroshi Mizuno	<ul style="list-style-type: none"> Dennis Orgill Xenogenic Scaffolds Induce Stromal Tissues Marita Eisenmann-Klein Microfat for neuroma and phantom pain Nelson Piccolo Current uses of fat grafting in burns, Complex wounds and their sequelae Marita Eisenmann-Klein Adipose tissue derived stem cells for treatment of osteoarthritis (interdisciplinary with orthopedic surgeons)

ISPRES Day 3 (Oct 19, Sat, Room 7) [赤線付セッションは領域講習]

	Session / Moderators	Speakers / Talk topics
9:00	09:00-10:20 Free papers Keynote lectures Body contouring Moderators: Nobert Pallua/ Ken Arashiro	<ul style="list-style-type: none"> R14 Omar Tillo (UK) Safety of Brazilian Butt Lift Surgery (BBL): Insights from the UK Ban and National Guidelines R47 Tim Neavin (USA) Autologous Fat Transfer with PRP for Penile Augmentation: A Safe and Effective Procedure Performed Under Local Anesthesia Aris Sterodimas Composite body contouring using a novel radiofrequency energy modality assisted by stromal enriched lipograft Weigang Cao Application of fat grafting and liposuction combined with RFAL skin tightening technique in total body contouring procedures
10:00	10:20-12:20 Keynote lectures Face Moderators: Tim Papadopoulos/ Joseph Anthony	<ul style="list-style-type: none"> Weigang Cao Fat equalization in facial contouring and rejuvenation- Concept and Strategy Lee Pu Ethnic considerations in cosmetic facial fat grafting Aris Sterodimas Composite face lifting: Blending lipografting, helium plasma & exosomes Valerio Cervelli Fat grafting in face rejuvenation: new trends Ewa Siolo Evolution of fat grafting in facial regeneration & aesthetics -20 years experience Marco Klinger Fat in face surgery
11:00	Coffee break (10 min)	
12:00	12:30-13:30 Luncheon session (Simultaneous screening of Room 6)	<ul style="list-style-type: none"> Geoffrey Gurtner (30 min) Stem cells in wound healing and technologies for stem cell delivery to wounds Emi Nishimura (30 min) Stem cell fate determination and dynamics for regeneration and aging -Lessons from biology for better medicine-
13:00	13:30-15:30 Free papers Keynote lectures Breast 1 Moderators: Nelson Piccolo/ Koichi Tomita	<ul style="list-style-type: none"> R01 Viacheslav Vasilyev (Russia) The stability of the inframammary fold formed by loop suture during breast augmentation/reconstruction with fat grafting R37 Amani Landoulsi Helal (France)[Online] "Transformative Role of Autologous Fat Grafting in Breast Reconstruction: A Case Report" R29 Paulo Piccolo (USA) Nano fat grafting improves radiation skin changes in breast cancer patients Marco Klinger Fat in breast surgery Amin Kalaaji Hybrid (composite) implant-fat breast augmentation/revision Gino Rigotti (Virtual live) Fat grafting in aesthetic and reconstructive breast surgery: Synergy between biomorphogenesis and cryopreservation.
14:00	15:30-16:30 Keynote lectures Breast 2 Moderators: Amin Kalaaji/ Toshihiko Satake	<ul style="list-style-type: none"> Valerio Cervelli Hybrid breast augmentation: Just the cherry on top? Marita Eisenmann-Klein Microfat in Aesthetic and Reconstructive Breast Surgery Roger Khouri How to convert implants to fat without losing the augmentation
15:00	16:30-17:50 Free papers Face Moderators: Eva Siolo/ Natsuko Kakudo	<ul style="list-style-type: none"> R08 Melinda Lacerna (USA) Deep plasma skin resurfacing: Accelerated healing with human MSC exosomes R10 Dan Yan (China) A Clinical Study of Platelet-rich Fibrin Combined with Autologous High-Density Fat Transplantation in Augmentation Rhinoplasty R40 Smilja Tudjarova Gjorgova (North Macedonia) Synergy of facial aesthetic surgery with fat transfer maximizing facial beauty R36 Amani Landoulsi Helal (France)[Online] Adipose-Derived Stem Cell Injections to Improve Outcomes of Facial Fat Grafting: A Retrospective Study of 100 Patients R15 Chang Cheng Chang (Taiwan) 755-nm picosecond laser combined with bioactive polymer dots to reverse photo-damage on nude mouse model R12 Haihua Chen (China) High Double Eyelid Fold Correction Composite Using Fat Strip Transplantation and Pretarsal Orbicularis Oculi Flap R44 Hanjeong Lee (Korea) Facial liposuction and contouring with CT scan
16:00		
17:00		

Organizing committee

Kotaro Yoshimura (Japan)
Giovanni Botti (Italy)
Nariaki Miyata (Japan)

Program committee

Chris Patronella (USA)
Giovanni Salti (Italy)
Ken Arashiro (Japan)
Chia Chi Kao (USA)
Patrick Huang (Taiwan)
Akiko Imaizumi (Japan)
Taro Kono (Japan)

Adrian Ooi (Singapore)
Hideaki Sato (Japan)
Hyungjoon Seo (Korea)
Taejoo Ahn (Korea)

招待演者



Giovanni Botti
(Italy)



Chris
Patronella
(USA)



Tim
Papadopoulos
(Australia)



Patrick
Tonnard
(Belgium)




Nariaki Miyata
(Japan)



Roger Khouri
(USA)



Chia Chi Kao
(USA)



Sherri Roberts
(USA)



Giovanni Salti
(Italy)



Florencio
Lucero
(Philippines)



Patrick Huang
(Taiwan)



Nobutaka
Furuyama
(Japan)



Ken Arashiro
(Japan)



Hideaki Sato
(Japan)



Adrian Ooi
(Singapore)



Akiko Imaizumi
(Japan)



Bin Zhang
(China)



Peter Peng
(Taiwan)



Taro Kono
(Japan)



Woffles Wu
(Singapore)



Hongki Lee
(Korea)



Zhan Wang
(China)



Hyungjoon Seo
(Korea)



Taejoo Ahn
(Korea)



Ayaka
Nishikawa
(Japan)



Yoshio Ikeda
(Japan)



Masanori
Ohashi
(Japan)



Shinichi
Soyano
(Japan)



Susumu
Takayanagi
(Japan)

プログラム

- 1) Keynote speeches: Face lift, Surgery for the breast, Surgery for the body, Energy-based devices, Non-surgery for the face, BTX and HA injections, Facial rejuvenation, etc.
- 2) APRAS symposium
- 3) Japan-China-Korea joint session: Cutting edge of aesthetic medicine
- 4) JSAS session
- 5) Free paper sessions (Award selection)

TAAT Day 1 (Oct 17, Thurs, Room 8) [赤線付セッションは領域講習]

	Session / Moderators	Speakers / Talk topics
9:00	09:00-10:30 Free papers Surgical procedures Moderators: Tim Papadopoulos/ Asahi Rintaro	<ul style="list-style-type: none"> A07 Xin Cui (China) Abdominoplasty in the low BMI Asian Patient A08 Chao Xie (China) "Exploration of Visual Sculpture-Abdominal Sculpture of Chinese People" A03 Jinho Lee (Korea) "How to treat the ipsilateral sunken chest in augmentation mammoplasty" A09 Yanling Wen (China) "Safe and Effective Injection for Treating Pouches" A12 Yinan Zhou (China) "The Application of Light-Shadow Aesthetics in Cosmetic Injection" A10 Lina Liu (China) "Treatment Strategies for Post-Facial Fat Grafting Deformities" A28 Dina M Badawi (Egypt)[Online] "Optimizing scarless double chin treatment: Systematic plan through combining surgical, energy based, and manual techniques" A34 Yu Hua (China) A treatment plan for orbital aging A35 Qian Li (China) Bioactive glass in clinical applications
10:00	10:30-12:20 Keynote lectures Facelift Moderators: Adrian Ooi/ Susumu Takayanagi	<ul style="list-style-type: none"> Lee Pu Scarless mid-face lift: A less invasive approach for facial rejuvenation Tim Papadopoulos Anatomical considerations and surgical techniques in deep plane facelifts Woffles Wu Long Term Strategies with the Woffles Threadlift Chia Chi Kao Ponytail lift: A scarless total deep plane facelift for Asians Giovanni Botti (30 min) Facelift in 2024: doubts and certainties
11:00	Coffee break (10 min)	
12:00	12:30-13:30 Luncheon seminar (Metras Inc.) Moderators: Akiyoshi Takada	<ul style="list-style-type: none"> John Paul C. Pareja New era of power-assisted liposuction
13:00	13:30-14:30 Keynote lectures JSAS session Moderators: Taejoo Ahn/ Hideaki Sato	<ul style="list-style-type: none"> Ayaka Nishikawa Trends in skin rejuvenation and injectable therapies for Asians Yoshio Ikeda Asian trends of double eyelids surgery Masanori Ohashi Restoring youthful body contours: Hi-definition lipoplasty and advanced skin tightening techniques
14:00	Coffee break (10 min)	
15:00	14:40-16:20 Keynote lectures APRAS symposium Moderators: Florencio Lucero/ Hirokazu Uda	<ul style="list-style-type: none"> Adrian Ooi Algorithm for Asian upper eyelid rejuvenation Hyungjoon Seo Consideration factors for preparation of aesthetic orthognathic surgery Ken Arashiro Lipoabdominoplasty: Technical ingenuity for better results Taejoo Ahn Four direction ocular enlargement Woffles Wu The composite rhinoplasty and beyond
16:00	16:20-17:30 Free papers APRAS paper award session Moderators: Hyungjoon Seo/ Joseoh Anthony	<ul style="list-style-type: none"> A04 Jinho Lee (Korea) Challenges in primary rhinoplasty with autologous dorsal grafts: Comparison of homogenous grafts and hybrid autologous grafts A27 Jun Karibe (Japan) "Hair Regeneration Using Stem Cell-Conditioned Medium" A15 Hiroko Ochiai (Japan) "Factors Influencing Early Postoperative Swelling After Ptosis Surgery" A14 Chang Cheng Chang (Taiwan) Efficacy of early intervention using pulsed dye laser (PDL) for traumatic or postoperative scars improvement in Asian patients A33 Yu-chuan Yang (Taiwan)[Online] Preliminary Outcome of Enhansing Transdermal Delivery of Autofluorescence Nanoparticles Assisted of Picosecond Laser and Fractional CO2 Laser
17:00		Awarding ceremony/ Memorial photo
18:00		

TAAT Day 2 (Oct 18, Fri, Room 8) [赤線付セッションは領域講習]

	Session / Moderators	Speakers / Talk topics
9:00	09:00-10:50 Keynote lectures Japan-China-Korea Joint Session: Cutting Edge of Aesthetic Medicine Moderators: Giovanni Salti/ Tatsuro Kamakura	<ul style="list-style-type: none"> ● Bin Zhang The current status and forecast of medical aesthetics and plastic surgery industry in China ● Hideaki Sato Limitations and possibilities of non-surgical aesthetic medicine in Japan ● Hong-Ki Lee Facial overfilled syndrome - Where it has come from and where we should go? ● Zhan Wang Aesthetics energy-based device and injections in current private clinics of China ● Akiko Imaizumi Trends in Japanese aesthetic medicine from the perspective of dermatologist
11:00	Coffee break (10 min)	
11:00	11:00-12:20 Keynote lectures Breast Moderators: Tim Papadopoulos/ Toshihiko Satake	<p>Sherri Roberts Implementing a successful virtual consultation program to expand your profits & surgery schedule</p> <p>Giovanni Botti Ergonomic breast implants in breast augmentation</p> <p>Roger Khouri Breast Augmentation with Reverse Abdominoplasty and Fat Transfer: The RAFT Procedure</p> <p>Peter Rubin Dermal suspension mastopexy in massive weight loss patient</p>
12:00	Coffee break (10 min)	
13:00	12:30-13:30 Luncheon seminar (J. Hewitt Inc.) Moderator: Giovanni Salti	<p>PROFILO® STRUCTURA: THE NEW FRONTIER OF ADIPOSE TISSUE RESTORATION IN RESPONSE TO AGING</p> <ul style="list-style-type: none"> ● Giovanni Salti ● Minori Ueno ● Junko Seike
14:00	13:30-15:00 Keynote lectures Body contouring Moderators: Roger Khouri/ Ken Arashiro	<p>Peter Rubin Abdominal contouring in massive weight loss patient</p> <p>Chris Patronella Preserving hip projection with lower body lift surgery: A novel adipofascial flap</p> <p>Tim Papadopoulos Advances in abdominoplasty: Minimising risks and optimising results</p> <p>Chris Patronella (30 min) Restoring anatomical definition with abdominoplasty: sub-scarpa's fat sculpting and anatomy-defining progressive tension sutures</p>
15:00	15:00-16:20 Keynote lectures Laser and energy devices Moderators: Chia Chi Kao/ Akiko Imaizumi	<p>Nariaki Miyata What is difference in mechanism and clinical results among various kinds of energy-based devices for tightening?</p> <p>Patrick Huang Evaluating the effects of needling radiofrequency with and without exosomes: a 5-M split-face study</p> <p>Peter Peng Anatomy based tightening and lifting by combining different devices</p> <p>Taro Kono Laser treatment strategies for pigmented lesions</p>
16:00	16:20-17:40 Free papers TAAT best paper session Moderators: Weigang Cao/ Harunosuke Kato	<ul style="list-style-type: none"> ● A17 Haihua Chen (China) High Double Eyelid Fold Correction Composite Using Fat Strip Transplantation and Pretarsal Orbicularis Oculi Flap ● A24 I-Feng Sun (Taiwan) "The Rejuvenating Effect of Fat Grafting: Fiction or Fact" ● A06 Ming Ni (China) Plasma Radiofrequency-assisted Microliposuction for the Treatment of Facial Overfilled Syndrome Induced by Various Causes in Asians ● A21 Tien-Chun Tsai (Taiwan) "Improvement of visual acuity impairment in Poly-D,L-lactic acid injections by hyperbaric oxygen therapy" <p>Awarding ceremony/ Memorial photo</p>
17:00		
18:00		

TAAT Day 3 (Oct 19, Sat, Room 8) [赤線付セッションは領域講習]

	Session / Moderators	Speakers / Talk topics
9:00	9:00-10:20 Keynote lectures Face 1 Moderators: Giovanni Botti/ Yuzo Komuro	<ul style="list-style-type: none"> ● Tim Papadopoulos Anatomic considerations and surgical planning in lip lift bullhorn surgery ● Woffles Wu The role of epicanthoplasty to beautify the Asian face ● Chia Chi Kao Management of dark circles and under eye hollow ● Hyungjoon Seo Characteristics of short nose and diverse correction methods
10:00	10:20-11:20 Keynote lectures Face 2 Moderators: Woffles Wu/ Susumu Takayanagi	<ul style="list-style-type: none"> ● Taejoo Ahn Minimal-incisional ptosis correction and endoforehead lift: overcome shortcomings ● Chia Chi Kao Brow fashioning NOT brow lifting ● Giovanni Botti Blepharoplasty complications and their treatments
11:00	11:20-12:20 Keynote lectures BTX and HA injection Moderators: Giovanni Salti/ Shinichi Soyano	<ul style="list-style-type: none"> ● Nobutaka Furuyama Comprehensive approach of non-surgical total facial treatment — Bonsai aesthetics ● Woffles Wu Microtoxins and microfillers for face and neck rejuvenation ● Nariaki Miyata Filler injection: how to combine with EBDs and threads for natural looking
12:00	Coffee break (10 min)	
13:00	12:30-13:30 Lunch time break	(No program)
14:00	13:30-14:50 Keynote lectures Facial Rejuvenation (Non-surgery) 1 Moderators: Florencio Lucero/ Nariaki Miyata	<ul style="list-style-type: none"> ● Giovanni Salti Threads for the neck: principles and limitations ● Patrick Huang Exosome delivery via fractional CO2 laser stimulates hair regrowth in En Coup de Sabre morphea alopecia ● Giovanni Salti "Autologous Regenerative therapy: from lipofilling to stem cell regeneration in a simple office setting" ● Patrick Huang A split-face study: HIFU vs. HIFU + lyophilized platelet concentrates injection
15:00	14:50-16:10 Keynote lectures Facial rejuvenation (Non-surgery) 2 Moderators: Florencio Lucero/ Shinichi Soyano	<ul style="list-style-type: none"> ● Patrick Tonnard (Virtual live) Is aging a disease? Perspectives from a plastic surgeons view. ● Patrick Tonnard (Virtual live) Nanofat microneedling as a routine anti-aging treatment in facial rejuvenation surgery ● Giovanni Salti Polylactic acid for reshaping of the buttocks: indications and long term results ● Peter Peng Perioral rejuvenation-The best minimal invasive combination therapy
16:00	16:10-17:20 Free papers Non-surgery Moderators: Peter Peng/ Taro Kono	<ul style="list-style-type: none"> ● A13 Shuaihua Li (China) "Application of Collagen Combined with Botulinum Toxin in the Treatment of Periorbital Aging" ● A23 Ching-En Chen (Taiwan) "A Cutting-Edge Strategy for Prevention the Severe Complications in Filler Injection and Fat Grafting" ● A22 Kento Takaya (Japan) Efficacy of 730nm Picosecond Laser on Acquired Dermal Melanocytosis in Asian Women ● A29 Luis Antezana (USA) "Peeling Back the Layers: A TikTok Analysis of Chemical Peel Content" ● A31 Hui-Hui Zhao (China) An injection method that uses "HA" to improve perioral aging ● A32 Xiang Wang (China) An improved injection method for non-painful abobotulinumtoxin A to lift the entire face ● A19 Hsinkai Chen (China) "The Experience of Nasal Injection Therapy in 1981 Patients with Combination Materials about HA,PCL,CaHA and Thread"
17:00		
18:00		

E-poster 発表一覧 (Zoom Event 内でご覧いただけます)

第 33 回日本形成外科学会基礎学術集会

J19	亀倉 暁	関東労災病院 整形外科	光超音波イメージングによる切断指再接着術後の吻合血管の検討
J60	山門 希実	帝京大学医学部 形成口腔顎顔面外科	リビッドバブルと超音波とを併用した in vivo インプラント型軟骨組織再生の試み
J76	檜山 和也	長崎大学 形成外科	ケロイド由来線維芽細胞及び正常皮膚由来線維芽細胞を用いた RNA-seq 解析
J80	井上 唯史	洛和会音羽病院 形成外科	皮下線維束組織を用いたリンパ管静脈吻合術

IPSRC

P22	Hyungsuk Yi	South Korea	Minimum Number of Sutures for Microvascular Anastomosis during Replantation
P32	Junya Oshima	Japan	Effect of basic fibroblast growth factor in perifascial areolar tissue transplant
P37	Austin Chen	USA	Transforming Aesthetic Surgical Education Using Artificial Intelligence
P39	Kuang-Ling Ou	Taiwan	Three-Dimensional Printing cells laden F127 on Gelatin/Alginate Scaffold Promote Wound Recovery
P51	Yuki Ohtake	Japan	Preliminary Investigation Comparing Intraocular Pressure in Glaucoma Patients Before and After Blepharoptosis Surgery: Potential Impact in Intraocular Pressure Based on Surgical Technique
P72	Toshihiro Fujiwara	Japan	Adipose-derived stem/stromal cells from young mice promote wound healing in aged mice through the regulation of ROS homeostasis by extracellular superoxide dismutase.
P73	Takayuki Ueda	Japan	A Report of Complications Associated with Cyanoacrylate Closure for Varicose Veins
P98	Ho Yun Chung	South Korea	Comparative response to VEGF between normal and arteriovenous malformations endothelial cells
P99	Ho Yun Chung	South Korea	MicroRNA-135b-5p as a potential biomarker in the endothelial cells of arteriovenous malformations

ISPRES

R33	Chuan Han Ang	Singapore	Overcoming the three-dimensional complexity of vulvar defects: a stepwise, multi-flap approach
-----	---------------	-----------	--

TAAT

A18	Austin Chen	USA	Global Interest in Glucagon-like Peptide-1 Agonists for Weight Loss and its Impact on Aesthetic Surgery
-----	-------------	-----	---

一般演題 (口演) | 一般演題 6 (血管・リンパ管)

J03

補体欠損リンパ浮腫モデルでは CD4⁺T 細胞の浸潤が増加する西岡 俊彦 (にしおか としひこ)¹、井上 徳光²、片山 圭一²、山田 源¹、朝村 真一¹¹ 和歌山県立医科大学 形成外科学講座² 和歌山県立医科大学 分子遺伝学講座

【目的】

リンパ浮腫患者の皮膚や皮下組織においては、多様な免疫細胞の浸潤が確認され、特に CD4⁺T 細胞が線維化やリンパ管機能障害といったリンパ浮腫の進行に関わっていることが報告されている。しかしながら、リンパ浮腫の進行機構に関しては、多くの点で未解明である。過去の報告では、マウス尾部リンパ浮腫モデルにおいて自然免疫の1つである補体系の遺伝子発現の上昇が確認されているが、リンパ浮腫組織における補体の活性化の有無やその役割については明らかではない。今回、リンパ浮腫の進行機構のさらなる解明のため、補体欠損モデルを用いてリンパ浮腫組織における補体活性化の関与について解析したので報告する。

【方法】

リンパ浮腫組織における補体因子の発現および補体の活性化を調べるために、術後 3 週の尾部リンパ浮腫組織で real-time RT-PCR および蛍光免疫組織染色を用いて検討した。C3 欠損マウスおよび C5 欠損マウスを用いて、術後の尾部浮腫体積の測定や組織学的検討を行い、野生型と比較した。

【結果】

C3 の遺伝子発現の上昇が尾部リンパ浮腫組織で検出され、C3 タンパク質はリンパ浮腫組織の拡張したリンパ管周囲に分布がみられた。また、C3 と共局在する形で C4 も検出され、リンパ浮腫領域における古典経路またはレクチン経路の活性化が示唆された。C3 欠損マウスでは野生型との比較で、CD4⁺T 細胞の浸潤の増加と死細胞の増加が認められた。

【考察】

本研究から、リンパ浮腫の進行に伴う組織損傷が古典経路またはレクチン経路の活性化を誘発し、慢性炎症を引き起こしている可能性が示唆された。さらに C3 欠損による死細胞の除去機構の障害が、死細胞の増加および CD4⁺T 細胞浸潤の増加を促進する一因となっていることが示唆された。

一般演題 (口演) | 一般演題 4 (皮膚創傷治療 3)

J05

Burn wound conversion 研究のための新しいマウス熱傷モデル

松田 識郁 (まつだ のりふみ)¹、佐藤 千草¹、石川 耕資¹、前田 拓¹、三浦 隆洋¹、舟山 恵美¹、
大西 俊介²、山本 有平¹

¹ 北海道大学 大学院医学研究院・医学院 形成外科学教室

² 北海道大学 大学院薬学研究院 分子細胞医薬学

【目的】広範囲熱傷は未だに致死率の高い外傷であり、熱傷面積は生命予後に大きく関わる要因である。古典的な Jackson の Zone 分類のうち、Zone of stasis は不安定であり、経時的に壊死領域に移行することがある。この概念を Burn wound conversion と呼ぶ。Burn wound conversion を防ぐことで、熱傷面積の拡大を防ぎ、生命予後を改善することが期待されており、多くの基礎研究がなされてきたが、その病態生理は十分には解明されていない。その基礎研究の多くはラットを用いた Comb model において行われてきたが、マウスはラットと比べ、実験試薬が多く、遺伝子改変モデルを作製しやすいため、マウスを用いることでより多面的な研究が可能となる。そこでマウスを用いて、Burn wound conversion を模した新しい熱傷モデルを作製することを目的とした。

【方法】ICR マウス雄 75 匹を用いて、以下の 3 群を作製し、各群を比較した。沸騰したお湯で十分に温めた金属テンプレートで、マウスの側腹部左右 2 ヶ所に 5 秒間 (5s 群)、15 秒間 (15s 群)、25 秒間 (25s 群)、それぞれ接触させ、熱傷創を作製した。受傷 96 時間後に創の写真撮影を行い、金属テンプレート非接触部の壊死領域と生存領域の面積を計算した。また受傷 1 時間後、12 時間後、24 時間後、48 時間後、96 時間後に創から皮膚を採取し、組織学的評価を行った。

【結果】5s 群では Burn wound conversion がわずかしこ生じず、25s 群ではほとんどの組織が壊死したため、動物モデルとしては不適切であると判断した。15s 群では Burn wound conversion が適度に生じており、壊死領域と生存領域が混在していた。受傷 96 時間後の生存面積割合は、5s 群で $20.1\% \pm 0.6\%$ 、15s 群で $9.6\% \pm 0.6\%$ 、25s 群で $3.7\% \pm 0.8\%$ であり、いずれの群間でも有意差を認めた。組織学的評価では、皮膚付属器と皮下筋層に受傷 1 時間後から変性を認めた。

【考察】15s 群が再現性高く Burn wound conversion を表現できるモデルであると判断した。組織学的評価から、皮膚付属器と皮下筋層の変性は Burn wound conversion の早期診断および治療介入の手がかりとなりうることを示唆された。

一般演題 (口演) | 一般演題 4 (皮膚創傷治癒 3)

J06

オートロジェルシステム®と既存 PRP 療法の創傷治癒における比較検討

島田 和樹 (しまだ かずき)、小宮 貴子、小田 柚香、荒木 祐太郎、浅井 麻衣香、青木 昂平、松村 一

東京医科大学病院 形成外科

【目的】本邦の難治性皮膚潰瘍に対する多血小板血漿療法には多血小板血漿処置 J003-4 として行われる既存 PRP 療法とオートロジェルシステム® (本システム) がある。本システムの主な特徴は single spin 処理による PRP 調製、塩化カルシウム及びトロンビンによる PRP の活性化並びにつど採血である。既存 PRP 療法では、各社から販売されている機器を使用するため PRP 調製法が統一されていない事、PRP の活性化を含まない事及び凍結保存が可能な事である。以上より、これらの PRP 療法は異なる特徴を有することから、今回、ラット創傷皮膚モデルを用いて、既存 PRP 療法と本システムの創傷治癒に対する効果を比較した。

【方法】本システムではラット血液の single spin 処理及び PRP の活性化により PRP ゲルを作製した。既存 PRP 療法は、double spin 処理により PRP を調製した。ラット背部に直径 8mm の創傷皮膚をつくり、本システムの PRP ゲルは臨床試験を参照して 120 μ L を、既存 PRP 療法は「多血小板血漿 (PRP) を用いた難治性皮膚潰瘍の治療について」(日本皮膚科学会)を参照して 10 μ L を塗布し、塗布 7 日後まで創傷面積を測定した。また、塗布 1、2 及び 7 日後に 3 匹ずつの創部の病理を評価した。

【結果】本システム PRP ゲルの創傷面積は既存 PRP 療法と比較して塗布 7 日後に有意に縮小した。病理では、塗布 1 及び 2 日後にフィブリン沈着、好中球浸潤、線維化、血管増生に関して、本システム PRP ゲルで高いスコアを示す個体が多くみられた。

【考察】塗布 1 及び 2 日後の病理評価では、本システム PRP ゲル塗布は細胞増殖期に関連する変化が既存 PRP 療法よりみられた。慢性創傷は炎症期から細胞増殖期へ移行できずに炎症が遷延したものと考えられていることから、早期の細胞増殖期に関連する反応の結果、塗布 7 日後に創傷面積が PRP 塗布より縮小したと考えられた。以上より、本システムは既存 PRP 療法より治療効果が高いことが示唆された。

一般演題 (口演) | 一般演題 8 (AI ほか)

J08

生体吸収性マグネシウム骨接合材開発に向けたブルシャイト皮膜処理の有用性の検討

遊佐 優 (ゆさ ゆう)¹、清水 良央^{1,2}、岡田 誉元¹、林 昌伸¹、佐藤 顕光¹、三浦 千絵子¹、
泉 万祐子²、今井 啓道¹¹ 東北大学医学系研究科 形成外科学分野² 日本パーカライジング (株)

【目的】生体吸収性骨接合材の理想的な新素材としてマグネシウム合金の研究が国内外で盛んに行われている。しかし、マグネシウムは吸収過程でガスを発生し、また腐食環境に応じて腐食速度が異なることが知られている。臨床応用する際には手術侵襲や骨折部からの出血により、マグネシウムの腐食が促進されるため、腐食を適切に制御する方法として皮膜処理技術が行われることがある。中でも、リン酸カルシウムによる皮膜処理方法には生体安全性があり、また骨形成を促す作用が期待できるため有用な手段の 1 つである。今回抗腐食処理としてリン酸カルシウムの 1 つであるブルシャイト皮膜処理の有用性について検討した。

【方法】99.9%純マグネシウム (未処理群) とブルシャイト皮膜処理 (皮膜処理群) を施したマグネシウム基材を、ラットの大腿骨で出血モデルを作成して埋植した。埋植後の基材を埋植 1、3、7、14 日後に取り出し、重量減少と表面に析出した不溶性塩について分析を行った。分析手段として SEM-EDX、ラマン分光法、ICP-MS を用いた。

【結果】皮膜処理の有無に関わらず埋植後は経時的に腐食速度が遅くなったが、ブルシャイト皮膜処理を行うと腐食が抑制された。また、未処理群では埋植初期に表面にマグネシウムの分布が多く、析出する不溶性塩は炭酸塩とリン酸塩が混じったものであった。一方、皮膜処理群では早期にリン酸塩による表面皮膜を形成していることが確認された。

【考察】未処理群試料と比較し、皮膜処理試料は腐食に伴う不溶性塩の構造が異なり、出血環境でも埋植初期から安定した不溶性塩を形成することで腐食を抑制していると考えられた。ブルシャイト皮膜処理は他のリン酸カルシウムよりも皮膜処理技術が容易であり、皮膜処理に有用であると考えられた。

J12

Buccal fat pad の解剖学的検討

坂本 好昭 (さかもと よしあき)¹、中西 雄二²、今西 宜晶³、陳 建穎²、田中 克弥²、高詰 佳史³、
貴志 和生¹

¹ 慶應義塾大学医学部 形成外科

² 表参道スキンクリニック

³ 慶應義塾大学医学部 解剖学教室

【目的】Buccal fat pad は形成外科医にとってなじみの深い解剖構造であろう。その発見の歴史は古く、発見者については議論があるが、現在のところ 1801 年フランスの解剖学者 Xavier Bichat が初めて記述したとされている。しかしながらその構造について解剖学的な検討は十分には行われておらず、統一の見解が出てるとは言い難い。

【方法】新鮮遺体ならびにホルマリン固定遺体を用いて頬部解剖を行った。体表から層解剖を行い、Buccal fat pad の構造を確認した。また一部の遺体にはあらかじめ酸化鉛を全身動脈に注入後、Buccal fat pad を摘出し、レントゲン撮影を行い栄養血管の走行の確認を行った。

【結果】Buccal fat pad は従前から指摘されているように中央部の Body と側頭窩に向かう temporal extension、そして咬筋前縁で最も浅層に位置する buccal extension の 3 構造が確認できた。栄養血管は顎動脈から分岐するものがメインであり、これら 3 構造の血流は linking していた。また Buccal fat pad を支えるいくつかの ligament が確認できた。

【考察】実臨床において、Buccal fat pad は整容面改善のために摘出したり、あるいは脂肪弁として挙上する報告がある。摘出に関しては口腔内からは body と temporal extension の摘出は容易であるが、buccal extension は顔面神経頬枝に近接しており、損傷リスクが高いことが示唆された。また脂肪弁としての挙上に当たってその血管走行を理解しておくことは大切であると考え。

一般演題 (口演) | 一般演題 4 (皮膚創傷治癒 3)

J13

陰圧閉鎖療法 (NPWT) を用いた植皮固定至適圧の検討

橋本 葵 (はしもと あおい)¹、塗 隆志²、太田 穂子²、梅田 千鶴²、上田 晃一²¹ 守口敬仁会病院 形成外科² 大阪医科薬科大学 形成外科

【目的】近年陰圧閉鎖療法 (NPWT) による植皮固定の報告が散見されているが、吸引圧と移植皮膚への圧迫圧との相関は明らかになっていない。体圧測定装置である Pico Press®を用いて、NPWT の吸引圧と皮膚の圧迫圧の相関について明らかにする。従来の Tie over dressing では至適圧迫圧は 20mmHg とされており、NPWT による植皮固定に十分な吸引圧を測定する。

【方法】検討 1: 健常人の足背、下腿、大腿に Pico Press®センサーを貼付し、その上から 3M™ V.A.C.®型陰圧維持管理装置を装着する。陰圧維持管理装置の陰圧を変化させながらそれぞれの圧迫圧を測定した。また足関節、膝関節にも同様に装着し、屈曲角度を変化させながら測定を行った。検討 2: 人工皮膚シートを用いて潰瘍モデルと植皮モデルを作成し、検討 1 と同様に陰圧に対する実際の圧迫圧の測定を行った。植皮モデルはシート状、ドレーン孔を開けたものの、メッシュ状を作成し、また植皮モデルの固定を 4 点留め、連続縫合と圧着程度に差をつけた。

【結果】検討 1 では陰圧の上昇と圧迫圧に相関を認めなかった。足関節部では陰圧の上昇に反して圧迫圧が低下した。膝関節部では屈曲角度の上昇に伴って圧迫圧が上昇した。検討 2 では植皮モデルを連続縫合で密に固定した場合、陰圧に応じて圧迫圧が上昇した。連続縫合に加えてドレーン孔を作成すると陰圧の上昇に伴い圧迫圧も上昇し-50mmHg の吸引圧で 30mmHg の圧迫圧を得られた。

【考察】NPWT による植皮固定では圧迫 (compression) よりも圧着 (bonding) が重要である可能性が考えられる。植皮片を密に固定し、ドレーン孔を作成することで皮膚と移植床の間に陰圧がかかり、皮膚が移植床へ圧着されることで NPWT による陰圧が実際の圧迫圧に効果的であることが考えられる。

一般演題 (口演) | 一般演題 10 (レーザー)

J14

乳児血管腫のレーザー治療効果に対する客観的評価方法の確立と従来の視覚評価法との比較検討

森久 陽一郎 (もりひさ よういちろう)¹、力丸 (西) 由起子²、王丸 陽光³、井野 康⁴、姉川 美奈²、寺田 小百合²、力丸 英明²、清川 兼輔²

¹ 国立病院機構九州医療センター形成外科

² 久留米大学形成外科・顎顔面外科

³ 王丸クリニック

⁴ 飯塚病院形成外科

【目的】乳児血管腫 (IH) は、乳児期の一般的な良性腫瘍である。ほとんどの IH は自然に解消するが、皮膚潰瘍形成、機能障害、または美容上のために治療が必要なものもある。通常、血管腫のような赤色病変に対するレーザー治療の効果判定は、治療前後の画像を見比べて 4～5 段階での視覚的評価で行う主観的であまりよいものである。

皮膚分析装置の ANTERA3D™ を用いて IH のヘモグロビン濃度を数値化し、レーザー治療の効果を客観的に評価する方法を確立する。

【方法】2012-2015 年において、レーザー法のみで治療された IH 81 症例を対象に行った。研究期間における治療前と観察期間における最終取得画像に基づいて、従来の視覚的 4 段階評価を行った。評価は poor/fair/good/excellent のいずれかに分類された。次いで、同じ画像を用いて、治療前後の病変および病変周囲の正常皮膚のヘモグロビン濃度を数値化した。この数値から赤色比を算出し、さらに計算式を設定して、赤色比から改善差および改善率をそれぞれ算出した。また、赤色比および改善差と改善率の 3 つの評価基準と視覚評価の相関性について統計学的検定を行った。

【結果】1 症例あたり平均 4.3 回の治療を行っていた。全例の 60.1% が good / excellent であった。視覚評価で分類されたレーザー治療後の各群では、治療後赤色比および改善率について統計学的有意差があった。また、改善率と視覚的 4 段階評価には統計学的に相関性があった。

【考察】これまで主観的に評価されていた乳児血管腫に対する治療効果判定を、ANTERA3D™ を用いて IH のヘモグロビン濃度を数値化し赤色比、改善差、改善率を算出することで客観的に治療効果判定が可能となった。これにより今後は色素性病変の治療法や治療機器や施設間の比較が可能になると考える。

一般演題 (口演) | 一般演題 1 (腫瘍・移植ほか)

J15

当科における基底細胞癌治療の変遷と切除マージン 2mm 以下の症例の術後経過に関する検討

京野 香織 (きょうの かおり)^{1,2}、黒瀬 顕²、樋口 彩子¹、葛西 沙弥佳¹、飯田 圭一郎¹、
和田 尚子¹、三上 誠¹、漆館 聡志¹

¹ 弘前大学形成外科

² 弘前大学大学院医学研究科 病理診断学講座

【目的】NCCN ガイドラインは、基底細胞癌(BCC)の手術における切除マージンを低リスク群と高リスク群に分けて検討し、低リスク群では4mm を推奨している。近年本邦から、4mm未満の切除マージンで切除し高確率で断端陰性であったという報告があり、切除マージンを縮小した手術でも根治できる可能性が示唆されている。今回、当科において手術した BCC のうち、2mm以下の切除マージンで切除した症例の術後経過について検討した。

【方法】診療録より 2013 年 1 月 1 日から 2022 年 12 月 31 日に当科で切除術を行った BCC のうち、術後 1 年以上経過観察している症例を抽出し、BCC の部位、腫瘍長径、腫瘍の境界、色素の状態と断端の評価と組織型、局所再発の有無を調査した。さらに 1 期的に切除し治療した群と 2 期的に切除し再建した群とで局所再発の有無を比較検討した。

【結果】BCC 切除症例の総数は 112 例であり、そのうち 2mm 以下の切除マージンで切除したものは 53 例であった。部位では、鼻部 26 例、眼瞼 15 例、内眼角部 5 例、頬部 3 例の順に多く、それ以外の顔面が 3 例、殿部が 1 例であった。腫瘍長径は平均 8.3mm で、組織型は結節型が 44 例、微小結節型が 2 例、浸潤型が 3 例、混合型が 4 例であり、境界明瞭かつ有色素性の BCC は 16 例で、そのうち結節型は 13 例(85%以上)であった。切除断端は結節型と浸潤型の混合型の 1 例を除きすべて陰性で、陽性例に対しては拡大切除を施行し、53 例全てにおいて局所再発を認めなかった。1 期的に切除し治療した群は 24 例、2 期的に切除し再建した群は 29 例ありいずれの群においても断端陰性を確認しており、局所再発の有無に差は認めなかった。

【考察】本邦における BCC は結節型が多く、境界明瞭かつ有色素性である場合が多い。このような症例では 2mm 以下の切除マージンで切除した場合でも、断端陰性であることが多く、より少ない切除範囲でも根治が得られる可能性が示唆された。

一般演題 (口演) | 一般演題 1 (腫瘍・移植ほか)

J16

メラノーマに対する腫瘍溶解性ウイルスと抗 PD-1 抗体の併用療法によるリンパ系の免疫賦活化に関する検証

佐々木 雄輝 (ささき ゆうき)、前田 拓、三浦 隆洋、石川 耕資、舟山 恵美、山本 有平

北海道大学 大学院医学研究院 形成外科学教室

【目的】本研究では、腫瘍溶解性ウイルスと免疫チェックポイント阻害薬の併用療法によって、リンパ組織において免疫系がどのように賦活化されているかについて、動物モデルを用いて検証した。【方法】単純ヘルペスウイルス 1 型の弱毒化株である Canerpaturev (C-REV) とマウス抗 PD-1 抗体を用いた。マウスメラノーマモデルを作成し、投与薬剤によって各群に割り付けた。in vitro および in vivo における併用療法の抗腫瘍効果を検証し、リンパ組織における免疫系の変化を評価した。【結果】C-REV 抗 PD-1 抗体の併用療法は、リンパ組織におけるリンパ球集団を変化させ、より腫瘍を抑制する方向に免疫系を活性化した。【考察】免疫チェックポイント阻害薬は、メラノーマの薬物療法において中心的な薬剤であるが、一次耐性や二次耐性の問題があり、その奏効率には限界がある。奏効率を高めるために、様々な薬剤の併用療法が行われてきたが、副作用の問題から現状用いられている薬剤は限られている。免疫チェックポイント阻害薬と腫瘍溶解性ウイルスの併用療法には、これまでの免疫チェックポイント阻害薬の限界を突破できる可能性がある。

一般演題 (口演) | 一般演題 3 (皮膚創傷治癒 2)

J17

線維化を制御するイモリ免疫細胞の可能性

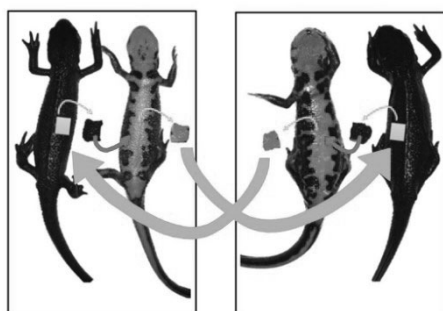
細見 謙登 (ほそみ けんと)¹、丸山 和晃²、今中 恭子²、俵 功³、白石 真士⁴、成島 三長¹¹ 三重大学形成外科² 三重大学修復再生病理³ 三重大学血液内科⁴ 東京大学形成外科

【目的】植皮術後に生じる整容性や瘢痕拘縮における問題には、移植片への炎症反応鎮静化までの創傷治癒過程における免疫応答が深く関わるため、免疫系を制御して線維化を最小限にする治療法の開発が期待されている。優れた組織再生を誇るイモリは線維性組織を残存させずに創傷治癒が可能である。ヒトで強い拒絶反応が生じる非自己組織移植に対するイモリの免疫応答を観察することで、組織再生に寄与する免疫応答を明らかにすることが本研究の目的である。

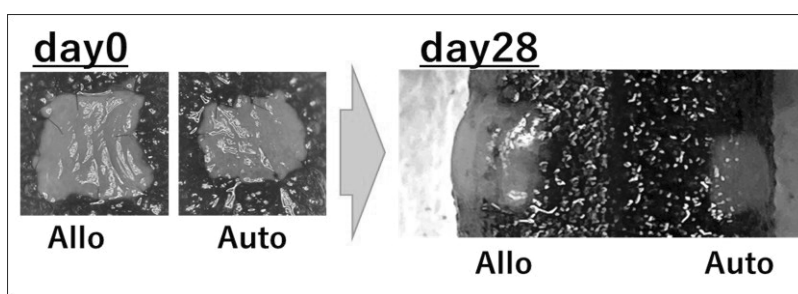
【方法】イモリ腹部皮膚(赤色)を採取し、背部(黒色)に作成した皮膚欠損創へ移植するモデルにおいて非自己組織移植(Allograft)と自己組織移植(Autograft)への反応を比較検討するため、移植片の経時的变化を肉眼的・組織学的に解析した。免疫細胞の中で貪食能を持つ細胞を標識するために墨汁を用いて末梢血中および組織中の貪食細胞の検出を試みた。

【結果】Allograft に対し、初期に組織内の血管新生が起き、後に血管網が消失していくという、ヒト同種植皮片への拒絶反応に類似した反応が観察された。しかしその後イモリでは移植片が脱落せずに結合し、数ヶ月かけて徐々に周囲の自己組織が非自己組織を置換していく現象が確認された。組織学的には、移植片の下床に分厚い線維性組織が一時的に出現したが、数ヶ月かけて退縮する経過が明らかになった。線維性組織が厚い時期には非自己組織片の全体に及ぶ免疫細胞の劇的な集簇が確認された。墨汁を取り込んだ細胞を末梢血中と組織中で確認し、移植後の組織中に経時的に増加・減少する挙動が明らかになった。

【考察】高い組織再生力を持つイモリにおいて、Allograft 後に発生した線維性組織を見事に退縮させる過程を発見し、さらに Autograft ではみられない免疫細胞の集簇、特に貪食細胞の関与を明らかにした。本モデルを活用し、組織移植後の線維化を抑える免疫細胞の役割・機能を明らかにしていきたい。



非自己組織移植モデル



Allograft と Autograft への反応の違い

一般演題 (口演) | 一般演題 2 (皮膚創傷治癒 1)

J18

羊膜由来間葉系幹細胞の抗菌活性と感染性糖尿病性潰瘍モデルマウスにおける効果

石井 陸 (いしい りく)¹、石川 耕資¹、前田 拓¹、三浦 隆洋¹、舟山 恵美¹、北條 正洋¹、大西 俊介²、山本 有平¹¹ 北海道大学 大学院医学研究院 形成外科学教室² 北海道大学 大学院薬学研究院 分子細胞医薬学教室

【目的】糖尿病性潰瘍は皮膚及び深部組織の破壊性病変で難治性かつ予後不良である。間葉系幹細胞は様々なサイトカインを産生し、血管新生、抗炎症、神経再生促進など、創傷治癒を促進する作用を持つ。また細菌増殖を抑制する作用も報告されており、感染制御にも有用と考えられる。間葉系幹細胞は種々の組織から採取可能であるが、特に羊膜由来のものは分娩後に通常は廃棄される胎盤から侵襲なく大量に採取することが可能であり、また胎児由来の幹細胞であるため細胞機能が高く、より大きな効果が期待できる。羊膜由来間葉系幹細胞 (amniotic-derived mesenchymal stem cells, AMSC) の感染性糖尿病性潰瘍の細菌抑制作用について検討する。【方法】AMSC の培地を採取・濾過し、培養上清を作成した。液体培地中の黄色ブドウ球菌に AMSC 培養上清を加え、細菌増殖の抑制効果について評価した。また ELISA で培養上清中の抗菌活性物質である LL-37 について評価した。6 週齢雄の ICR マウスにストレプトゾトシンを腹腔内投与し糖尿病を誘導した。投与 4 週後にマウスの背部に直径 8mm の皮膚全層欠損創を作成し、黄色ブドウ球菌の細菌懸濁液を塗布した。感染成立を確認した後に培養上清ゲルを塗布し、潰瘍面積の経時的変化と 10 日目の潰瘍の細菌数を評価した。

【結果】in vitro において AMSC 培養上清は黄色ブドウ球菌の増殖を抑制した。ELISA では培養上清中に LL-37 が検出された。in vivo において AMSC 培養上清はマウスの感染性糖尿病性潰瘍の細菌数を減少させ、創傷治癒を促進させた。組織学的にも血管新生や細胞増殖が盛んであり、好中球の浸潤も減少していた。また創傷治癒スコアリングにおいても有意に高いスコアを示した。

【考察】既報において他ソース由来の間葉系幹細胞の細菌抑制作用は報告があるが、羊膜由来間葉系幹細胞についてはない。本実験によって AMSC は細菌増殖抑制作用を持ち、その本態は LL-37 であることが示唆された。また、AMSC は糖尿病マウスの感染創に対する細菌抑制効果と創傷治癒促進効果をもつことが示唆された。

一般演題 (e ポスター)

J19

光超音波イメージングによる切断指再接着術後の吻合血管の検討

亀倉 暁 (かめくら さとる)、深澤 克泰

関東労災病院 整形外科

【目的】光超音波イメージングを用いて、切断再接着指の吻合血管および末梢血管の検討を行う。

【方法】光超音波イメージング photoacoustic imaging (PAI) は、レーザー等のパルス光を照射された吸収体が熱膨張を起こすときに生じる超音波（光音響波）を画像化する技術である。超音波イメージング装置は Luxonus 社の研究用機器を用いた。2 波長（756nm および 797nm）のレーザー光を交互照射し、各波長の音圧分布を用いて切断指再接着術後の患者の 3 次元の血管像を撮影した。2 つのレーザー光を用いることで患側と健常側との酸素飽和度の比較を行った。対象は切断指再接着を行った 3 患者・4 指とした。

【結果】被検者は全例男性で、年齢は 81 歳、80 歳、37 歳であった。術後経過期間はそれぞれ 2 年、8 年、6 ヶ月であった。再接着部位は 2 例が母指基節部であり、1 例は示指基節部・中指末節部であった。サーモグラフィでは再接着指で温度低下がみられた。光超音波イメージングでは、3 指で吻合した指動脈の開存が観察可能であった。吻合動脈は末梢の distal palmar arch から分岐する血管まで描出可能であった。高齢者の 2 例では健側ではみられなかった吻合部遠位部の一部でコイル状の変形がみられた。1 例の再接着指では描出される末梢血管の酸素飽和度が健側との比較において低くなる傾向が見られた。

【考察】

近年、切断指再接着や遊離皮弁手術におけるマイクロサージャリーでは口径 1.0 mm 以下の血管が対象となってきた。光超音波イメージングでは、これまで屍体解剖でしか観察できなかった血管の微細な解剖を、生体において 3 次元の高解像度で観察が可能となった。特に手指を中心としたマイクロサージャリーの領域において、術前後の血管解剖評価や新規皮弁手術の開発に光超音波イメージングの画像解析が役立つことが期待される。

一般演題 (口演) | 一般演題 10 (レーザー)

J20

Scaffold としての特性を用いたヒアルロン酸注入療法

青井 則之 (あおい のりゆき)

宮益坂クリニック

ヒアルロン酸フィラーは顔面のしわ治療用に発売されておよそ 30 年が経過する。当初は眉間、法令線などの表在性のしわの改善に使われ、持続期間も半年から 1 年程度とされていた。ところが 2010 年に入った頃から顔面の陥凹部分のボリューム改善や鼻、顎、頬、輪郭といった顔面の形態やパーツの改善など組織増大に使われるようになった。その場合、ヒアルロン酸フィラーは皮下や骨膜上に bolus に注入され、しばしば 1 年以上の長期にわたりボリューム改善が持続することがわかってきた。2018 年には注入されたヒアルロン酸の生体内動態が報告され、顔面用の粒子サイズのヒアルロン酸を用いた場合、皮下に注入されたヒアルロン酸内には周囲に存在する線維芽細胞や脂肪細胞が遊走して、自家組織とヒアルロン酸の複合体が形成され、長期持続に関与している可能性が指摘されている。これは注入されたヒアルロン酸が周囲の組織を構成する細胞の Scaffold として作用していることを意味している。さらに、自家組織と複合体になったヒアルロン酸は注入直後の状態より動きにくくなっていると考えられる。ヒアルロン酸は 1 回の治療で局所に大量に注入しても狙った部分に必要なボリュームを出すことができず、むしろ周囲に流れてしまい、局所の組織増大につながらないことは臨床でよく経験することである。そこで、一回あたりは周囲に流れない程度の注入量で行い、一度複合体ができた上に再度注入することによってより局所の組織増大が得られるのではないかと考え、当院では無理のない量を複数回に分割して注入する方法で良好な結果が得られている。いくつかの実例を挙げて、結果を報告する。ヒアルロン酸はフィラーとしての性質に加え、Scaffold としての作用があることがわかってきた。この効果を積極的に利用することで顔面をより立体的に仕上げることができるのではないかと考える。

一般演題 (口演) | 一般演題 8 (AI ほか)

J21

持続灌流併用局所陰圧閉鎖療法併用における担体として用いた人工真皮内の micrograft の組織学的評価

安藤 優希 (あんどう ゆうき)¹、伊藤 里沙子¹、吉沢 明成²、江郷 隼一郎²、馬場 香子¹、武田 啓²¹ 北里大学メディカルセンター 形成外科² 北里大学 形成外科・美容外科

【目的】Micrograft (MG) は、採取した組織を細断して移植する治療法であり、低侵襲で行える。2022 年に我々は、MG と局所陰圧閉鎖療法を併用した症例において、担体中に移植組織片が保持され、創傷治癒を促進する可能性を報告した。我々は、MG と持続灌流併用局所陰圧閉鎖療法 (Negative Pressure Wound Therapy instillation and dwell:NPWTi-d) の併用でも移植組織片が保持されるかに疑問を持ち、組織学的に検討した。類似の報告は認められず、若干の知見を得たので報告する。

【方法】82 歳女性の下腿難治性皮膚潰瘍に対し、RIGENERA システム®で作製した MG を、人工真皮を担体として移植した。移植前より施行していた NPWTi-d

を術直後より再開した。人工真皮の一部を手術当日、術後 3 日目、7 日目に採取し、HE 染色および keratin AE1/3、FactorⅧの免疫組織学染色にて観察した。

【結果】手術日の検体には、HE 染色・免疫染色とも人工真皮のコラーゲン層内に組織片と思われる構造が認められた。術後 3 日目には、HE 染色にてコラーゲン層内に赤血球とリンパ球・組織球、線維芽細胞が、免疫組織学染色にて keratin AE1/3 陽性の細胞が散見された。術後 7 日目の検体には、HE 染色でより多い細胞と好中球を認め、keratinAE1/3 および FactorⅧに陽性な細胞も認めた。

【考察】HE 染色の結果より、NPWTi-d を併用しても MG の組織片は担体内に保持されることが確認できた。免疫組織染色の結果より、線維芽細胞および新生血管が、担体内に誘導される可能性が示唆された。これらは、以前の我々の報告と同様であった。担体の人工真皮は組織再生の足場にもなり、また NPWTi-d の創傷治癒促進作用は広く認識されている。これらを併用した自験例では MG 独自の効果を判断することは難しい。しかしながら、自験例で担体の中に組織片が保持されることが確認できたため、MG と NPWTi-d の併用は可能であり、MG の治療効果も期待できることが示唆された。一方、MG と NPWT を併用した以前の報告より保持される組織片は少ない印象があり、治療条件には検討の余地があると考えられた。

一般演題 (口演) | 最優秀一般演題セッション

J22

臍帯・臍帯血由来材料による組織形成能の検討－15 年間の総括－

馬場 香子 (ばば きょうこ)^{1,2}、山崎 安晴²、杉本 佳香²、森山 和の²、杉本 孝之²、熊澤 憲一²、
曾根 由美子²、武田 啓²

¹ 北里大学メディカルセンター 形成外科

² 北里大学 医学部 形成外科・美容外科

【目的】我々は外科的侵襲の軽減を目指し、臍帯・臍帯血由来材料による組織形成能の検討を行っている。2021 年に本学会で過去 10 年間の経緯を発表した。本発表では 15 年間の研究を総括し発表する。

【方法】出生時に得た臍帯より explant 法で臍帯由来間葉系細胞 (UC-MSCs) を得た。臍帯血は採取直後に遠心分離を行い、臍帯血由来多血小板血漿 (UCB-PRP) と臍帯血由来乏血小板血漿 (UCB-PPP) に分離した。凍結保存は LaboBanker[®] を用いて -80°C で行った。以下を検討した。

- 1) UC-MSCs と骨髄由来間葉系細胞 (BM-MSCs) との骨形成における細胞動態の相違
- 2) 臍帯血由来フィブリン網 (UCB-FN) を足場として用いた UC-MSCs の骨形成能
- 3) 凍結保存後 UCB-PRP 中の成長因子: PDGF-BB・TGF- β 1・VEGF の測定と細胞活性
- 4) 凍結保存後 UC-MSCs の細胞活性と腫瘍化のリスク
- 5) 共培養での骨芽細胞・軟骨細胞・神経系細胞への UC-MSCs の分化能
- 6) 凍結保存後臍帯組織の検討

【結果】

- 1) UC-MSCs と BM-MSCs には骨形成において細胞動態に相違があり、UC-MSCs は骨形成がより困難であった。
- 2) UC-MSCs は UCB-FN を足場とし骨形成能を有した。
- 3) 凍結保存後 UCB-PRP 中の各成長因子は凍結前より高値であり、細胞活性を有した。
- 4) 凍結保存後 UC-MSCs の細胞活性は維持され、腫瘍化のリスクは低かった。
- 5) 共培養で UC-MSCs は骨芽細胞・軟骨細胞・神経系細胞へ分化した。
- 6) 凍結保存後臍帯組織断面および凍結保存後臍帯組織から得た細胞に CD34・CD73 が発現していた。

【考察】

自家組織由来再生医療材料には独自の利点がある。臍帯・臍帯血は出生時に無侵襲で一定量の組織を採取でき、-80°C で数年後の使用時まで凍結保存が可能であると考えられた。共培養は UC-MSCs の組織再生に有用である可能性が示唆され、比較的容易な手技で組織の再生が期待できた。UCB-PRP は組織再生に有用である可能性が示唆された。本研究より、臍帯・臍帯血は自家再生医療材料として有用であると考えられた。

一般演題 (口演) | 一般演題 6 (血管・リンパ管)

J23

電圧印加型冷蔵庫を用いたラット血管の非凍結保存による組織保存期間の延長効果

畔 熱行 (くろ あつゆき)¹、櫻井 裕章¹、長間 多恵¹、岡浦 廉¹、松浪 周平²、覚道 奈津子³、
日原 正勝³、松岡 祐貴³¹ 関西医科大学総合医療センター 形成外科² 関西医科大学総合医療センター 救急医学科³ 関西医科大学 形成外科

【目的】

切断四肢再接着や組織移植時の組織保存は、低温にすることで代謝が下がり、組織保存の期間を延長させている、しかし氷点下になると組織が凍結し細胞内の水分が凝結、細胞の膨化、細胞膜破壊により細胞死してしまう、そのため特別な機器や凍結保護剤を用いて温度を下けているが、これらを用いず、電圧印加型冷蔵庫を用いた短期間の組織保存の延長効果の検討を目的とする。

【方法】

電圧印加型冷蔵庫は、庫内で電圧を印加することにより分子を振動させ、細胞内の水分を凝結させないまま氷点下まで低温化し、凍結しない保存庫として開発された機器である。庫内に入れるだけでよく、簡便に過冷却状態となり、特別なプログラムや凍結保護剤などを使用せずに氷点下非凍結保存ができる。この過冷却保存技術の保存効果を、ラットの動脈グラフトモデルを用いて検証した。

【結果】

保存したラット大動脈の組織細胞の生存率を Cell Counting Kit-8 を用いて検討した。4℃での保存に比べ、過冷却保存の方が高かった。保存したラット大腿動脈の血管内皮を、光学顕微鏡ならびに、透過型電子顕微鏡を用いて観察を行った。長期間保存により血管内皮の剥離、内皮細胞の膨化が起こるが 4℃での保存に比べ、過冷却保存の方が長期間組織の構造が保たれていた。保存したラット大腿動脈を同系統のラットに移植を行い、開存率を検討した。過冷却保存した動脈は全例開存を認めたが、通常保存した動脈は血栓形成をきたしたものがあり、4℃での保存に比べ、過冷却保存の方が良好であった。

【考察】

電圧印加型冷蔵庫を用いた-2℃,1000V の条件下での過冷却保存は、従来の 4℃保存より大幅に改善され、保存期間の延長や移植後の予後の改善が期待される。

一般演題 (口演) | 一般演題 9 (再生医療)

J24

日本の社会における再生医療に関する意識調査

森山 和の (もりやま かずの)¹、馬場 香子^{2,3}、杉本 佳香³、熊澤 憲一³、杉本 孝之³、
加藤 由起子³、山崎 安晴³、武田 啓³

¹ 北里大学北里研究所病院 形成・美容外科

² 北里大学メディカルセンター

³ 北里大学医学部 形成外科・美容外科学

【目的】近年、再生医療は注目を浴び発展してきた。一方、一般社会には、再生医療が十分かつ正確に認識されていないとの疑念をもつ情報も散見される。本研究は一般社会における再生医療に関する意識調査を行い、我々と社会における認識の相違を理解し、再生医療の適切な提供と普及に寄与することを目的とした。

【方法】株式会社クロス・マーケティングに委託し、WEB アンケートで調査した。対象は 20 歳以上とし、職業を医療・生命科学研究関係者とそれ以外に分けた。それ以外のグループは年代 (20 歳毎 3 グループ)・性別・子供の有無とし、各 50 人を設定した。設問は、再生医療の認知・再生医療への関心と受容・再生医療への危惧・再生医療材料について、の項目を設定した。各設問の詳細は発表で提示する。

【結果】650 名の回答を回収した。再生医療の認知度は、名称は医療・生命科学研究関係者で約 85% 以上、その他で約 73%、内容は医療・生命科学研究関係者で約 42%、その他で約 7% であった。性別・職業・年齢・子供の有無で認知に差があった。再生医療への関心は、いわゆる美容医療より疾患・外傷に関する治療に対して高かった。再生医療への危惧は、安全性が最多で、次いで費用であった。再生医療材料は自家組織由来の希望が最多であった。治療選択への影響は専門家の意見が最多であった。

【考察】医療・生命科学研究関係者とその他の職種では再生医療の認知に差があり、啓蒙活動の必要性が示唆された。また、再生医療の内容まで認知している医療・生命科学研究関係者は半数以下と予想より低く、一般の社会への認知度をあげるには医療従事者への啓蒙活動も必要であると示唆された。真に良い治療を受けるには、患者が十分に治療を理解し、医療者と患者側双方が共通認識を持たなければならない。本研究結果より両者の認識の相違を把握することが、適切な再生医療の普及に必要であると考えられた。

一般演題 (口演) | 一般演題 5 (皮弁・マイクロサージャリー)

J25

ハンズフリー吸引管～助手なしの血管吻合もこれでスムーズに～

十九浦 礼子 (つくうら れいこ)


国立国際医療研究センター病院

【目的】血管吻合部への滲出液の流れ込みは、特に助手なしで吻合を行う場合、その処理の為に吻合を止めなければならず、流れが止まるため悩みの種である。今回、ハンズフリーで滲出液を吸引できる吸引管を開発したので紹介する。

【方法】2024 年 10 月～5 月に、血管柄付き遊離皮弁移植術の、内胸動静脈をレシピエント血管とした 9 例 (乳房再建 8 例、遊離空腸再建 1 例) において、ハンズフリー吸引管を用いて顕微鏡下に血管吻合をおこなった。

【結果】9 例中 9 例で滲出液の持続吸引をハンズフリーで行うことができ、吻合の流れを止めることなく邪魔せず、吻合を容易に行うことができた。吸引管使用による合併症 (血管のダメージや針糸の吸引事故など) は生じなかった。

【考察】血管吻合中の吻合部への滲出液の貯留を自動で処理してくれるハンズフリー吸引管は、術者を邪魔せず、血管吻合術をより容易にしてくれるツールとして有効である可能性が示唆された。助手がいる場合も、助手の手が吸引作業に取られないため有益と考えられた。固定性がまだ十分とはいえないため、それを強化する必要があると考えている。



一般演題 (口演) | 一般演題 10 (レーザー)

J26

AI を使用した鼻形成術 ～CT 画像より鼻軟骨の位置を特定する～

前田 珠未 (まえだ たまみ)、福田 慶三

ヴェリテクリニック

【目的】

当院では鼻形成術を行う際、術前に患者とベクトラを用いて仕上がりのシミュレーションを行い、手術の精度と結果の再現性を高めるため、テンプレートを使用している。テンプレート作成にはベクトラシミュレーションに加え、事前に頭部 CT 画像を撮影し、その両方から術前後の変化だけでなく、術中の移植軟骨の位置や、オーダーメイドプロテーゼ等のテンプレートのデザインも行っている。その際、鼻軟骨の位置が重要となるが、CT 画像では軟骨の位置が明瞭に描出されないため、今回は人工知能技術を利用して軟骨の位置の同定を試みた。

【方法】

従来、当院では外側鼻軟骨の位置を CT 画像の修正が可能なアプリケーションを使用し、およその位置をトレースし、軟骨の位置を可視化していた。しかし、実際の位置と一致していないこともあった。そこで、術中にトレースした軟骨の位置が実際の位置と合致しているかを検証し、合致していたものを抽出し、トレース後の CT 画像として人工知能に学習させ、ニューラルネットワークモデルを最適化した。

【結果】

CT 画像からトレースした軟骨の位置が実際と合致した症例は現在 28 例あり、その CT 画像を用いてニューラルネットワークが外側鼻軟骨の位置を自動的に特定できるようになった。これにより、軟骨位置のトレースを訓練されたスタッフが行う労力を軽減し、人の経験に基づくトレースの不安定性を安定化し、手術の精度を向上させることができた。

【考察】

鼻整形においてテンプレートを使用した手術は、正確な設計図があることで術者による結果のブレを最小限にし、良好な結果を得ることができる。そのためには正確なテンプレートが必要であり、正確な軟骨の位置や皮膚の厚みの検討が重要である。今後、実臨床で人工知能による軟骨の特定位置が実際と合致しているかを確認し、その結果を人工知能にフィードバックすることでさらに最適化していく予定である。

一般演題 (口演) | 一般演題 2 (皮膚創傷治療 1)

J27

光超音波イメージングを用いたケロイド血管新生の解析

牧野 愛子 (まきの あいこ)、齊藤 晋、高谷 亜矢子、津下 到、澤良木 詠一、森本 尚樹

京都大学大学院医学研究科形成外科学

【目的】ケロイドと血管新生の関連が報告されているが、その詳細は明らかではない。本研究の目的は、光超音波イメージングを用いてケロイド新生血管を描出することおよび、ケロイドの活動性との関係を明らかにすることである。

【方法】2022 年 12 月から 2023 年 12 月まで前向き観察研究を実施した。対象は京大病院形成外科でトリアムシノロン局所注射を受ける体幹および四肢の成人ケロイド患者とした。Luxonus 社の 3 次元光超音波イメージング機器を用いて 2 波長 (756nm および 797nm) のレーザー光を交互照射し、酸素飽和度の異なる血管を区別して描出した。比較のため、超音波診断装置を用いてドップラー画像を 3 次元撮影した。ケロイドを含む 4cm×6cm の関心領域をスキャンし、同サイズの健常領域も対照としてスキャンした。検査タイミングは治療前、治療後 1 か月、3 か月、6 か月に設定した。写真およびケロイドスケールを用いて活動性を評価した。専用ビューアーを用いて 3 次元画像を再構築し、ケロイドから離れた同一の血管を基準として酸素飽和度の標準化を行い、異なる時点での画像データを比較可能とした。ケロイド活動性と血管分布、酸素飽和度の経時的変化、病変部と対照領域との血管構造の違い、ケロイド新生血管の三次元構造について画像解析を行った。

【結果】5 患者 6 病変 (平均年齢 40 歳、男 4 名女 1 名) が本研究に含まれた。内 1 名は 6 か月時の撮影は辞退したが、残りは計 4 回の撮影を完了した。ケロイド表面を走行する血管と、活動性の高い部位に周囲から集簇する細血管が 3 次元で描出された。活動性の低下に伴う血管の減少と、活動性の増悪に伴う血管の増加が認められた。集簇血管の酸素飽和度は、ケロイドの活動性と関係していた。

【考察】ケロイドの保存的治療の効果や再発を予測する無侵襲の画像診断ツールとして、光超音波イメージングが利用できる可能性がある。

一般演題 (口演) | 一般演題 8 (AI ほか)

J28

マウス後肢リンパ浮腫の新たな評価法としての 3D スキャナーの潜在力

徐 東經 (そう とんぎょん)¹、伊藤 梨里¹、石川 耕資¹、三浦 隆洋¹、山本 有平¹、小野寺 康仁²、伊藤 陽一³、前田 拓¹

¹ 北海道大学大学院医学研究院 機能再生医学分野 形成外科学教室

² 北海道大学医理工学院グローバルセンター

³ 北海道大学医学研究院医学院社会医学分野医学統計学教室

【目的】マウスはコストや操作の簡便さ、分子生物学的評価ツールの多様性の面からリンパ浮腫モデルで広く用いられてきた。マウスにおけるリンパ浮腫の評価法はキャリパーや絹糸などを用いたツールから浮力の原理を用いた容積法、放射線科学的な方法まであらゆる方法が報告され、実際の研究に用いられてきた。既存法は観察者の手技に左右されると指摘され、放射線学的な評価はコストや被爆の問題が考えられる。今回、我々は3D スキャナーをマウス後肢リンパ浮腫モデルに用い、その有効性を確認することができたので報告する。

【方法】観察者3人がマウス後肢リンパ浮腫の評価を行った。既存に報告されたキャリパーによる足部厚の測定、絹糸を用いた後肢周径の測定、3D スキャンを各3回ずつ行った。測定後はマイクロCT を用いて放射線学的な評価を行った。放射線学的な評価により測定した数値を真値とみなし、各観察者により行われた測定値を比較した。既存に報告された方法とスキャナーによる方法間の信頼性、精度、測定時間を比較した。

【結果】3D スキャナーによる測定は信頼性が高く、誤差も少なかった。測定時間はキャリパーによる足部厚評価が最も短かった。熟練効果は特に観察されなかった。

【考察】3D スキャナーは臨床では3D スキャナーが乳房、顔面の形態の評価において広く用いられており、リンパ浮腫の評価にも用いられるようになってきた。小動物でも3D スキャナーを用いることで、より信頼性が高く、有用にリンパ浮腫評価ツールを開発した。

一般演題 (口演) | 一般演題 6 (血管・リンパ管)

J29

活性化大網を用いたリンパ浮腫治療における大網皮弁の分子生物学的側面に対する研究

徐 東經 (そう とんぎょん)、伊藤 梨里、石川 耕資、三浦 隆洋、舟山 恵美、山本 有平、前田 拓

北海道大学大学院医学研究院 機能再生医学分野 形成外科学教室

【目的】2次性リンパ浮腫は悪性腫瘍の治療や転移の予防として施行されるリンパ節郭清などで生じる。抹消リンパが破綻することにより軟部組織の易感染性や癌の移転異性が問題に上がってくる。また、循環機能不全が生じた四肢は患者の身体や精神面で苦痛の原因となる。臨床では様々な治療が行われているが、リンパ組織としての大網の機能が注目され、大網皮弁もその治療の一つとして用いられている。一方、大網は菌や異物に触れると活性化することが知られており、活性化した大網やその培養上清が様々な再生医療の材料として使われている。我々は、大網の有するリンパ浮腫治療への分子生物学的側面に関する研究を行ったので報告する。

【方法】8週齢、雄の C57BL6 マウスにポリデキストラン粒子を腹腔内投与し大網を活性化させ、1週間後大網を採取し器官培養を行った。8週齢、雄の C57BL6 マウスの後肢にシリコンプリントを用いたリンパ浮腫モデルを作成し培養上清を局所投与した。リンパ浮腫評価として、後肢周径の評価、病理組織学的評価を行った。

【結果】活性化大網の培養上清を投与した群でリンパ浮腫のピークが押さえられ、改善も早かった。病理組織学的評価では、活性化大網の培養上清を投与した群で皮膚厚が有意に薄かった。

【考察】大網は主に脂肪により構成され、まだらにミルキースポットという細胞成分が密集している領域を有する。大網は異物に触れることで活性化され、幹細胞や白血球などの細胞成分が増加することが知られており、これらの細胞が様々な成長因子やサイトカインを放出する。これらの性質から、活性化大網は再生医療の有用な材料として研究されている。活性化大網の培養上清はリンパ管新生に作用する成長因子も多量の放出していることが示唆された。今後、リンパ浮腫治療における大網の分子生物学的側面に関して考察できた。

一般演題 (口演) | 最優秀一般演題セッション

J30

培養軟骨の移植後骨化抑制法の確立と RNA シークエンス解析によるメカニズム解明

太田 智之 (おおた ともゆき)^{1,2}、北口 陽平^{1,2}、高尾 知佳²、岩井 良輔³、山田 大祐²、
藤澤 佑樹²、大曾根 達則²、宝田 剛志²

¹ 岡山大学学術研究院医歯薬学域 (医学系) 形成再建外科学分野

² 岡山大学学術研究院医歯薬学域 (医学系) 組織機能修復学分野

³ 岡山理科大学フロンティア理工学研究所

【目的】耳介や外鼻の形成に際しては自家軟骨移植が一般的な治療法であるが、軟骨採取部の侵襲や採取量の限界といった問題が存在する。これに代わる移植素材の開発として、軟骨再生医療領域では様々な培養軟骨の開発が進められてきたが、生体移植後の安定性の確保は重要な課題である。今回、我々は当施設で開発したスキャフォールドフリー iPS 細胞由来培養軟骨に関して、移植後の組織変化を解析した結果を報告する。

【方法】iPS 細胞を段階的に分化誘導することで肢芽間葉系細胞様に分化させ、これを拡大培養して得られる軟骨前駆細胞を細胞源とした。これらの細胞を独自の細胞自己凝集化法を用いて三次元化し、軟骨分化誘導を行うことで培養軟骨を形成した。この培養軟骨を免疫不全マウスに皮下移植し、移植後の組織変化を解析した。

【結果】移植した iPS 細胞由来培養軟骨は吸収されることなく維持されたが、数か月経過後に組織内に骨化が見られた。培養軟骨を移植前に低糖濃度の培地で培養することで、骨化を抑制できることが判明した。骨化条件と非骨化条件の移植前サンプルをシングルセル RNA シークエンス解析した結果、非骨化群では骨化関連遺伝子陽性細胞が減少していた。

【考察】移植を目指した培養軟骨の開発において、移植後の組織安定性は重大な課題である。特に骨化は重要なトピックであり、そのメカニズムを理解することは同分野において大きな意義を持つ。本研究では、低糖濃度の培地で培養することで、骨化関連遺伝子陽性細胞が減少し、骨化を抑制できることが示された。これは、成熟軟骨細胞と骨形成細胞における糖の要求性の違いに起因しているものと考えられる。今回の成果は、培養軟骨の骨化メカニズム解明とその解決の一助になると考える。

一般演題 (口演) | 一般演題 1 (腫瘍・移植ほか)

J31

ガイドラインが推奨するマージン以上で切除したにも関わらず再発した悪性黒色腫の 3 例

古賀 一史 (こが かずふみ)、藤岡 正樹、藤原 洸平、西園 馨子、日吉 尚

独立行政法人国立病院機構長崎医療センター

【目的】悪性黒色腫(Malignant Melanoma:以下、MM)の予後は原発巣の厚さ(Tumour Thickness:以下、TT)と相関するとされ、ガイドラインでは TT を基準に切除マージンが設定されている。MM は臨床所見と病理所見より表在拡大型、末端黒子型、悪性黒子型、結節型の 4 病型に分類される。研究対象の大半を占める白人は表在拡大型・結節型が多く、日本人を含むアジア人に多い末端黒子型に関しては十分な検証がされていない。特に、末端黒子型の中でも爪部 MM は側方マージン研究には全く含まれておらず、深部マージンの適切性について検証した前向き研究も存在しない。そのため、本邦患者での切除マージンの検討が必要である。

【方法】2003 年 4 月 1 日から 2023 年 3 月 31 日の間に当科で切除を施行した MM14 例を検討した。

【結果】14 例中 3 例に局所再発またはリンパ節転移を認めた。3 症例とも末端黒子型で、初療時のセンチネルリンパ節生検(sentinel lymph node biopsy: SLNB)は陰性であった。いずれもガイドラインで推奨される最大マージンよりも大きく切除されていたが、1 例は局所再発し、2 例はリンパ節転移を認めた。

【考察】再発した 3 例中、2 例は局所再発ではなくリンパ節転移であり、かつ、SLNB は陰性であったことから、仮に切除マージンをより大きくしたとしても、リンパ節転移の予防には寄与しない可能性が示唆された。また、今回再発した 3 症例はいずれも末端黒子型であり、ガイドラインに十分反映されている病型とは異なるため、病型毎に適切なマージンが異なる可能性についても検討を要すると考えられた。より適切なマージン設定を行うためには、日本人の症例に関する検討を積み重ねていく必要がある。

一般演題 (口演) | 一般演題 3 (皮膚創傷治療 2)

J34

慢性創傷洗浄にふさわしい石鹼はなにか

黒田 友集 (くろだ ともちか)¹、池田 憲一¹、中村 雅彦²、宮寺 志保²¹ 富山県立中央病院 形成外科² 富山県立中央病院 検査科

【目的】

慢性創傷は critical colonization がその一因となっている。慢性創傷を早く治癒へ導く方法として様々な治療が提唱されているが、まず行われるべきは創の洗浄である。

当院において、創部洗浄の際に看護師が「せっけん」として用意する洗浄剤はベータール F®であることがほぼ全例であった。一方で、ベータール F®での洗浄ではボディソープに代表される石鹼に比べ、洗い落とおせているバイオフィルムを主体とする「ぬめり」が乏しいと感じた。このため、ベータール F®とボディソープ、他の石鹼の洗浄力 (除菌力) を比較した。

【方法】

それぞれの試料 (石鹼液: ベータール F®・アルボース弱酸性泡ハンドソープ®・ボディソープ・シャボネットモイスト®, コントロール: 生理食塩水・10%ポビドンヨード液) 1ml に Mcfarland 0.25 の菌液 (*Escherichia coli*, *Staphylococcus aureus*, *Enterococcus faecalis*) を 10 μ l ずつ接種し、ボルテックスにて攪拌後 30 秒静置したもの 10 μ l を血液寒天培地へ白金耳で塗布し培養する。1 日後、2 日後の細菌コロニーを目視にて確認し、試料の殺菌力を評価した。

【結果】

ベータール F®, アルボース弱酸性泡ハンドソープ®は生理食塩水と比較して違いは無かった。ボディソープはコロニー形成が弱く、ある程度の効果を示した。シャボネットモイスト®は *Escherichia coli* に著効し、その効力はポビドンヨードとほぼ遜色が無かった。

【考察】

ベータール F®は肌に優しい洗浄剤として販売されており、健常皮膚においては泡をふき取るだけでも洗浄効果が期待できるとされている。また、弱酸性であることから褥瘡といった正常皮膚のバリア層が弱い場合でも使用が推奨されている。しかし、今回の実験では細菌を洗浄にて殺菌する効果は乏しかった (こすり洗いは考慮していない)。これは組成が弱酸性にあることに起因していると思われる、適切な環境下で創傷を洗浄する場合には、アルカリ性ボディソープの使用が優れているのではないかと考えられた。

一般演題 (口演) | 一般演題 4 (皮膚創傷治療 3)

J35

ケロイドの痒みに着目した組織学的解析および Substance P 遺伝子発現解析

松添 晴加 (まつぞえ はるか)^{1,2,3}、池田 実香²、豊島 公栄^{3,4}、内藤 素子²、川端 智也²、片岡 和哉²、森本 尚樹¹、辻 孝^{3,4}¹ 京都大学大学院 医学研究科 形成外科学² 神戸市立医療センター中央市民病院 形成外科³ 理化学研究所 生命機能科学研究センター⁴ 株式会社オーガンテック

【目的】ケロイドは、審美的な観点のみならず制御困難な痒みにより、患者の QOL を著しく低下させる。ケロイドにおける痒みのメカニズムに関する多くの先行研究が報告されているものの、治療コンセンサスの形成に至っていない。前回、ケロイドの痒みと神経線維の分布について報告したが、今回ケロイド発症部位における痒みの違いに着目して、組織学的な比較解析と Substance P(SP)の遺伝子発現を解析したので報告する。

【方法】難治性の痒みを主訴とする前胸部ケロイド 6 例と、痒みの訴えがない耳ケロイド 6 例を対象とし、3 例の腹部正常皮膚をコントロールとした。4%PFA で固定した組織標本より 5 μ m のパラフィン切片を作製し、HE 染色組織像を比較した。次に、痒みが見られた前胸部ケロイドについて、同様に固定した組織標本より 10 μ m の凍結切片を作製して、ISH により SP 遺伝子発現解析を行った。

【結果】正常皮膚と比較して、前胸部および耳ケロイドとも、表皮の肥厚、真皮中層の炎症性細胞の浸潤とケロイドコラーゲン形成といったケロイド特有の特徴が見られた。前胸部と耳ケロイドの組織学的比較では、表皮突起の分布、皮膚付属器の破壊像、および神経終末端の分布などで差異が認められた。また、前胸部ケロイド組織の ISH 解析により、ケロイドコラーゲンの周囲に SP 遺伝子の発現が観察された。

【考察】前胸部と耳ケロイドの組織学的比較により差異が明確となり、これが両者の症状や治療抵抗性の違いと相関する可能性が示唆された。さらに、前胸部ケロイド組織の周辺部における SP 遺伝子の発現も明らかとした。SP は神経原性炎症に関与し神経線維に存在する受容体に直接作用する痒み誘因物質であり、アトピー性皮膚炎において治療ターゲットとなっている。本研究の成果より、痒みを主訴とするケロイドに対して SP をターゲットとする治療法の可能性が示唆された。

一般演題 (口演) | 一般演題 3 (皮膚創傷治療 2)

J36

シングルセル解析を用いたケロイドの形成機構の解明を目指して

中村 遼太 (なかむら りょうた)¹、尾上 貴紀¹、石井 愛¹、大谷 直矢¹、黒田 一也¹、松崎 伸介²、久保 盾貴¹¹ 大阪大学医学部 形成外科² 森ノ宮医療大学 医療技術学部

ケロイドは致命的な疾患ではなく、軽視される傾向にあるが、その患者の実情としては、醜形や疼痛等の症状に苦しんでいる人が少なくない。しかしながらケロイドの形成機構は未だ不明な点が多く、治療法は限定的である。その理由として、その形成機構には様々な細胞が関与しながら、さらには細胞増殖因子や炎症性サイトカイン、機械的刺激などの様々な外的因子が複雑に関与することが考えられる。それらの要因の一つ一つを丹念に解析していくことは非常に重要なことであるが、治療に結びつけていくまでには莫大な時間と人員を要することが予想される。そこでわれわれは、先端技術であるシングルセル解析を駆使し、ケロイドに発現する因子を網羅的に解析することで、ケロイド形成に最も重要な細胞のサブタイプや因子を発見するなどにより、その形成機構を明らかにすることを目指している。

シングルセル解析を行うには、まず雑多な細胞が混在する組織から、それらを単一細胞として調製する必要がある。また、十分な解析を行うためには、適切な生細胞率と総細胞数が必要となる。

今回われわれは、研究への参加の同意を得た患者から採取したケロイド組織を、キットを用いて単一細胞化し、さらにセルソーターを用いることによって、適切な細胞条件を満たす細胞集団を調製した。その後シングルセル解析に提出し、問題なく解析を完了することができた。その調製方法について検討する。

一般演題 (口演) | 一般演題 5 (皮弁・マイクロサージャリー)

J38

新鮮凍結死体を用いた腓骨動脈皮弁後のドナー一部閉創に有用な穿通枝動脈皮弁の検討

美波 直岐 (みなみ なおき)¹、清水 隆昌¹、長谷川 英雄¹、仲西 康顕¹、河村 健二²、面川 庄平³、田中 康仁¹¹ 奈良県立医科大学整形外科科学講座² 玉井進記念四肢外傷センター³ 手の外科学講座

【目的】OCFFF(osteocutaneous fibula free flap)ドナー部の一期縫縮が困難な場合の合併症率は、植皮術で 33%、有茎皮弁で 12%と皮弁を用いた被覆の優位性が示されている。ヒラメ筋穿通枝や腓骨動脈近位穿通枝を利用したプロペラ皮弁が報告されているが、腓骨動脈穿通枝皮弁以外の解剖学的裏付けは乏しい。今回、新鮮凍結死体を用いた OCFFF 後のドナー部位閉創に有用な穿通枝の特徴を調査した。

【方法】新鮮凍結死体 6 体 11 肢を使用し、下腿後面に存在する 1.0mm 以上の穿通枝を調査した。穿通枝の本数、穿通枝位置 (深筋膜を貫く位置) [X、Y] とその血管径 (外径)、血管の由来を調査した。穿通枝位置は腓骨長軸を X 軸、腓骨長軸と直交する軸を Y 軸とし、腓骨遠位端を原点として測定を行った。

【結果】検体は男性 4 体、女性 2 体で、平均年齢は 78.3(70-92)歳であった。一肢につき穿通枝は平均 4.4 本、内訳はヒラメ筋穿通枝平均 0.9 本 (0-1 本) と腓腹筋穿通枝平均 3.5 本 (2-6 本) であった。ヒラメ筋穿通枝位置は [平均 18.6 (10.3-25.4) cm、4.3 (2.9-6.0) cm]、血管径は平均 1.4 (1.0-1.8) mm、腓骨動脈由来が 6 本、後脛骨動脈が 1 本、共通幹が 3 本であった。

腓腹筋穿通枝位置は [平均 25.9 (17.3-33.0) cm、9.3 (4.2-16.1) cm]、血管径は平均 1.6 (1.0-3.5) mm、すべて腓腹動脈由来であった。

【考察】OCFFF で一期縫縮が困難となるのは、下腿遠位 1/3 である場合が多い。ヒラメ筋穿通枝は下腿中央の腓骨やや後方に存在し、プロペラ皮弁で下腿近位の余剰軟部組織を遠位へ移動可能な有用な穿通枝である。稀に存在しない場合があり、注意が必要である。腓腹動脈穿通枝は、穿通枝位置が下腿近位の腓骨より離れた位置に存在するため、適応は限られる。

一般演題 (口演) | 一般演題 2 (皮膚創傷治癒 1)

J39

脱分化脂肪細胞 (DFAT) 含浸真空凍結乾燥人工真皮の in vitro 評価

宮下 采子 (みやした あやこ)^{1,2}、檜村 勉¹、竹内 ともみ^{1,2}、風間 智彦²、松本 太郎²、
副島 一孝¹

¹ 日本大学医学部 形成外科

² 日本大学医学部 機能形態学系 細胞再生・移植医学分野

【目的】

脱分化脂肪細胞(DFAT)を人工真皮コラーゲンスポンジ内に減圧環境下で浸透後、真空凍結乾燥処理して DFAT 含浸真空凍結乾燥人工真皮を作成した。今回は、減圧条件と生理活性物質の放出能について in vitro での検討を行った。

【方法】

SD 系ラットの腹腔内脂肪を天井培養して DFAT を調整した。自作簡易減圧浸透装置を用いて人工真皮 (Pelnac、コラーゲン使用人工真皮単層タイプ、GUNZE)に DFAT 懸濁液 $1.0 \times 10^6/\text{cm}^2$ を散布し減圧処理を施した。1.至適減圧条件の検討：-10cmHg 群、-70cmHg 群を作成しそれぞれ2分間減圧処理を施した。HE 染色標本で人工真皮断面の上層と下層の単位面積当たりの細胞数を測定し比較した。2.生理活性物質放出能の検討：1.で得られた条件で作成した DFAT 含浸人工真皮を新鮮群、凍結保存群、真空凍結乾燥群(各群 n=8)に分けて、走査電子顕微鏡による組織検索、生理活性物質(VEGF, bFGF)の放出能を定量した。真空凍結乾燥には真空凍結乾燥機(CHList, ALPHA1-4/2-4LSCplus, KUBOTA 社製)を用いた。

【結果】

- 1.-70cmHg 群で人工真皮全層に細胞含浸が得られた。
- 2.凍結保存群、真空凍結乾燥群いずれにおいても人工真皮コラーゲンスポンジ間隙に DFAT 細胞が認められた。
- 3.生理活性物質の定量結果は bFGF は真空凍結乾燥群で他の群より優位に多く、VEGF は有意差はなかったが、真空凍結乾燥群で多い傾向が伺われた。

【考察】

真空凍結乾燥により DFAT は凝集していたが細胞形態を維持していることが観察された。そして、湿潤環境に戻すと生理活性物質の放出が認められた。それは、新鮮状態や凍結保存状態よりも多量であり、細胞が壊れることにより一度に放出させるものと推測された。

一般演題 (口演) | 一般演題 2 (皮膚創傷治療 1)

J40

バトロキシビンがマウス熱傷に与える影響の解析

今井 利郎 (いまいとしろう)¹、佐藤 佑樹²、丹野 寛大²、松永 拓¹、伊師 森葉¹、庄司 未樹¹、
今井 啓道¹、菅野 恵美²¹ 東北大学大学院医学系研究科形成外科学分野² 東北大学大学院医学系研究科看護技術開発学分野

【目的】熱傷治療においては、Jackson が提唱した凝固帯、うっ血帯、充血帯の分類がよく知られており、血栓や血管収縮が起きているうっ血帯から、不可逆的な壊死である凝固帯への移行を最小限に抑えることが熱傷治療の目標の一つである。様々な発展を遂げた今日の熱傷治療においても、デブリードマン等の外科的処置や全身管理を適切に行うことが唯一の対抗策であり、現在もなお熱傷治療の課題であり続けている。蛇毒由来のトロンビン様酵素であるバトロキシビン(BTX)は抗血栓作用、血管新生促進作用が報告されており、すでに慢性動脈閉塞症や突発性難聴で用いられている薬剤であるが、熱傷に与える影響は解明されていない。本研究では、マウス熱傷モデルに BTX を投与し、熱傷に与える影響を解析した。

【方法】麻酔下に C57BL/6 マウスの背部皮膚に 4 個の熱傷創を作成した。熱傷創は 90°C に熱した直径 5 mm の円形の電気ゴテ (白光株式会社製) を 10 秒間接触させることで作成した。創作成日に生理食塩水または BTX 30 バトロキシビンユニット/kg を腹腔内に投与し、以後は摘出前日まで連日腹腔内投与を行ない、経時的 (1、3、5、7、10、14 日目) に熱傷創を摘出した。上皮間距離、肉芽組織面積、CD31 陽性細胞数を病理学的に、増殖因子やサイトカイン産生を ELISA 法で解析した。本研究は東北大学動物実験委員会の承認を得て実施した。

【結果】対照群と比較し、BTX 投与群において 5、7 日目の上皮間距離が有意に低く、10 日目も低下傾向を示した。血管新生の指標である CD31 陽性細胞数は 5、7、10 日目に有意に高かった。また、塩基性線維芽細胞増殖因子(bFGF)産生量が 3 日目で増加傾向を示し、残りの全てのタイムポイントで有意な上昇を認めた。

【考察】本研究により、BTX 投与は上皮化と血管新生を促進することが示された。bFGF がこれらの促進に関わっている可能性について、今後さらなる研究が必要である。

一般演題 (口演) | 一般演題 6 (血管・リンパ管)

J41

開創型ハンズフリー吸引管～重症リンパ浮腫での LVA をもっと手軽に～

十九浦 礼子 (つくうら れいこ)

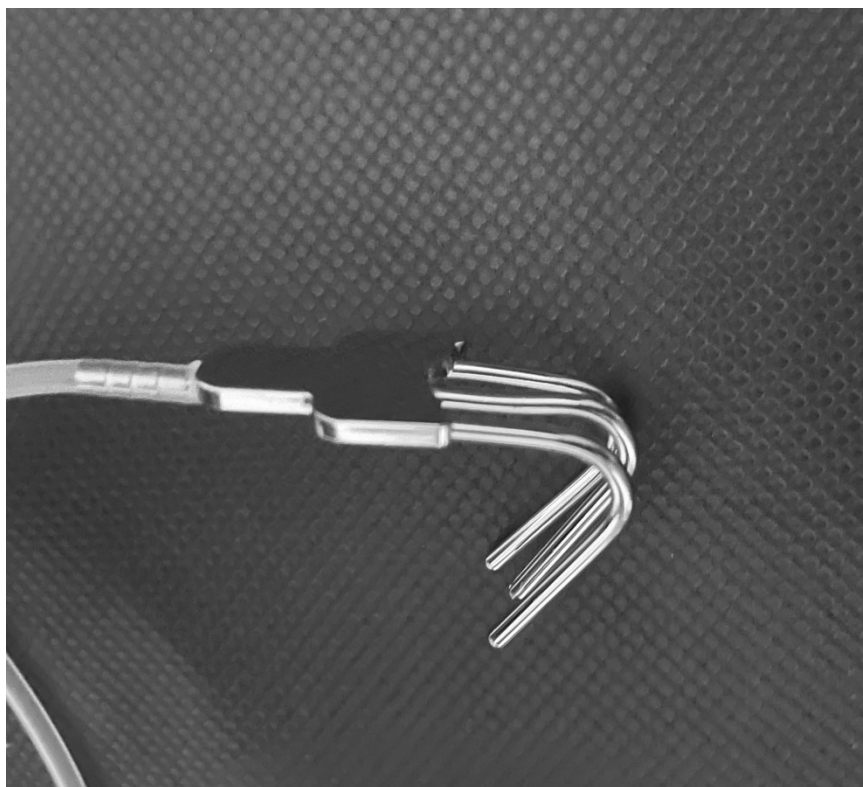
国立国際医療研究センター病院

【目的】重症リンパ浮腫におけるリンパ管吻合中のリンパ液の貯留はリンパ管吻合を困難にする。リンパ液の漏出をハンズフリーで吸引できる開創型の吸引管を開発したので紹介する。

【方法】2024 年 2～4 月に、重症二次性リンパ浮腫 3 例 対しリンパ管吻合術中に開創型吸引管を用いてリンパ液の持続吸引をおこなった。症例の重症度は全例で ISL stage3 であり、うち 2 例は Dermal Backflow stage IV, 1 例は ICG 非適応のため dermal backflow stage 不明であった。

【結果】3 例中 3 例でリンパ液の持続吸引をハンズフリーで行うことができ、吻合を邪魔せず、吻合を容易に行うことができた。吸引管使用による明らかな合併症は生じなかった。

【考察】重症リンパ浮腫におけるリンパ管吻合術中に溢れ出てくるリンパ液を処理するリンパ吸引管はハンズフリーで使用することができ、術者を邪魔せず、リンパ管吻合術をより容易にしてくれるツールとして有効である可能性が示唆された。リンパ管吻合は術野が小さいのでそれに合うようサイズの縮小の検討性が示唆された。



一般演題 (口演) | 一般演題 1 (腫瘍・移植ほか)

J42

脂肪組織由来幹細胞 (ADSC) バンク設立を目指して

原 幸司 (はら こうじ)¹、今井 啓道^{1,2}、伊藤 貴子^{2,3}、沖田 ひとみ^{2,3}、佐々木 麻美^{2,3}、
後藤 昌史^{2,3}¹ 東北大学病院 形成外科² 東北大学病院 移植再生医学分野³ 東北大学病院 移植再生医療センター

間葉系幹細胞である脂肪組織由来幹細胞 (ADSC: adipose tissue-derived stem cell) は損傷や炎症を起こした組織へと集積し、障害を抑える物質を放出することで組織の回復機能を持つことが知られている。これらの特性を生かし、これまで治療が困難であった疾患の治療や新規療法に関する研究が行われている。しかし、ADSC の供給の多くは海外に依存しているため、国内において安全かつ安定的に供給することを目指し、ADSC バンク設立の前身として、ADSC 供給プロジェクトを東北大学病院移植再生医療センターで立ち上げた。

移植再生医療センターとは、再生医療の推進を目的に掲げ、2008 年から稼働している細胞プロセッシングセンター(以下 CPC)を前身とし、2022 年 4 月に東北大学病院内に設立された。本センターは、臓器を一から構築するのではなく、特殊な能力を持つ細胞を移植することで、損傷した組織の修復や肩代わりをする再生医療を行うことを特色としており、移植医療と再生医療の融合を目的としている。すでに臍島バンクが稼働しており、臍臓から臍島を分離・保管し、糖尿病患者へ臍島移植を実施済みである。

ADSC 供給プロジェクト立ち上げに際し、院内の倫理審査に加えて、独自に外部の有識者委員会を設立し、科学的かつ倫理的妥当性を高める工夫を行った。定期的に有識者委員会に図り、現状に即した内容になっている評価頂いている点は特記に値する。

脂肪組織採取の手順としては、手術前にプロジェクトの構成員 (医師) が本プロジェクトの協力機関である美容形成クリニックなどへ出向き、患者 (研究協力者) から直接同意を取得し、本来であれば廃棄されてしまう脂肪組織を回収する。回収後速やかに CPC で ADSC を分離・増殖し、研究機関・医療機関や製薬・細胞製造関連企業へ提供する流れとなっている。

ADSC 供給プロジェクトについて、現状の報告および今後の課題について述べる。

一般演題 (口演) | 一般演題 2 (皮膚創傷治癒 1)

J43

皮膚伸展刺激および RhoA 経路の阻害による線維芽細胞のアポトーシス動態と増殖能の検討

石井 愛 (いしい めぐみ)¹、黒田 一也¹、松崎 伸介²、中村 遼太¹、大谷 直矢¹、久保 盾貴¹¹ 大阪大学附属病院 形成外科² 森ノ宮医療大学 医療技術学部 診療放射線学科

【目的】ケロイド、肥厚性瘢痕の形成に関わる要素として、皮膚線維芽細胞の筋線維芽細胞への分化およびアポトーシス動態の変化が考えられる。また、好発部位からは皮膚への機械的伸展刺激も重要な因子であると考えられる。先行研究において、皮膚線維芽細胞は、機械的伸展刺激を加えることで、細胞骨格制御因子である RhoA 経路を介して、筋線維芽細胞への分化が誘導されることが報告されているが、アポトーシス動態や増殖能に注目した報告は未だ少ない。今回、RhoA 経路を阻害した皮膚線維芽細胞に対して機械的伸展刺激を加えることによるアポトーシス動態および細胞増殖能の変化を検討した。

【方法】正常皮膚線維芽細胞(NFB)に対して、アデノ随伴ウイルスベクターを用いて、正常皮膚線維芽細胞に不活性型 LIMK2 の遺伝子導入を行い、RhoA 経路を阻害した(NFB LIMK2 negative)。NFB および NFB LIMK2 negative に対して、伸展刺激装置を用いて伸展刺激を加え、免疫染色によりアポトーシス動態の変化を調べた。また、同様に、BrdU 染色により、増殖能の変化を観察した。

【結果】免疫染色の結果、NFB および NFB LIMK2 negative において、伸展刺激を加えた群では、加えなかった群と比較して、アポトーシスが抑制されていた。また、NFB LIMK2 negative 群は、NFB 群と比較して、アポトーシスが促進されていた。BrdU 染色の結果、NFB LIMK2 negative 群は、NFB 群と比較して、増殖能が抑制されていた。

【考察】正常皮膚線維芽細胞では、伸展刺激によりアポトーシスの抑制を認めた。LIMK2 の制御を介して RhoA 経路を阻害すると、アポトーシスが誘導され、また、増殖能が抑制されることが示された。これらの結果が異常瘢痕形成機序の解明に役立つ可能性がある。

一般演題 (口演) | 一般演題 4 (皮膚創傷治癒 3)

J44

in vivo におけるミトコンドリア移植の創傷治癒効果について

高清水 一慶 (たかしみず いっけい)、杠 俊介

信州大学医学部 形成再建外科学教室

【目的】細胞のエネルギー産生の要であるミトコンドリア (以下、Mt) の機能異常は、細胞レベルだけでなく、組織、個体にまでその影響が及ぶことがわかっている。これまで我々は、in vitro の創傷治癒モデルにおいて健常者由来の細胞から単離した Mt を移植することにより、創傷が早期に閉鎖すること、またその際に細胞増殖関連遺伝子の発現が増加することを報告してきた。今回、in vivo の創傷治癒モデルにおいて同様の実験を行ったので報告する。

【方法】C57BL/6 の背部を除毛後、皮膚生検パンチを用いて全層皮膚欠損創を作成し、創収縮予防装具を縫合固定することで創傷治癒モデルを作製した。移植するための健常な Mt は、別個体の肝臓を脱血後、細切して更にホモジナイザーで潰し、遠心法で Mt 分画を分離することで単離した。単離した Mt を創傷治癒モデルの創に投与し、創傷被覆材でドレッシングした後、経時的に創の上皮化および収縮率を観察した。

【結果】この創傷治癒モデルでは、創は 1 週間程度で上皮化し、10 日経過すると創のサイズが始めに作製した創の大きさの 2 割ほどに縮小し、4 週間でほとんど創がわからなくなった。Mt 移植群はコントロール群と比較して、上皮化と創の縮小する時期が濃度依存的に早くなる傾向があった。

【考察】Mt 移植は、in vitro で得られた結果と同様に、創を早く縮小させる可能性が示唆された。

一般演題 (口演) | 最優秀一般演題セッション

J45

アカハライモリの熱傷モデルを用いた“傷上皮”と炎症の関係

高清水 一慶 (たかしみず いっけい)、杠 俊介

信州大学医学部 形成再建外科学教室

【目的】驚異的な再生力を有するアカハライモリは、皮膚を欠損しても瘢痕形成することなく完全再生することがわかっている。その創傷治癒過程の初期に、ヒトとは異なる“傷上皮”と呼ばれる上皮が傷全面を被覆することで、炎症が早期に鎮静化されることをこれまでの研究から見出した。炎症の早期鎮静化が完全再生に関与している可能性を追求するため、皮膚欠損創より炎症が強く生じるⅢ度熱傷創のモデルを開発、報告してきた。このモデルにおいて炎症の程度がどのように変化していくのかを“傷上皮”に注目しつつ検証を行った。

【方法】アカハライモリのⅢ度熱傷モデルを用いて、経時的に創を観察しつつ、創部組織の一部を採取し、total RNA を抽出後、cDNA を合成した。また残りの組織を用いてパラフィンブロックによる切片標本も同時に作製した。炎症・抗炎症マーカーである IL-1 β 、IL-6、iNOS、IFN γ 、TGF β 、IL-10、Arg1 について PCR を行い、遺伝子発現量の変動を解析した。得られた切片標本を用いて染色を行い、組織学的評価を行った。

【結果】熱傷モデルでは、数日で焼痂は融解し潰瘍形成をしつつ、受傷後 7 日前後で周囲から伸展した“傷上皮”で創面は被覆された。遺伝子発現解析から、その被覆した時期を境に炎症マーカーは減少し、抗炎症マーカーは増大する傾向が見られた。組織では“傷上皮”が創面を被覆したのちも、組織内では血管からの血球細胞の漏出や線維性組織や筋組織の分解が認められた。

【考察】皮膚欠損創よりも炎症がより強く生じる熱傷創を用いたモデルにおいても、“傷上皮”が創面を被覆することで早期に炎症が鎮静化する傾向があることが示唆される。

一般演題 (口演) | 一般演題 5 (皮弁・マイクロサージャリー)

J46

マウスリンパ節付随免疫皮弁モデルを用いた新しいがん免疫療法に向けて

羽賀 義剛 (はが よしたか)^{1,2}、前田 千恵³、芦澤 忠³、兼松 明里³、荒木 淳²、安永 能周²、秋山 靖人³、森 弘樹¹

¹ 東京医科歯科大学 形成・再建外科学分野

² 静岡県立静岡がんセンター 再建・形成外科

³ 静岡県立静岡がんセンター 免疫治療研究部

【目的】これまで、樹状細胞 (DC) による抗がん効果を付加した組織皮弁を用いて、腫瘍の局所再発の抑制とワクチン効果による遠隔転移の抑制を行うという、ラットの免疫皮弁治療モデルに関する報告がなされている。今回我々は、より臨床応用に近づける為に、マウスに対するリンパ節付随免疫皮弁治療モデルを用いて、マウス乳がんの転移治療効果などに関する検証を行った。

【方法】近交系 BALB/cA マウスの大腿骨から骨髓を採取し、DC の培養を行った。DC はマウストリプルネガティブ乳がん細胞株 EMT6 (以下 EMT6) の腫瘍細胞溶解液 (Lysate) により成熟化したもの (Lysate 処理群)、Lysate を用いずに成熟化したもの (Lysate 非処理群)、2 種類を準備した。続いて、マウスの鼠径部にリンパ節付随有茎皮弁をデザインし、EMT6 を皮弁近傍に移植した。腫瘍増生が認められた後、培養した DC を蛍光標識して皮弁内に投与し、移植した腫瘍と皮弁内リンパ節に関して、フローサイトメトリー (以下 FACS) を用いて評価した。

【結果】DC 投与 24 時間後に移植腫瘍および皮弁内リンパ節を確認したところ、リンパ節内では Lysate 処理した DC が確認できた。一方、腫瘍内においては、蛍光標識した DC は Lysate 処理・非処理群のいずれでも確認できなかった。

【考察】Lysate 処理した DC を投与することで、リンパ節を介した抗腫瘍効果の可能性が推察された。一方で、腫瘍内には蛍光標識した DC が確認できなかったが、腫瘍内には死細胞なども多く含まれ、目的とする DC を FACS の際に拾い切れていない可能性も考えられる。その為、病理学的なアプローチなども含め、他方面からの腫瘍抑制効果の評価も検討している。また、今回の結果は腫瘍構築モデルに対する抗腫瘍効果の可能性である為、今後は腫瘍抑制効果に関しても検討すべく、追加実験を行う予定である。

一般演題 (口演) | 一般演題 1 (腫瘍・移植ほか)

J47

酸化セルロース貼付剤 (吸収性局所止血剤) を用いた、安全で確実なリンパ節摘出術の検討

石原 良平 (いしはら りょうへい)^{1,2}、廣瀬 太郎¹

¹ 群馬県立がんセンター

² 帝京大学医学部付属病院

目的

病理診断を目的としたリンパ節摘出術では、もっとも腫大しているリンパ節を狙って、小指の先程度以上の組織量を、またリンパ節皮質ーリンパ濾胞まで含む、十分な深さでのリンパ節組織の摘出が求められる。

特に、悪性リンパ腫を疑う場合、可能な限り早急にリンパ節摘出をおこなうことが迅速な治療開始につながり、予後改善の助けとなる。次いで、合併症 (出血、感染、リンパ漏等) も少ない術式が求められる。

今回、酸化セルロース貼付剤を用いたリンパ節部分摘出法を含む複数の術式について検討を加えた。

方法

対象は 2011 年 1 月から 2024 年 5 月までおこなったリンパ節摘出術 349 症例である。

摘出するリンパ節は、皮下に容易に触知できるもので、腹腔内や大血管・神経に接するものは避けた。

術式はリンパ節の丸ごと摘出、または部分摘出である。部分摘出では紡錘状切り出し、突出部切り出し、サイコロ状切り出し+酸化セルロースを切り出し面に充填する方法で、それぞれの術式を比較した。

結果

紡錘状切り出し、また突出部切り出しでは、出血、リンパ漏が生じた症例があったが、サイコロ状切り出し+酸化セルロース貼付剤では同様の合併症は発生しなかった。

また紡錘状切り出しの 1 例では、充分深い新鮮なリンパ節組織を摘出することができず、2 度目の摘出術で診断に至った。

考察

全身麻酔に比べ人員的、時間的制約の少ない局所麻酔下でリンパ節摘出をおこなうことは早期の診断につながる。

診断率に関しては、紡錘状切り出しのみ複数回の摘出術が必要となった症例があった。

サイズが大きく、癒着が強い等の理由で対象のリンパ節を丸ごと摘出を行うことが困難な場合もサイコロ状に切り出し+酸化セルロース貼付剤使用により、合併症が少なくかつ診断率の高いリンパ節摘出をおこなうことができた。

一般演題 (口演) Online | 一般演題 9 (再生医療)

J48

骨分化誘導時におけるエクソソーム量の変化について、ヒト腸骨由来間葉系細胞由来の培養上清での検討

杉本 佳香 (すぎもと よしか)¹、杉本 孝之¹、馬場 香子^{1,2}、熊澤 憲一¹、森山 和の³、
加藤 由起子¹、山崎 安晴¹、武田 啓¹

¹ 北里大学医学部 形成外科・美容外科学

² 北里大学メディカルセンター 形成外科

³ 北里大学北里研究所病院 形成・美容外科

【はじめに】

本研究は骨組織再生のために自己の凍結保存したヒト骨由来間葉系細胞 (hBT-MSCs) を用いた臨床応用である。われわれは骨形成にかかわる新たな因子として、hBT-MSCs から分泌されるエクソソーム (Exo) に注目し、骨分化誘導能などの検討を行ってきた。今回、骨分化誘導時における Exo の量の変化について報告する。

【目的】

hBT-MSCs の培養上清から Exo を精製し、蛍光標識抗 Exo マーカー抗体で標識された Exo を用いて経時的な量の変化を調べた。

【方法】

hBT-MSCs を維持培地と骨分化誘導培地に播種し、3 週間培養した。精製した Exo は Western blot (WB) およびフローサイトメトリー (fluorescence-activated cell sorting : FACS)、蛍光免疫染色を行い、定性・定量確認を行った。また骨形成能を確認するため Ca 定量/染色を行った。

【結果】

Exo の経時的定量で、CD9 陽性の Exo がほとんど存在しないことが WB 解析で確認された。FACS 解析においても CD9 のシグナルは弱く、WB の結果が再現された。FACS におけるヒストグラム解析では、維持培地に比べ骨誘導培地の方が強いシグナルを認め、特に CD63 陽性の Exo が高シグナルであり、経時的に比例関数様の増大傾向を認めた。また免疫蛍光染色での共焦点画像において、FACS と同様に CD63 陽性 Exo が多く認められ、CD9 陽性 Exo は殆ど確認できなかった。こちらも CD63, CD81 陽性 Exo は経時的に増大傾向を認めた。Ca 定量/染色において Exo 滴加群に Ca の産生がみられ、産生量としてはコントロール < Exo 添加群となった。

【考察】

維持培地と骨誘導培地で、Exo が存在する量も異なることから、Exo に内包される miRNA 等の変化と共に細胞から分泌される Exo の量も骨形成に関連していることが推定された。

一般演題 (口演) | 一般演題 3 (皮膚創傷治癒 2)

J49

PGA 不織布による組織修復促進の検討

末吉 遊 (すえよし ゆう)¹、磯貝 典孝²、楠原 廣久¹、中尾 仁美¹、富田 興一¹¹ 近畿大学 形成外科² 同志社大学 生命医科学部

【目的】 Polyglycolic acid(以下 PGA)不織布は生分解性で、肺・気管支・肝・消化管など脆弱な組織の縫合時に組織補強材として臨床で用いられている。しかし組織学的な変化や評価については解明されていない部分が多い。今回異なる繊維径の PGA 不織布をラットの皮下に埋植し、誘導されるマクロファージや I 型コラーゲンに着目し、組織修復の促進に寄与するか検討した。

【方法】 PGA シート (繊維径約 14.2 μm 、NEOVEIL[®]、GUNZE) と nano PGA シート (繊維径約 2.0 μm 、NEOVEIL nano[®]、GUNZE) の異なる繊維径の 2 種類の PGA を、ラット腹部皮下に埋植した。埋植 3 日目、1、2、3、4 週目に取り出し評価を行った。評価は、組織学的検査 (HE 染色、Masson-Trichrome 染色) で埋植組織の厚さの変化やコラーゲン線維の走行を、免疫組織学的検査 (α SMA、CD34、CD68、CD163、Type I collagen、MCP-1、TNF α 、TGF β 、IL-6) で遊走した細胞の種類や遊走時期の評価を行った。

【結果】 nano PGA シートは、早期に炎症細胞の遊走を認め、その後 CD68+マクロファージ、異物巨細胞を PGA 繊維の周囲に認めた。細径の血管新生とともに I 型コラーゲンの産生も早期から認めた。一方、PGA シートは、繊維の分解が遅く、炎症反応の遷延化、I 型コラーゲンの産生が遅延していた。

【考察】 nano PGA シートは、早期から M2 マクロファージ、I 型コラーゲンが早期から出現していることより、早期に組織修復が行われることを示唆した。nano PGA シートは細胞の足場としても非常に有用であり、再生医療において、移植細胞と移植床との接着材料として期待できる。

一般演題 (口演) | 一般演題 1 (腫瘍・移植ほか)

J50

局所的な乏毛・無毛モデルの開発

森脇 裕太 (もりわき ゆうた)、白石 真土、栗田 昌和、岡崎 睦

東京大学大学院医学系研究科 形成外科学分野

【目的】毛包再生能を検討するためのモデルとして、ヌードマウスやヘアレスマウスなど遺伝子変異を有するマウスや、手掌・足底など無毛部位が用いられるが、局所の細胞の賦活による毛包再生・新生能を評価するためには、生得の原因によらない局所的な乏毛、無毛を呈するモデルが望ましい。後天的な原因で局所的に乏毛・無毛を呈するモデルの開発を試みた。

【方法】正常な細胞を有する局所的な乏毛・無毛皮膚領域を作成する手術手技の最適化を目的として、細胞移植術、植皮術の有効性を検討した。GFP マウスをドナー、ヌードマウスをレシピエントとして、1) 初代培養ケラチノサイトのシリコンチャンバー内への移植、2) 全層植皮、3) 5/1000 インチ分層植皮、4) 10/1000 インチ分層植皮、を行い生着領域および局所の毛包付属器の状態を組織学的に解析した。

【結果】培養ケラチノサイト移植術では、術後 4 週の時点で潰瘍面の $56 \pm 11\%$ の上皮化した創面のうち移植した細胞の占める領域は $1.3 \pm 0.6\%$ まで収縮していた一方、植皮術においては移植組織の 90% 以上の面積で生着をえた。全層植皮・10/1000 インチ分層植皮では多量の発毛が見られ、組織学的評価では各群の組織切片において毛包数がそれぞれ平均 8 個/mm、14 個/mm であったのに対し、5/1000 インチ分層植皮ではほぼ発毛が見られず、組織学的に毛包数は 1 個/mm のみであった。

【考察】5/1000 インチ植皮術を行うことで、局所的な乏毛皮膚領域を広範囲に有するマウスモデルを安定して作成可能であった。遺伝的・部位特性的影響を受けず汎用性の高い本モデルは後天的な原因で乏毛を呈した動物モデルとして毛包再生能の検討に有用であると思われる。

一般演題 (口演) | 一般演題 7 (顔面骨・手の外科・乳房)

J51

人工物乳房再建におけるバイオフィルム解析 -textured type vs smooth type-

松永 拓 (まつなが ひろむ)¹、庄司 未樹¹、菅野 恵美²、今井 啓道¹¹ 東北大学医学系研究科 形成外科学分野² 東北大学医学系研究科 基礎・健康開発看護学講座

【目的】

人工物による乳房再建では、特にインプラント関連未分化大細胞型リンパ腫(BIA-ALCL)が問題となっている。原因として人工物表面のシリコン形状の関与が指摘されており、表面形状が macro textured type での発生が多いとの報告がある。当院ではシリコンに対する被膜周囲の集積細胞やサイトカイン産生量などの炎症反応の解析やバイオフィルムの検出を in vitro からヒト検体に至るまで網羅的に行ってきた。今回我々は、新たに開始となった smooth type Tissue Expander(TE)に対する被膜組織のヒト検体を採取し、バイオフィルム解析を行ったため、これまでの結果に加え文献的考察を含めて報告する。

【方法】

2018 年 5 月から 2023 年 12 月までにシリコンインプラント挿入術を施行し、被膜採取が可能であった症例を対象とした。検体は LIVE&DEAD 染色による生菌と Rhodamine ConA による多糖類の二重染色法を行い、共焦点レーザー走査顕微鏡にて生菌が多糖類中に存在する検体をバイオフィルム陽性検体とした。

【結果】

症例数は乳房再建患者 57 名、58 乳房であった。臨床的に感染徴候を認めた症例はなかった。textured type、smooth type はそれぞれ 46 乳房、12 乳房であり、31 乳房(67%)、3 乳房(25%)にバイオフィルムを認め、textured type でバイオフィルム検出率が有意に高い結果であった。

【考察】

BIA-ALCL や被膜拘縮は、過剰な免疫反応や炎症反応などの関与が指摘されているが、明確なメカニズムは解明されていない。今回、textured type で 67%と高いバイオフィルム検出率を認め、諸家の難治性潰瘍などにおけるバイオフィルム検出率とほぼ同等であった。これは、手術は無菌操作であり TE 留置期間も限定的であることから textured type に特徴的な結果であると考えられる。また、被膜の採取は部分的であり、より高い検出率となる可能性も考えられた。今後 smooth type および micro textured type の解析を重ねるとともに、バイオフィルム形成に関わる細菌叢や各被膜組織の病理学的、免疫学的な解析を進めていく予定である。

一般演題 (口演) | 一般演題 8 (AI ほか)

J53

間葉系幹細胞に対してセルネストが与える影響

浅倉 辰則 (あさくら たつのり)、松田 健

新潟大学大学院 医歯学総合研究科 形成外科学教室

【目的】

現在形成外科領域では脂肪組織由来幹細胞、骨髄由来間葉系幹細胞、血管内皮前駆細胞などを用いた再生医学の臨床研究が盛んである。しかし自己の組織を使った治療は時間とコストがかかり臨床応用へのハードルは高い。形成外科領域で扱う骨欠損部への治療が人工材料によって簡便に骨移植と同等の効果を得ることが出来れば、患者の負担を減らす画期的な治療法となり得る。私たちはコラーゲンなどの細胞接着性タンパク質に共通の細胞接着活性アミノ酸配列 RGD モチーフを集積したリコンビナントペプチド (RGD ペプチド: セルネスト (cellnest)、富士フィルム) に着目し、これまでにラットの頭蓋骨欠損部にセルネストの In vivo 移植実験を行い、その骨再生における有効性を本学会で発表してきた。今回私たちは間葉系幹細胞 (MSC) の培養系にセルネストを添加し、MSC の挙動に及ぼす影響を In vitro で解析した。

【方法】

細胞毒性試験 (MTT assay)、細胞接着試験 (cell adhesion assay)、細胞周期試験 (cell cycle assay)、骨分化マーカー解析を行った。いずれの実験も MSC を播種後、3 種類の濃度の異なるセルネストと共培養することでデータを得た。

【結果】

細胞毒性試験ではセルネストの MSC への毒性は認めなかった。細胞接着試験ではセルネストの濃度が上がるほど細胞接着を促進させた。細胞周期試験では G2 期の割合がセルネスト投与群でやや多かったが有意な差は認めなかった。RNA 解析ではセルネスト投与により骨形成マーカーである ALP 発現レベルの上昇を認めた。

【考察】

セルネストは MSC の骨芽細胞への分化を促進させる安全な足場材料であることが示唆された。

J54

Group A Streptococcus Necrotizing Soft Tissue Infection の早期は白血球が上昇しにくい

西條 優作 (さいじょう ゆうさく)、小野 真平、秋山 豪、小川 令

日本医科大学付属病院 形成外科

【目的】GAS-NSTI は早期に敗血症を呈し致死率が高く、治療には手術や全身管理、持続透析を要する。早期診断が大切であるが、発症早期では多くの症例が蜂窩織炎などと誤診され適切な治療介入が遅れる。本研究は GAS-NSTI の発症早期血液検査データを調べることで、早期診断のための血液検査データの特徴を明らかにするものである。

【方法】日本医科大学付属病院における 2010 年 1 月から 2024 年 3 月の間に GAS-NSTI と診断された治療を受けた患者を対象とした。患者を、軟部組織の疼痛、発赤、熱感、腫脹のいずれかを自覚してから 3 日以内に血液検査を受けた群 (group 1) と 4 日以降に受けた群 (Group 2) の 2 群に分け、WBC、CRP、Na、Cre、Hb、Glu、Plt、BUN、LRINEC スコア、qSOFA を比較した。

【結果】Group 1 は Group 2 と比較して、CRP は同等に高値 ($34.0 \pm 11.2 \text{ mg/dL}$) にも関わらず WBC は有意に低く、WBC の平均値は正常範囲内であった ($6.7 \pm 4.9 \times 10^3/\mu\text{l}$)。LRINEC スコアは Group 1 において 75% が 6 点以上となった。また qSOFA 陽性率は全体で 24% であった。

【考察】GAS-NSTI の症状初期には CRP が高値にも関わらず WBC が上昇しない傾向を認めた。また GAS による敗血症を、qSOFA を用いて疑うことは困難である。そのため軟部組織症状があり、血液検査で上記所見があれば GAS-NSTI を疑う必要がある。

一般演題 (口演) | 一般演題 7 (顔面骨・手の外科・乳房)

J55

アレイ小型デュロメータを用いた再建乳房の硬さ三次元マッピングシステム

古屋 香菜子 (ふるや かなこ)¹、辛川 領²、矢野 智之²、長谷川 雪憲³、荻野 秀一⁴、森本 尚樹⁵、荒船 龍彦⁶¹ 東京電機大学大学院² がん研有明病院³ 株式会社 レナートサイエンス⁴ 滋賀医科大学医学部付属病院⁵ 京都大学大学院医学研究科⁶ 東京電機大学

乳房再建の手法として、人工物や自家組織移植があるが、手術侵襲や術後の形態変化といった課題がある。そこで、新たな手法として、ポリ乳酸スキャフォールドを用いた人工脂肪による再建技術が提案されている。スキャフォールドは埋植後、脂肪細胞が流入してやがて脂肪組織と硬さ、組成が同一化するというメカニズムであるが、基礎的検討として実施された動物実験においてはその速度・条件にばらつきが確認されている。そこで臨床応用に向けて、患者の術後 QOL に強く影響する乳房の局所硬さを定量的に計測・評価可能なシステムの開発が急務である。以上より再建後の乳房の局所硬さ情報を多点三次元表示可能なシステムの開発を本研究の目的とした。システムは独自開発した小型デュロメータを多数配置した下着と、コンピュータ、センサ値を三次元マップに表示するソフトウェアから構成される。計測した硬さ情報から深度カメラを用いて計測した乳房の三次元形状データの表面に、硬さ分布図をテクスチャ画像として重畳する。まずセンサの妥当性評価のため、しこりが埋め込まれた乳がん触診モデルを用いて既存の生体組織硬度計と自作機器を計測、比較した。次に乳房硬さ計測の評価実験として、人工脂肪を埋植したミニブタを用い、開発したシステムの結果と形成外科専門医の触診結果を比較した。ミニブタを対象とした人工脂肪の硬さ評価の結果、定性的ではあるが、触診による医師の持つ感覚と導出した三次元硬さ分布図に大きな齟齬がないことを確認した。小型デュロメータを下着に多数配置することで、簡便に乳房の硬さ計測が可能であると考ええる。また、自作機器を用いて人工脂肪の硬さを計測可能であると考ええる。本システムを用い再建乳房の硬さ分布の定量的評価ができることが示唆された。

一般演題 (口演) | 一般演題 5 (皮弁・マイクロサージャリー)

J56

AR マイクロサージャリートレーニングシステムを用いた術者視線解析と熟練医暗黙知の抽出

坂田 洸崇 (さかた ひろたか)¹、辛川 領²、矢野 智之²、荒船 龍彦³¹ 東京電機大学大学院² がん研有明病院³ 東京電機大学

【目的】

マイクロサージャリー習得のため、初学者は継続的な血管吻合技術の訓練が重要である。我々はヘッドマウントディスプレイを用いた AR 型のマイクロサージャリートレーニングシステムの開発し、立体視と熟練医の細かい手技工程のシャドーイングを両立することで、従来の顕微鏡のみを用いたマイクロサージャリーのトレーニングに比べて、より効果的な技術習得を可能とした。一方で本システムを用いた解析から、熟練医のマイクロサージャリーの技術には未だ言語化されていない暗黙知が存在し、熟練医の手技のビデオ映像の視聴やトレースだけでは、各手技工程における根拠や理由の理解が十分ではないという課題も明らかになった。そこで本研究の目的は、AR トレーニングシステムに手術映像と操作者の視線記録機能を付与し、熟練医と初学者で血管吻合手技における注視箇所や速度の差を明らかにするマイクロサージャリー手技工程計測・解析システムの開発とした。

【方法】

VR ヘッドセットに備わる視線計測機能を用いて術者視線の時系列座標情報を取得し、血管吻合手技中の術者視野映像に視点を重畳する独自ソフトウェアを開発した。また視点座標の表示だけでなく、視線の累積によるヒートマップ導出機能を実装した。本システムを用いてまず熟練医の血管吻合手技の両眼視野映像と視線座標情報を記録し、血管吻合手技をさらに細かい手技工程へと分解して、どの手技操作において実際の行動着手・開始・終了と視線の移動の関係を解析した。

【結果】

次に初学者による血管吻合操作を、熟練医の分解された手技工程と比較することで、熟練医の暗黙知に該当する動画視聴による視線傾向と手技パターンの言語化を行った。

【考察】

熟練医の暗黙知の1つとして針操作時点よりも先を見越した視線移動や針先よりも血管への注視が多くの時間を占める可能性が示唆された。

一般演題 (口演) | 一般演題 7 (顔面骨・手の外科・乳房)

J57

先天性眼瞼下垂の筋膜移植術、筋膜の成長期を含めた経時的変化
～眼瞼・眉毛位置計測ソフトを用いて～

小柳 俊彰 (こやなぎ としあき)¹、板宮 朋基²、中野 亜希人²、大慈弥 裕之³、高木 誠司¹

¹ 福岡大学形成外科

² 神奈川歯科大学

³ 北里大学形成外科・美容外科

【目的】先天性眼瞼下垂に対する治療の 1 つに筋膜移植術がある。この治療において、移植された筋膜の経時的変化を正確に予測することは難しく、また成長期をまたいだ際の筋膜長の変化に関しても不明な点が多い。われわれは以前より臨床写真より簡便かつ精密に眼瞼及び眉毛位置を計測するソフトを開発、報告してきた。今回、本ソフトを応用し、術中、術後の筋膜長の経時的な変化を計測した。

【方法】当院で 2009 年～2022 年の間に先天性眼瞼下垂症に対し手術を行った 157 症例の内、①筋膜吊り上げ術を行った、②術中の角膜輪が確認できる写真が撮影されている、③術後 1 年以上の写真がある、上記 3 点の条件を満たした 14 症例に対し本ソフト (眼瞼・眉毛位置計測ソフト) で計測を行った。

【結果】本ソフトでは 1%、およそ 0.1 mm 単位での計測ができるため、筋膜の収縮率や術後の経時的変化、成長期をまたいだ際の変化に関して詳細な計測結果が得られた。

【結論】眼瞼・眉毛位置計測ソフトを使用することにより、先天性眼瞼下垂に対する筋膜移植術に関する詳細なデータを得ることができた。

一般演題 (口演) | 一般演題 6 (血管・リンパ管)

J58

ラット上腸間膜リンパ管を用いた人工リンパ管生体内挙動評価モデルの開発

辻本 悠貴 (つじもと ゆうき)^{1,2}、山中 浩気^{1,2}、馬原 淳²、齊藤 晋¹、山岡 哲二^{2,3}、森本 尚樹¹¹ 京都大学大学院医学研究科形成外科学² 国立循環器病研究センター研究所³ 公立小松大学保健医療学部臨床工学科

【目的】リンパ浮腫に対して、リンパ管閉塞部位を跨いで自家静脈や自家リンパ管などを interposition graft する術式は、lymphatic-venous anastomosis (LVA) と比較してより生理的な経路でリンパ管流路を再建できるが、ドナーが犠牲となるため普及には至っていない。我々は interposition graft に使用可能である内腔 0.5mm の人工リンパ管を開発中であるが、その有効性を評価する小動物実験モデルの報告はなかった。本研究の目的は、ラット上腸間膜リンパ管がリンパ管 interposition graft 実験モデルとして利用可能かを調べることである。

【方法】雄の SD ラット (548g±21 g) 10 匹を使用した。腹部横切開で開腹し、腸管を右側へ避け、盲腸周囲のリンパ節にパテントブルーを注射した。上腸間膜動脈と腹腔動脈の間に位置する上腸間膜リンパ管を同定し、その短軸径を計測した。人工リンパ管として長さ 4mm、内径 0.5mm のシリコンチューブを interposition graft として上腸間膜リンパ管に移植した。

【結果】上腸間膜リンパ管は色素法により速やかに同定でき、短軸径は $0.97 \pm 0.35\text{mm}$ であった。10 例中 7 例でシリコンチューブの移植が可能で、直後に開存性が確認できた。上・下腸間膜リンパ管が癒合した解剖学的破格や、上腸間膜リンパ管と上腸間膜動脈が癒着し剥離できないものは移植できなかった。

【考察】下肢や後腹膜に存在する径 0.3mm 未満のリンパ管を利用したラットの LVA モデルが報告されているが、これらのリンパ管は口径が細く分枝も多い。一方でラットの上腸間膜リンパ管は十分な径を持ち、解剖学的な位置も安定しており、人工リンパ管の再現性の高い開存性評価が可能と考えられる。

一般演題 (口演) | 一般演題 5 (皮弁・マイクロサージャリー)

J59

裸眼立体視を用いた乳房再建術前・術中支援システム

橋田 周治 (はしだ しゅうじ)¹、辛川 領²、矢野 智之²、荒船 龍彦³¹ 東京電機大学大学院² 公益財団法人がん研究会 有明病院³ 東京電機大学

乳房再建術前に穿通枝の位置や構造の把握や、穿通枝ごとに作成できる皮弁の最適なサイズや形状のプランニングは初学者には容易ではない。また三次元 CT 画像の立体形状把握用機器として Head mount display (HMD)を用いて術前データを 3D ホログラム化する製品があるが、毎回 HMD を装着するのは煩雑という課題がある。そこで本研究では、(1) 過去の手術データから皮弁組織内の穿通枝本数、その内移植手術に用いた穿通枝血管とその血管径、血流速度、採取した皮弁体積と、実際に移植された皮弁体積情報を学習データとして、患者の穿通枝血管径と血流速度から採取可能な皮弁サイズを導出する予測システムと(2) 予測した皮弁サイズを 3D データに生成し、患者 CT データへ重畳して裸眼立体視するシステムの開発を目的とした。裸眼立体視には空間再現モニタ ELF-SR2 (Sony) を用い、立体視用の患者データの表示ソフトウェアを独自に開発した。立体視用のデータは、患者の CT データから穿通枝、皮膚、脂肪組織を 3D オブジェクトとして選択的に表示可能とした。再建手術した患者の穿通枝の平均血管径 $\phi 4.2\text{mm}$ と平均血流速度 127mm/sec を基準データとし、実際に採取した皮弁形状を 3D 計測と重量計測を行い皮弁形状の基礎 3D データとした。血管径 \times 血流速度で求まる値を皮弁組織への供給可能血液量と想定し、この値を基準にして、再建に使用しなかった穿通枝 $\phi 3.8\text{mm}$ の血管径や流速 $147, 107 (\pm 20) \text{mm/sec}$ を変えると、供給可能血液量と比例して拡大縮小した皮弁 3D データを予測値として生成し、ボディ CT データに重畳表示する。生成した仮想皮弁組織の 3D データを形成外科専門医 2 名により評価を行い、妥当性の確認を行った。

一般演題 (e ポスター)

J60

リピッドバブルと超音波とを併用した in vivo インプラント型軟骨組織再生の試み

山門 希実 (やまかど のぞみ)、山岡 尚世、小室 裕造

帝京大学医学部 形成口腔顎顔面外科

【目的】

軟骨再生医療においては外傷や変形性関節症などが原因で起こる軟骨損傷に対する治療が行われている。これは患者由来の軟骨細胞を培養、増殖して作製した細胞塊を損傷部位に移植するものである。一方、形成外科における主要な軟骨疾患は口唇口蓋裂における鼻変形、小耳症における耳介変形などの形態異常であり、これらを改善するためには力学的強度を有し三次元形態をとることのできるインプラント型の再生軟骨を作製する必要がある。そこで我々は形状維持の方法として多孔体型足場素材を用いて、軟骨再生関連遺伝子である Sox9 をリピッドバブルと超音波を使用した新しい方法で軟骨前駆細胞に遺伝子導入し in vivo での軟骨組織再生を試みている。昨年の本学会では、得られた再生軟骨組織の遺伝子発現の検討について報告したが、今回、生化学的、組織学的に詳細なデータが得られたため報告する。

【方法】

ヒト膝由来軟骨前駆細胞 2.5×10^5 cells をスキャフォールドであるコラーゲンゲルと混和し多孔体コラーゲンスポンジに投与し三次元的に培養後、ヌードマウスの背部皮下に移植した。ここに新たに開発されたリピッドバブルと超音波を用いて 1 週間おきに Sox9 遺伝子を 500ng、2 μ g をそれぞれ導入し 1 か月後に検体を摘出し生化学的、組織学的に評価した。

【結果】

Sox9 遺伝子導入により生理的軟骨特性を持った再生軟骨が得られた。また導入する Sox9 の濃度が高いほど生理的軟骨の性状に近い再生軟骨組織が得られた。

【考察】

ハイドロゲルと多孔体スポンジを併用したハイブリッド型のコラーゲンスキャフォールドに、リピッドバブルと超音波を用いた遺伝子導入法を組み合わせることにより三次元形状を持った再生軟骨組織を得ることが出来た。この方法は比較的簡便かつ低侵襲であり生体内における軟骨組織再生治療の 1 つの手法として有用であることが示唆された。

一般演題 (口演) | 一般演題 5 (皮弁・マイクロサージャリー)

J61

鼻中隔における血行動態の観察とその臨床応用

上 敏明 (かみ としあき)

上敏明

【目的】 日常、臨床において、Trans columella incision の存在が端的に示されるように、鼻中隔の血流は軽視されがちであった。我々は鼻翼部や鼻尖部の組織欠損に対し、鼻中隔の血流を応用した皮弁を考案した。本報告では鼻中隔における血行を確認するため、ラットの鼻を使用した実験を行なった。実験の概要とともに、鼻中隔を皮弁の茎とした鼻中隔皮弁の応用例について述べたい。

【方法】ウイスター系ラット雄、生後9週を使用。フェノバルビタール 30mg を腹腔内投与し麻酔する。麻酔終了後、直ちに鼻部を中心に上口唇を含めた切片を採取する。鼻軟骨は含めない。直ちにサリチル酸メチルの溶液に沈め透明標本の作成を行なう。3 日目にサリチル酸メチルに浸したまま位走査顕微鏡により鼻中隔の血管を観察する。次に鼻中隔を矢状方向、水平方向に離断し、ホルマリン固定、HE 染色を行ない鏡検する。

【結果】 透明標本においては鼻柱基部より鼻尖部にかけて血管の存在が認められた。HE 染色の標本においては鼻中隔の長軸方向に豊富な血管が存在した。

【結論】 鼻中隔には豊富な血管が存在し、鼻尖部皮膚、皮下組織を栄養している事が推察された。

【臨床応用】

症例 1. 自傷行為により鼻翼欠損をきたした症例、当初は局所皮弁により修復したが目的を達せられず、2 回目の手術として鼻柱皮弁により鼻翼を形成した。

症例 2、顔面斜裂、口唇口蓋裂、生後 1 年目に口唇形成、斜裂部 Z 形成術を行なう。4 年後に鼻翼欠損に対し鼻中隔皮弁を応用した。

た。

【考察】

鼻中隔における血流は十分で、鼻尖部、鼻背部皮膚、皮下組織を栄養できることがラットを使用した実験により判明した。その臨床応用においても鼻柱皮弁は鼻翼再建に有用であることが推察される。

一般演題 (口演) | 一般演題 2 (皮膚創傷治療 1)

J62

空間トランスクリプトームによるケロイド病態解析

土佐 眞美子 (とさ まみこ)¹、阿部 芳憲²、多賀 麻里絵¹、小川 令¹

¹ 日本医科大学付属病院形成外科・再建外科・美容外科

² 日本医科大学研究部 共同研究施設分子解析研究室

【目的】ケロイドは慢性炎症を伴う線維性疾患であり、確立した動物モデルがないこともあり、その発症・維持機構は解明されていない点も多い。本研究では新たな視点からケロイド病態の解明と新規治療標的分子を明らかにする目的で、空間トランスクリプトーム解析を行った。

【方法】手術時に摘出したケロイド組織を用い、細胞の位置情報が保存された状態で遺伝子発現プロファイルを明らかにできる空間トランスクリプトーム解析 (Visium) を行って、ケロイド病態の解明と新たな治療標的候補分子の有無について検証した。

【結果】ケロイド組織における遺伝子発現データのクラスター解析により、異なる遺伝子発現プロファイルを示す複数のクラスターが特定された。ケロイド組織で活性化が報告されている TGF- β シグナル伝達経路活性化領域を取り巻くように、制御性 T 細胞や M2 マクロファージなど炎症反応に関与する細胞が多く含まれると考えられるクラスターが存在していた。さらに、他の炎症製疾患と似たクラスターも存在することが分かった。本研究からケロイド組織中にはまだ報告されていない、ケロイド治療法開発の新規候補分子が高発現されていることも見出した。

【考察】ケロイド組織内の各クラスターを構成する遺伝子群をもとに、GO (Gene Ontology) 解析を行って主制御遺伝子 (Master Regulator) が存在する可能性も示された。さらに新規候補分子の下流で発現変動する可能性がある遺伝子群も浮かび上がった。今後、主制御遺伝子を起点とした新たな治療標的候補分子の制御機構を解明することで、ケロイド治療法開発の基盤情報となる新しいケロイド発症・維持機構を提唱できる可能性がある。

一般演題 (口演) | 一般演題 6 (血管・リンパ管)

J63

乳児血管腫に対するプロプラノロール投与終了後に再増大を認めた症例の検討

藤井 奈穂 (ふじい なほ)、平山 美希、入潮 実季、打越 大登、谷本 華乃子、元村 尚嗣

大阪公立大学形成外科

【目的】乳児血管腫の治療法としては以前よりパルス色素レーザー照射が行われていたが、2016 年以降はプロプラノロール (以下、PPL) 内服が保険適用となり、機能部位にかかる場合や活動性が高い症例では PPL 内服療法が第一選択となっている。内服療法の終了時期は病変の腫脹が改善し、色調もおちついた時点で決定しているが、内服終了後に病変が再増大する症例も経験した。今回、PPL 内服療法内服終了後病変が再増大した症例について検討した。

【方法】当院で 2016 年以降に PPL 内服治療を行った症例のうち、内服終了後半年以上の経過が確認できた 42 例について、内服終了後に病変の再増大を認めた症例と、再増大を認めなかった症例について比較検討を行った。

【結果】41 例の内訳は、男児 14 例、女児 27 例であった。内服終了後、病変が再増大した症例は 41 例中 4 例 (9.8%) であった。内服開始月齢は平均 3.6 カ月、再増大群では平均 2.8 カ月、再増大を認めなかった群は平均 3.8 カ月であった ($p>0.05$)。内服期間は平均 10 カ月、再増大群では 11.8 ヶ月、再増大しなかった群は 9.9 カ月であった ($p>0.05$)。また、部位や血管腫のタイプ、出生時低体重についてなど患者背景についての比較も行ったが、2 群間に有意な差は認められなかった。

【考察】比較を行った症例数が少なかったため有意差は出なかったが、再増大した群のほうが内服開始年齢も早く、また内服期間も長い傾向にあった。再増大のリスクとしては「内服期間が短いため」ということではなく、もともとの血管腫の活動性が高く、早くから内服を開始し、長期服用が必要だった症例のほうが内服終了後に再増大する傾向にあることが示唆された。今後も症例を重ねて検討が必要と考える。

一般演題 (口演) | 一般演題 1 (腫瘍・移植ほか)

J65

脂肪移植のための染色体別エピジェネティクス修飾の可視化

窪田 吉孝 (くぼた よしたか)、小坂 健太郎、山路 佳久、秋田 新介、三川 信之

千葉大学形成外科

【はじめに】多面的作用に期待した脂肪移植治療において、材料となる皮下脂肪組織に含まれる細胞群の性質を解析することは、治療効果を最大限に発揮するために重要である。しかし、細胞機能の根幹であるエピジェネティクス解析は殆ど行われていない。染色体別解析が可能なプラットフォームを用いて皮下脂肪細胞のエピジェネティクス状態可視化を行った。

【方法】ヒト腹部皮下組織をコラゲナーゼ処理の後に遠心分離し、浮遊層から天井培養細胞(ccdPAs)、沈殿層から脂肪幹細胞(ASCs)を 7 週間培養した。エピジェネティクス修飾のうち、CpG メチル化 450K assay と H3K4me3 ChIP-seq assay を行った。Subio Platform®に bigWig データをインポートして解析した。

【結果】hg19 の Ref Seq Genes のうち、64.9%は H3K4me3 が集積している領域(= Interval)があり、H3K4me3 による転写調節を受けていることが分かった。また、Interval のうち 65.6%は転写開始地点(transcription start site, TSS)の前後 400 bp の領域に存在し、転写促進を行っていると考えられた。PPARG TSS 付近のピーク値は ASCs 16.2, ccdPAs 24.2、また、RUNX2 P1 TSS 付近のピーク値は ASCs 21.5 ccdPAs 33.1 であり細胞分化能の観察結果と一致していた。

H3K4me3 Interval のうち、72.6%は CpG Island と重なっていた。CpG Island から見ると、H3K4me3 と重なっているものは 51.8%だった。CpG Island の方が広範囲に分布しており、単独で、あるいは他のヒストン修飾とともに転写調節を行っているとされた。H3K4me3 と重なる CpG Island の殆どでメチル化率は極めて低いが、稀にメチル化率が高い場合があった。これは転写のアクセルとブレーキのように働くエピジェネティクス修飾が共存状態にあり興味深い。このような特殊な重なりは染色体の端、すなわちテロメア付近に集中して存在し、セントロメア付近には殆ど存在しなかった。また、第 1 染色体ではまばらにしか存在しなかったが、第 19 染色体では密に存在するなどの違いみられた。

【考察】皮下脂肪組織の細胞解析も大量データの時代が到来したが、得られた大量データから全体像をつかむことは必ずしも容易ではない。今回、染色体ごとのエピジェネティクス状態を把握することが出来た。これらの結果は脂肪移植の目的ごとの最適化の基盤となる。

一般演題 (口演) | 一般演題 7 (顔面骨・手の外科・乳房)

J66

手の外科領域における光超音波イメージングの実際と展望

深沢 克康 (ふかさわ かつやす)、亀倉 暁

関東労災病院 整形外科

【目的】

手の外科領域で扱う疾患は、指切断を含めた外傷からはじまり、先天性疾患や神経疾患による麻痺手、関節リウマチによる手変形、さらには腫瘍性病変や加齢変化に伴う変形性関節症に至るまで多岐にわたる。手の外科領域での血行動態の把握は、血管吻合による切断指再接着術の他にも医原性血管損傷を防ぐための手術術式の検討、リウマチ活動性の評価、腫瘍性病変の病態把握、変形性関節症の評価と治療法の検討に有用である。しかし微細な構造であるが故に、血管造影や MRI による詳細な評価は困難であり、現状では超音波装置による評価を行っているものの、検査者間による相違や獲得した画像情報は検査者以外には共有しにくい。

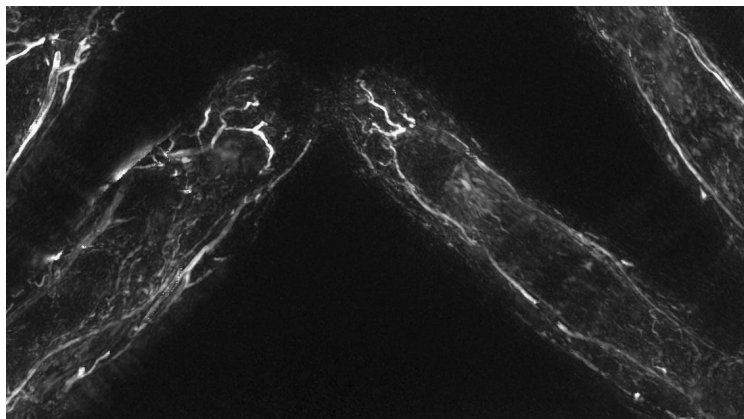
光超音波イメージングは 19 世紀に Alexander Graham Bell 博士が発見した光音響現象と呼ばれる現象を元に開発された技術であり、深さ数 cm の血管情報を詳細に観察することができる。また、756nm や 797nm など複数波長の光を用いることで酸素飽和度の指標を算出する特徴を持ち、高解像度で 3 次元的な血管像を非侵襲的に撮影可能である。

【方法】

今回 Luxonus 社製の光超音波イメージング装置を用いて、切断指の再接着術を行った症例の血行評価とともに手の外科領域で扱う疾患の血行評価を行った。

【結果と考察】

今までに乳がんやリンパ管、皮弁の評価として臨床応用を検討されたが、手の外科領域は散乱の影響の少ない、皮下組織の浅い構造物であるため、本装置は有用であった。動作による画像の不整に対して砂囊による固定やゲルシート、ウォーターバックでの音響マッチングを行った。本報告ではこれらの工夫とともに実際の応用例を提示しながら手の外科領域における展望に関して考察する。



一般演題 (口演) | 一般演題 7 (顔面骨・手の外科・乳房)

J68

VY 前進皮弁及び Minced skin graft を用いた簡便な乳輪乳頭形成術

牧野 潤 (まきの じゅん)、貴志 和生

慶應義塾大学医学部 形成外科

【目的】

乳輪乳頭切除を伴う乳房の再建後は、乳輪乳頭再建がその一連の再建の集大成といえる。種々の報告がなされている乳輪及び乳頭の再建方法のうち、局所皮弁及び植皮術による再建は最も一般的な手法のひとつである。ただし新たな瘢痕が生まれることや乳頭の平坦化などが課題であり、今回それらを克服しかつ簡便な手術手技について報告する。

【方法】

当科にて乳房再建後、手術による乳輪乳頭再建を希望した 2 例に対して、VY 前進皮弁による乳頭再建及び大腿内側による乳輪再建を施行した。症例はそれぞれインプラント及び腹直筋皮弁による乳房再建症例であった。対側の乳輪乳頭と対称となるようマーキングしたのち、VY 皮弁をデザインした。デザインした皮弁及び乳輪部分をあらかじめ脱上皮した。皮弁挙上時に大胸筋の厚みがあった症例については筋皮弁とした。皮弁挙上後ドナー部分を縫縮したのち、インドシアニングリーン(ICG)を用いて皮弁への血行を確認した。皮弁をロール状に固定し乳頭を形成し、その後大腿内側より植皮をおこなうことで乳輪を形成した。余った植皮片を細断し minced skin graft として皮弁に塗布し手術を終了した。

【結果】

術後皮弁血行及び植皮生着は良好で、術後 1 週間で抜糸をおこない退院となった。皮弁は約 3 週間で上皮化した。その後も外来にて経過フォローを継続し、術後半年の時点で良好な乳輪乳頭の形態を維持している。

【考察】

本術式は主に次のような特徴があるといえる。①乳房切除時の瘢痕に沿うように VY 皮弁をデザインすることで、乳房に新たな瘢痕をつくらずに乳頭再建が可能である。②筋皮弁として flap を挙上し ICG でも確認することで、皮弁血行をより担保できる。③皮弁に minced skin graft を塗布することで上皮化の促進と乳頭の質感を再現できる。④手術手技が簡便で安定した手術成績が期待できる。

一般演題 (口演) | 一般演題 2 (皮膚創傷治療 1)

J69

糖尿病性潰瘍に対する有効な治療法としてのマイクロニードルの可能性

森永 絵理 (もりなが えり)、高木 誠司

福岡大学 形成外科

【目的】

糖尿病性潰瘍は、糖尿病患者のほぼ 6% にみられる難治性の合併症である。糖尿病性潰瘍の患者の中には、現在の標準治療では大腿切断を防ぐことができない者もいる。したがって、新規で効果的な根治療法が必要である。マイクロニードルは、美容医療において広く応用されている創傷治療法である。本研究では、糖尿病性潰瘍に対するマイクロニードルの治療効果を動物モデルを用いて評価した。

【方法】

薬物誘発糖尿病を有する 9~10 週齢の雄性 C57BL/6J マウスを用い、背部の全層皮膚切除を行った。マイクロニードル治療を行ったマウスと行わなかったマウスをそれぞれマイクロニードル治療群と非治療群に分類した。マイクロニードルの治療効果は、治療後 14 日までの創傷閉鎖率と創傷の組織学的評価によって評価した。

【結果】

創傷閉鎖率は、マイクロニードル施術 7 日後より、マイクロニードル施術群で非施術群より有意に高かった (創傷閉鎖率: $63.0 \pm 4.1\%$ vs $40.8 \pm 4.7\%$)。組織学的評価から、マイクロニードルは 12 時間以内に好中球と M1 マクロファージの微小出血部位への浸潤を誘導することが明らかになった。マクロファージはマイクロニードルの 4 日後には M2 マクロファージに移行した。マイクロニードルの 7 日後には、トランスフォーミング増殖因子 $\beta 1$ の過剰発現が確認された。その後、コラーゲン増殖と新生血管の促進が、それぞれマイクロニードル 10 日後と 14 日後に見られた。

【考察】

我々のデータは、糖尿病性潰瘍の動物モデルにおいて、マイクロニードルが創傷治療に有効であることを明らかにした。この研究は、小動物モデルおよび急性外科創傷と関連する限界を含んでいる。今後の臨床試験が推奨される。

一般演題 (口演) | 一般演題 7 (顔面骨・手の外科・乳房)

J70

Shear wave elastography を用いた頭蓋内圧の非侵襲的な測定法の研究

安藤 暢浩 (あんどう のぶひろ)¹、三川 信之¹、秋田 新介¹、平田 慎之介²¹ 千葉大学医学部 形成外科² 千葉大学 フロンティア医工学センター

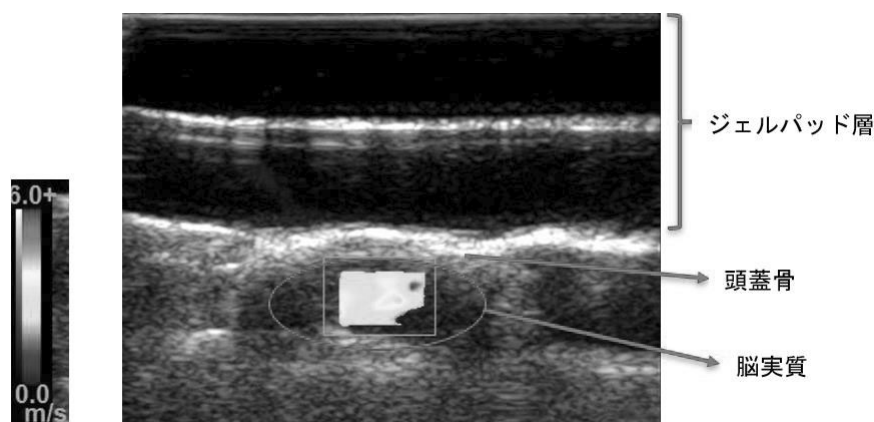
【目的】頭蓋縫合早期癒合症では、高い頭蓋内圧が様々な症状を引き起こす。本疾患の患児において、頭蓋内圧を非侵襲的に測定することができれば、その値は治療介入における重要な指標となる。本研究はその前段階として、動物実験において Shear wave elastography を用いて脳実質の弾性力を測定し、頭蓋内圧と相関を得ることを目的として開始された。今回われわれは、頭蓋内圧を変動させることができるラットの作成と、ラット脳実質の弾性力の測定について結果を得たので発表する。

【方法】成体ラットの全身麻酔後、頭蓋骨を露出させた。側方部に 2mm の骨孔を開け、内圧測定センサーを硬膜下に挿入した。また、第 1 頸椎上の硬膜下に翼状針を挿入し、生理食塩水を注入することで頭蓋内圧を上昇させた。また、別個体の正常ラットにおいて頭蓋骨を薄く削った後、音響放射カインパルスによって生体内組織の加振を行う Shear wave elastography を頭蓋骨上から当て、組織内せん断波速度と脳実質弾性力の測定を試みた。

【結果】生理食塩水を注入すると頭蓋内圧は上昇し、最大 45mmHg まで上昇させることに成功した。正常ラット脳実質のせん断波速度は約 3.0m/s で弾性コントラストは図のようになったが、測定は不安定であった。

【考察】ヒト新生児では、大泉門上から Shear wave elastography を用いて脳実質の弾性力を測定し、頭蓋内圧と相関が得られたとする報告があるが、動物実験で行った報告は未だない。現時点の研究成果では、ラット頭蓋内の観察と脳実質弾性力の測定は可能であり、今後は頭蓋内圧を上昇させた状態で脳実質弾性力を測定し、頭蓋内圧との相関を確認したいが、現時点の方法では弾性力の測定が安定せず、相関を得ることは難しいと考えている。原因として、インパルスが頭蓋骨で遮られてしまうことや、プローブに比較して脳実質が小さすぎるのが考えられた。今後は、モデル動物をウサギに変更し、頭蓋骨の一部を外科的に切除した上から測定を試みていく予定である。

図. Shear wave elastography による脳実質弾性力の測定



一般演題 (口演) | 一般演題 1 (腫瘍・移植ほか)

J71

当院当科で過去 3 年間に取り扱った脂肪腫 100 例の統計

中尾 仁美 (なかお ひとみ)、末吉 遊、林 利空、田中 信行、楠原 廣久、富田 與一

近畿大学病院

【目的】脂肪腫は軟部腫瘍では最もよく発生し、1000 人に 1 人以上が罹患すると考えられている。2020 年 1 月 1 日から 2023 年 12 月 31 日の 3 年間に脂肪腫と診断された症例 100 例について集計し、今後の術前診断ならびに病理検査結果予測の一助とする。

【方法】2020 年 1 月 1 日から 2023 年 12 月 31 日の 3 年間に当科で摘出した脂肪腫 100 例について、診療録から抽出し得た結果について後ろ向き研究を行った。抽出項目は、年齢、性別、部位、発見から受診までの期間、肉眼所見、術前画像検査、病理検査結果、既往歴とした。同一患者については、部位が異なった場合はそれぞれで 1 例とした。術前画像検査を複数行っている症例は、のべ数とした。

【結果】年齢は、13 歳から 89 歳。性別は、男性 53 例、女性 47 例。部位は、頭部、頸部、上肢、腹部、背部、臀部、下肢と全身に至っていた。術前画像検査は、MRI は 56 例、CT は 14 例、エコーは 30 例、PET は 1 例、画像検査なしは 4 例。病理検査結果では、脂肪腫は 90 例、筋肉内脂肪腫は 3 例、血管脂肪腫は 2 例、多形脂肪腫様腫瘍は 2 例、紡錘形細胞性脂肪腫は 1 例、褐色脂肪腫は 1 例、線維脂肪腫は 1 例であった。単発例は 94 例、多発例は 6 例であった。

【考察】検討項目について文献学的考察を踏まえて報告するとともに、印象的であった症例を供覧する。

一般演題 (口演) | 一般演題 7 (顔面骨・手の外科・乳房)

J73

唇裂患者における外鼻の左右差
～相同モデルを用いた 3 次元形態解析～

勝部 元紀 (かつべ もとき)、宇都宮 夏子、熊切 将宜、森本 尚樹

京都大学大学院医学研究科形成外科学

【目的】当科にて加療中の 15 才以上の唇裂患者のうち、成人期の外鼻修正手術を未施行の 64 人に対し Vectra を用いて 3 次元画像を取得した。患者内訳は男女比は 37:27、平均年齢 16.8 歳 (15～24 歳)、左右比は 21:43、幼少期の外鼻形成術は 45 人に認め、顎裂を 51 人に認めた。3 次元画像を元に HBM Rugle を用いて相同モデルを作成し、まずは 3D slicer の DeCa module を使用して顔面全体の左右差の解析を行なった。更に外鼻については 鼻翼、鼻尖、鼻背にわけて左右差の平均スコアを抽出し、患者データとの関連性について統計解析を行なった。

【方法】当科にて加療中の 15 才以上の唇裂患者のうち、成人期の外鼻修正手術を未施行の 64 人に対し Vectra を用いて 3 次元画像を取得した。患者内訳は男女比は 37:27、平均年齢 16.8 歳 (15～24 歳)、左右比は 21:43、幼少期の外鼻形成術は 45 人に認め、顎裂を 51 人に認めた。3 次元画像を元に HBM Rugle を用いて相同モデルを作成し、まずは 3D slicer の DeCa module を使用して外鼻全体顔面全体の左右差の解析を行なった。更に外鼻については 鼻翼、鼻尖、鼻背にわけて左右差の平均スコアを抽出し、患者データとの関連性について統計解析を行なった。

【結果】患者ごとに左右差を生じる部位は当然異なるが、平均した場合に最も左右差が大きいのは鼻翼部分であった (図1)。また左右差の標準偏差については鼻尖が最も大きかった (図2)。つまり、多くの患者において鼻翼に左右差があり、中には鼻尖に顕著な左右差を認める患者が存在していた。また、外鼻各部位の左右差の平均スコアと患者データ (患者性別、唇裂の左右、顎裂の有無、外鼻手術歴) の間には統計学的有意な関連性は示されなかった。

【考察】今回、相同モデルを用いることで外鼻の左右差を定量的に評価できた。唇裂患者において患側鼻翼が低形成であることを定量的にしめすことが出来た。また、顎裂や手術歴との関連は認めなかったが、今後は対象患者数を増やして解析を進めたい。また今回適応した解析手法を応用することで成長を加味した唇裂患者の形態把握を更に進めていきたい。




図1




図2

一般演題 (口演) | 一般演題 6 (血管・リンパ管)

J74

ペルフルブタンによる造影超音波と ICG 血管造影を併用したリンパ管-静脈吻合の術前評価

桑原 征宏 (くわばら まさひろ)、得能 香菜、平山 貴浩、細山田 広人、山本 直人

自治医科大学附属さいたま医療センター形成外科

【目的】

リンパ浮腫に対するリンパ管静脈吻合術は標準的な手術となってきた。術前にインドシアニンググリーン (ICG) 造影検査を行いリンパ管の走行を描写してから手術を実施する施設が多いと思われるが、リンパ浮腫の状態が酷いと造影されない場合や、Dermal Backflow sign で Diffuse パターンを呈してリンパ管の走行がわからず切開線の決定に難渋することがある。そこでわれわれはペルフルブタン (商品名ソナゾイド) を用いた造影エコーによるリンパ管造影と ICG 造影検査を併用することでより、リンパ管が造影されない症例や Diffuse パターンで全体が造影されてしまう症例でも、簡単で安全なリンパ管静脈吻合術が可能と考え報告する。

【方法】

第二世代超音波造影剤ペルフルブタンは 2007 年 1 月に日本で販売され、肝腫瘍、乳腺腫瘍でのみ保険適応が可能である。当院では倫理委員会を通して試験的にリンパ浮腫の患者に対してペルフルブタンを用いた造影エコーを実施し、吻合に適しているリンパ管及び静脈を確認できる部分で皮膚切開を実施している。副作用はほぼなく安全に使用でき、肝代謝のため腎不全患者にも使用可能である。15 人の患者で術前にマーキングした皮膚切開部分で術中にリンパ管を確認できた部分を検討した。

【結果】

15 人の患者に術前 ICG およびペルフルブタンを用いた造影エコーを実施したところ、ICG 単独群が 72.6% のリンパ管検出率だったのが、併用群では 83.6% と高い検出率を認めた。また術前 ICG で diffuse pattern を呈した部分の造影エコーでのリンパ管検出率は 68.6% だった。

【考察】

造影剤を用いないリンパ管エコーの報告もあるが、高周波数のエコー (33MHz、70MHz など) が必要な場合や、静脈との区別が困難で熟練の手技が必要かと思われる。造影剤を用いた造影エコーは 18MHz と低周波数のプローブでもリンパ管と静脈を区別できるため、リンパ管の走行を確認するのに有用な検査と考えられ、少ない切開で効果的な吻合を行うことができる。これから症例を重ねていき、少ない切開部位で確実な吻合ができる部分を術前に判断できるようにしたい。

一般演題 (e ポスター)

J76

ケロイド由来線維芽細胞及び正常皮膚由来線維芽細胞を用いた RNA-seq 解析

櫻山 和也 (かしま かずや)、猪狩 紀子、東 晃史、岩尾 敦彦、西條 広人、森内 由季、
葉石 慎也

長崎大学形成外科

【目的】

ケロイドは皮膚に生じる線維化疾患であることから、強皮症や肺線維症などの他の線維化疾患とともに研究がなされている。しかし、線維化に加えて、強い浸潤性と増殖性を持つというケロイドはその中でも異質の存在であり、いまだその病態すらはっきりと解明されていない。本研究の目的は、ケロイド由来の線維芽細胞に特徴的な遺伝子発現を検出し、ケロイド病態の原因を追究することである。

【方法】ケロイド病変及び正常皮膚の検体は、4 例の日本人より手術時に採取した。ケロイド病態部はケロイド病変部辺縁の肥厚及び発赤を伴っている部分より採取し、正常皮膚の検体は同一症例のケロイド辺縁より 5mm 離れた発赤を伴わない正常皮膚より採取した。ケロイドであるとの診断は臨床病態及び病理所見より判断を行った。線維芽細胞の培養は、Explant 法で行った。培養 2 週間で採取された線維芽細胞を継代 0 として採取し、RNA の抽出を行った。Total RNA の抽出は miRNeasy mini kit (QIAGEN, Tokyo, Japan)で行った。RNA-seq 解析 (名古屋大学環境医学研究所発生遺伝分野ゲノム不安性疾患検査センター, Nagoya, Japan) を行った。データ解析は RNAseqChef (Pair-wise DEG, DESeq2, Benjaminie Hochberg method, Fold change>2, FDR<0.05, Basement 0) を用いて行った。本研究は倫理委員会の承認を得ている (長崎大学病院臨床研究倫理委員会・許可番号 2208015)。

【結果】

NF に比較して、KF で増加している RNA が 18 個と減少している RNA が 3 個得られた。NFTX2 及び FGF9 の増加が確認された。

【考察】

当院で先行して行ったケロイド及び正常皮膚の組織検体を使用した micro array においても、ケロイド組織において NPTX2 と FGF 9 の増加を認めており、これらの遺伝子の発現増加がケロイド病態の一因を担っている可能性がある。NPTX2 はアトピー性皮膚炎や接触性皮膚炎で慢性的なかゆみの原因の一因とされている神経伝達物質であることから、ケロイド病態で活動性の高い部分におけるかゆみの原因の一因として NPTX2 の関与が示唆された。

一般演題 (口演) | 一般演題 8 (AI ほか)

J77

ソトス症候群の DNA メチル化解析で *IGF2*-DMR0 が *IGF2* P0 特異的 enhancer であり、過成長に関与する可能性を示した

渡邊 英孝 (わたなべ ひでたか)¹、田中 恵理香¹、中川 栄治¹、吉住 茉莉子¹、永野 義博¹、
副島 英伸²、上村 哲司¹

¹ 佐賀大学医学部附属病院 形成外科

² 佐賀大学分子生命科学講座 分子遺伝学・エピジェネティクス分野

【目的】ヒストン H3 リジン 36 (H3K36) のジメチル化酵素である *NSD1* 遺伝子のハプロ不全は、過成長症候群であるソトス症候群を引き起こす。DNA メチル化酵素 DNMT3A および DNMT3B は、H3K36 トリメチル化を認識し DNA をメチル化して、インプリント DMR を確立する。この H3K36 トリメチル化は、他のヒストンメチル化酵素である SETD2 により H3K36 ジメチル化から変換される。DNMT3A および SETD2 における変異は、ソトス症候群様の過成長症候群の患者において特定されており、さらに最近では、H3K36 ジメチル化自体が DNMT3A のリクルートや DNA メチル化の維持に必要であることが報告されてきている。このことから、ソトス症候群ではインプリント DMR の低メチル化が予想される。そこで、ソトス症候群のインプリント DMR のメチル化を解析し、病態への影響について明らかにすることを目的とした。

【方法】ソトス症候群患者 31 人のインプリント DMR 28 カ所の DNA メチル化を MALDI-TOF MS 法と bisulfite-pyrosequencing 法で解析し、得られた結果についてさらに培養細胞を用いて DMR のメチル化とインプリント遺伝子の発現量を定量的に解析、*IGF2* P0 promoter 活性の検討、ヒストン修飾の状態解析など、詳細な実験を行った。

【結果】ソトス症候群患者では高頻度に *IGF2*-DMR0 の低メチル化を認め、また *IGF2*-DMR0 は、*IGF2* P0 promoter の特異的エンハンサーであるということが示された。エピゲノム編集により *IGF2*-DMR0 特異的に低メチル化を起こすと、*IGF2* の P0 プロモーターからの転写が増加したが、P3・P4 プロモーターからの転写は変わらなかった。

【考察】*IGF2*-DMR0 が *IGF2* の P0 プロモーターからの転写を調節する DNA メチル化依存性のエンハンサーであると解明した。DNA 低メチル化による *IGF2* の過剰発現が、ソトス症候群の表現型である過成長の一因に関与する可能性があると考ええる。

一般演題 (口演) | 一般演題 3 (皮膚創傷治療 2)

J79

ラット皮弁虚血再灌流障害モデルによるバトロキソビンの皮弁壊死抑制効果の検討

今川 孝太郎 (いまがわ こうたろう)¹、増田 治史²、森田 大貴³、大塚 静香³、赤松 正³¹ 東海大学医学部付属八王子病院形成外科² 湘南鎌倉総合病院臨床研究センター³ 東海大学医学部外科学系形成外科

【目的】バトロキソビンは蛇毒から抽出精製されたトロンビン様酵素で抗血栓作用を有し慢性動脈閉塞症に適応のある薬剤である。当該施設では本薬剤が Neutrophil extracellular traps (NETs) を阻害し、微小循環を改善することを報告している。今回はラット皮弁虚血再灌流障害モデルによるバトロキソビンの皮弁壊死抑制効果について検討した。

【方法】ラットの左腹部に 4.5x3cm の浅腹壁動静脈を茎とする皮弁を挙上し、血管茎を 6 時間クランプした後解除し虚血再灌流モデルとした。血管クランプ解除時にバトロキソビン 10BU/kg を腹腔内投与 (1 回のみ) する群と、コントロール群 (生食投与) で検討した。皮弁内の血液灌流範囲をレーザードプラーで確認、組織染色としてカルプロテクチン (NETs の発現)、CD31 を観察した。

【結果】レーザードプラーでの皮弁内灌流領域の平均は 48 時間でコントロール群 (n=10) : 27.04% (SD18.7)、バトロキソビン投与群 (n=10) : 58.9%(SD15.3)、7 日目でコントロール群 (n=5) : 44.6%(SD18.3)、バトロキソビン投与群 (n=5) : 78.1%(SD5.8)であった (P<0.05)。組織学的検討では、再灌流後 48 時間のカルプロテクチン染色で、バトロキソビン投与群の NETs 発現が少ないことが認められた。また、7 日目では皮下血管がバトロキソビン群で多く認められる結果であった。

【考察】レーザードプラー血流イメージと組織学的検討から、バトロキソビンは虚血再灌流障害モデルにおいて皮弁内血流保護作用があることが認められた。その機序として従来からのフィブリンノーゲン活性抑制作用に加えて、NETs 発現を抑制することが確認された。NETs の過剰発現は微小循環を阻害することが知られており、虚血再灌流障害などの炎症に起因して生じる組織壊死に対し本薬剤が効果を発揮する可能性が示唆された。

一般演題 (e ポスター)

J80

皮下線維束組織を用いたリンパ管静脈吻合術

井上 唯史 (いのうえ ただし)、竹川 政裕、棟田 陽子

洛和会音羽病院

【背景】リンパ管静脈吻合で用いる毛細リンパ管は、基底膜や周皮細胞がなく、リンパ内皮細胞と弾性線維の膜からなる管腔構造をしている。リンパ浮腫患者の皮下組織は硬化しており、リンパ管を癒痕組織から剥離単離することは困難である。

【目的】リンパ浮腫患者のリンパ管構造を病理解剖学的に検討し、リンパ管を含んだ線維束組織でのリンパ管静脈吻合術について検証した。

【方法】リンパ浮腫でリンパ管静脈吻合術を行った患者の吻合リンパ管組織を透過電子顕微鏡と走査電子顕微鏡を用いて観察した。

【結果】

症例 1: 73 歳女性

準広汎子宮全摘術と後腹膜リンパ節郭清術後 1 年から右足背浮腫が出現した。(ISL Stage II) コラーゲン線維に埋もれた弾性線維のみの管腔構造を認めた。(リンパ管直径 : 41.72 μm)

症例 2: 79 歳男性

2020 年に両下腿静脈瘤手術後 2 年から左下肢浮腫が出現した。(ISL stage II 後期) 乱走したコラーゲン線維の組織塊の中に、蛇行した弾性線維のみからなる管腔構造を認めた。(リンパ管直径 : 3.34 μm)

症例 3: 74 歳女性

2015 年 2 月単純子宮全摘術、両付属器切除、大動脈リンパ節郭清術後 3 年から右下肢に浮腫が急激に出現した。(ISL Stage II) 整列したコラーゲン線維束の中に弾性線維のみの管腔構造を認めた。(リンパ管直径 : 46.71 μm)

症例 4: 45 歳女性

広汎子宮全摘術と後腹膜リンパ節郭清術後 4 年から右下肢浮腫が出現した。(ISL Stage II) 電顕像では、吻合リンパ管組織は、整列したコラーゲン線維束の中にある弾性線維のみの管腔構造であった。(リンパ管直径 : 17.71 μm)

【考察】リンパ浮腫のリンパ管は、厚いコラーゲン組織塊の中に一層の弾性線維の膜でできた管腔構造物であった。リンパ管の直径は最大で 46 μm であった。デリケートで細いリンパ管を剥離し、既製の縫合糸で血管に吻合することは困難であると考えられた。皮膚直下の線維束には厚いコラーゲン組織の中に管状構造様のリンパ管が多数埋入していた。線維束中のリンパ管と血管を吻合することは、合理的であると考えられた。

一般演題 (口演) | 一般演題 3 (皮膚創傷治療 2)

J82

難治性感染症に対する新規治療法の開発

岡野 純子 (おかの じゅんこ)¹、西川 絢子²、藤野 和典³、仲川 孝彦⁴、小島 秀人⁴

¹ 滋賀医科大学形成外科講座

² 滋賀医科大学皮膚科講座

³ 滋賀医科大学救急集中医学講座

⁴ 滋賀医科大学生命情報開拓講座

【目的】 多剤耐性菌が原因となる感染症は治療抵抗性であり、医療従事者も患者および家族も疲弊する。当科でも扱う感染症疾患は皮膚難治性潰瘍を始め、術後感染症等多岐にわたる。新規抗生物質開発は多大に費用がかかる一方、病原菌は接合伝達による耐性遺伝子の水平伝播や形質転換によって容易に抗生物質耐性を獲得する。WHO は、現在のままだと 2050 年には年間1000万人以上が多剤耐性菌による感染症によって死亡し、ガンによる死亡数を上回ると警告している。バクテリオファージ (以下ファージ) は、細菌や古細菌に感染し、ヒトには感染しないウイルスであり特異的に標的菌を溶菌できることから、多剤耐性菌に対する次世代の治療選択肢として注目されているファージセラピー)。本研究では、病原菌に対して有効なファージの source を探索した。

【方法】

病原菌に特異的なファージを探索するため、滋賀医科大学医学部附属病院の病院排水からファージを単離後、プラークアッセイ、濁度検査、電子顕微鏡による観察を行った。

【結果】

滋賀医科大学医学部附属病院の病院排水から単離されたファージは、同病院に入院した患者の皮膚潰瘍部から検出された緑膿菌、黄色ブドウ球菌 (MRSA) に対しては溶菌活性を持たなかったが、カテーテル尿から検出された大腸菌に対して持続して溶菌活性を示した。電子顕微鏡にて、Cadovirales 特有の形態が観察された。

【考察】

多剤耐性菌に対する難治性感染症に対し、病院排水から単離したファージを用いるファージセラピーの可能性が示唆された。

一般演題 (口演) | 一般演題 9 (再生医療)

J83

免疫不全マウスを用いた人工真皮移植モデルでのヒト DFAT の創傷治癒促進効果の検証

長崎 敬仁 (ながさき けいと)^{1,3}、樫村 勉¹、松本 太郎²、副島 一孝¹¹ 日本大学医学部形成外科学系形成外科学分野² 日本大学医学部機能形態学系細胞再生・移植医学分野³ みつわ台総合病院

【目的】

脱分化脂肪細胞 (Dedifferentiated fat cell: DFAT) は、成熟脂肪細胞に由来する細胞であり、間葉系幹細胞 (mesenchymal stem cell) に似た多分化能を有する。われわれは、ラット人工真皮移植モデルを用いた実験で、DFAT の創傷治癒促進効果を検証し、同種同系ラットより調整した DFAT が、人工真皮移植モデルにおいて、真皮様組織の構築促進効果および血管新生効果が得られたことを報告した。今回、免疫不全マウスを用いた実験モデルで、ヒト DFAT が同様の効果を示すか検証した。

【方法】

ヒト DFAT は大学倫理委員会の承認の元(承認番号 RK-210914-1)、患者より文書で承諾を得て手術時に余剰となった脂肪組織から調整した。SCID マウスの背部に作成した 2×3cm の全層皮膚欠損創に人工真皮(PELNAC®、通常タイプ、GUNZE)を移植するモデルを作成し、移植床に DFAT を散布した群と散布しない対照群を作成した。移植後、1,2,3 週間目に組織を採取し、Hematoxylin and Eosin (H-E) 染色、膠原線維の同定目的に Masson-trichrome (MT) 染色、血管新生の検索目的に抗マウス CD31 モノクローナル免疫染色、ヒト由来血管内皮細胞の検索目的に抗ヒト CD31 モノクローナル免疫染色を用いて組織学的評価を行った。

【結果】

1 週間後の真皮様組織は治療群で有意に厚く、2 週間後の膠原線維の量は、治療群で有意に多かった。さらに、2 週間後の新生血管数は治療群で有意に多かった。抗ヒト CD31 モノクローナル抗体陽性細胞は、3 週目に治療群の真皮様組織で観察された。

【考察】 今回の結果より、ヒト DFAT も真皮様組織の構築促進、血管新生促進効果を有することが確認された。血管内皮細胞への分化は、移植初期は paracrine 効果も推測されるが、抗ヒト CD31 モノクローナル抗体が陽性であり、血管内皮細胞への分化も示唆された。

一般演題 (口演) | 一般演題 8 (AI ほか)

J84

ABCC11 遺伝子の SNP 保有率と腋臭症発症因子の関連性に関する臨床研究

伊藤 賢奎 (いとう たかふみ)¹、久保村 憲¹、桑原 大彰¹、小川 令²、赤石 諭史¹¹ 日本医科大学武蔵小杉病院形成外科² 日本医科大学付属病院 形成外科・再建外科・美容外科

【はじめに】腋臭症は耳垢型決定遺伝子である ABCC11 遺伝子の一塩基多型 (SNP : 538G > A(rs17822931; Gly180Arg)) との関連が示唆されており、日本人の約 10-15% が湿型耳垢を有するためこの遺伝子の保有者とされる。腋臭症には客観的診断基準がないため、この遺伝子検査は腋臭症の診断に役立つと考えられるが、実際にその有用性を示した研究はない。本研究は、腋臭を主訴とする患者で真の腋臭症の割合と、この ABCC11 遺伝子の SNP 保有者で腋臭症発症に影響を与える因子を解析した。

【方法】腋臭を主訴とする患者 (N=152) を対象に、ABCC11 遺伝子の SNP 検査を実施し、ホモ、ヘテロ、なしに分類し、腋臭症皮弁法の術中所見でアポクリン汗腺の増生の有無を確認した。また患者の年齢、性別、家族歴、耳垢型、手掌多汗症の有無、器質的疾患の既往有無の指標を収集した。統計解析には多変量解析を用い、有意水準を 5% とした。

【結果】患者 152 人のうち、ABCC11 遺伝子の SNP 保有者 (ホモおよびヘテロ) は 120 人 (78.9%) であり、その全例に術中所見でアポクリン汗腺の増生を認めた。多変量解析の結果、この遺伝子の保有者で腋臭症の発症に有意な影響を与える因子として、家族歴 (オッズ比: 2.34, $p < 0.01$)、湿型耳垢 (オッズ比: 2.58, $p < 0.01$)、および手掌多汗症 (オッズ比: 1.87, $p < 0.05$) が挙げられた。また、器質的疾患の既往は腋臭症発症に関連なかった。

【考察】腋臭を主訴に受診する患者の約 79% が上記遺伝子の保有者であり、術中所見より真の腋臭症患者であることが確認された。本研究により、腋臭症発症には家族歴、耳垢の湿潤状態、手掌多汗症が有意な影響を与えることがわかった。真の腋臭症の診断精度の向上は、患者への最適な治療法の提供に寄与すると考えられる。

結論：本研究は、腋臭を主訴に受診する患者の大部分が ABCC11 遺伝子の SNP 保有者であることを示し、腋臭症発症に影響を与える因子を特定した。腋臭症の診断および治療における新たな視点が提供され、今後の臨床応用が期待される。

一般演題 (口演) | 一般演題 8 (AI ほか)

J85

多血小板血漿 (PRP) の透過率による品質管理方法の開発

長島 隼人 (ながしま はやと)^{1,2}、矢下 茂毅³、澤根 佑里⁴、木戸 祐輔⁴、野崎 貴裕^{1,4}、
矢澤 真樹¹、貴志 和生¹

¹ 慶應義塾大学 医学部 形成外科

² 栃木県立がんセンター 形成外科

³ 慶應義塾大学大学院 理工学研究科 総合デザイン工学専攻

⁴ 慶應義塾大学 理工学部 システムデザイン工学科

【目的】多血小板血漿 (PRP; Platelet Rich Plasma) による治療は、血小板から放出される各種成長因子が自己治癒力をサポートし、創傷治癒や組織再生を促進することが期待されている。変形性関節症や各種手術時の使用に加え、スポーツ医学や美容医学への応用が進んでいる。しかし、PRP の品質確認は、血球計数器や顕微鏡を用いた血小板の濃度測定や異物混入の確認に依存している。これらの方法は高額な機器を必要とし、目視による場合は煩雑で人為的ミスや誤差が生じる可能性がある。そこで、我々は物理的特性 (粘度・導電率・透過率) から PRP 濃度を推定する新たな手法を検討し、光学的特性である透過率からの推定が最も高精度であることを報告した。今回は透過率測定を用いて PRP への異物混入を検知できるかどうか、赤血球をモデルとして検証した。

【方法】被験者 4 人からそれぞれ 30 ml の採血を行い、3.2%クエン酸ナトリウム 4 ml と混和した後、200 g で 10 分間の遠心分離を行い、PRP と赤血球を作成した。各試料の透過率は分光光度計 (UV1280、島津製作所) を用いて測定し、PRP と赤血球の混合試料の測定も実施した。

【結果】赤血球のみを測定した場合、420 nm および 570 nm 付近のヘモグロビン吸収波長で透過率の変化が観察された。PRP と赤血球の混合試料については、800 nm および 900 nm の 2 波長の測定値からランベルトベールの法則を用いた連立方程式を解くことで、血小板と赤血球の濃度を推定することが可能であった。

【考察】分光光度計による測定により、赤血球の混入有無および混入の程度を高精度で推定できる可能性が示された。この手法は従来よりも安価な機器と方法で PRP の濃度推定と品質管理を行うことが可能であり、PRP 治療の安全性確保および治療成績の向上に寄与することが期待される。

一般演題 (口演) | 最優秀一般演題セッション

J87

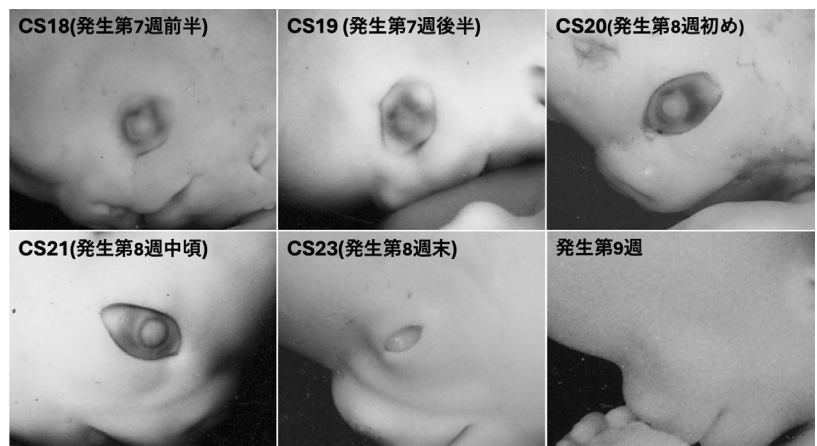
ヒト標本を用いた初期眼瞼発生時期の検討

熊切 将宜 (くまきり まさのり)^{1,2}、勝部 元紀¹、宇都宮 夏子^{1,2}、森本 尚樹¹、山田 重人²¹ 京都大学大学院医学研究科 形成外科学² 京都大学大学院医学研究科 先天異常標本解析センター

【背景・目的】眼瞼の発生は、マウスでの実験レベルでは関連するシグナル分子や経路が特定されつつあるが、ヒトでは胎児標本は非常に貴重であり、正常眼瞼の発生でさえ未解明なことが多い。先天性眼瞼下垂、コロボーマ、潜伏眼球など、様々な先天性眼瞼疾患があり、これらの異常の発生時期の特定や病態理解には正常眼瞼の発生パターンの理解が重要である。本研究では組織切片および外観写真を用いて、ヒト発生初期における眼瞼の正常発生過程を解明することを目的とした。

【方法】世界最大の胎児標本数を誇る京都コレクションから、最初に眼瞼が現れる Carnegie Stage (CS) 18 (発生第 7 週初め) から上下眼瞼が癒合する発生第 9 週までの正常ヒト胚子および胎児の 39 例 78 側の連続組織切片と外観写真を対象とし、眼瞼の各構造が観察される時期を記録した。

【結果】内・外眼角は CS20 頃に形成され、内眼角がわずかに早く形成された。挙筋腱膜や lower eyelid retractors (LER) は CS20 で結膜円蓋部に生じた細胞集積から、CS22 から CS23 頃に膜状に変化し徐々に凝集した。内眦部には CS21 頃から細胞集積を認め、徐々に凝集した。眼瞼の癒合は CS23 で認め、発生第 9 週では全例で認めた。癒合途中の標本では内側のみが癒合している標本、両側が癒合している標本があり、外側のみ癒合している標本はなかった。涙小管は CS20 で観察され、CS23 以降で涙小管垂直部が観察された。発生第 9 週で半月襞と思われる構造が観察できたが、涙丘は観察できなかった。



【考察】内・外眼角、挙筋腱膜、上下涙小管の形成、眼瞼の癒合の時期は既報とほとんど同様であった。LER は相同な構造とされる挙筋腱膜とほとんど同時期に発生していた。眼瞼癒合は鼻側から始まると考えられた。内眦靱帯の細胞集積は既報よりかなり早い時期から認めた。涙丘は涙小管が全長にわたって形成されているにも関わらず確認できず、下眼瞼から涙小管によって切り出されるという定説を支持しない結果であった。

一般演題 (口演) | 一般演題 7 (顔面骨・手の外科・乳房)

J88

光超音波イメージング装置を用いた脂肪注入後の再建乳房の血管構造の解析

角田 祐衣 (つのだ ゆい)¹、武藤 真由¹、佐武 利彦^{1,2}

¹ Lala プレスト・リコンストラクション・クリニック横浜

² 富山大学形成再建外科・美容外科

【目的】脂肪注入などの遊離組織移植には血管新生が不可欠であり、脂肪の生着率向上のために付加する脂肪幹細胞や PRP などは血管新生促進因子としても知られている。移植した組織内の新生血管を観察するためには組織生検や造影剤を用いた画像検査を要し、患者侵襲の観点から実臨床で頻回に行うことは困難である。今回、非侵襲的に血管を可視化できる光超音波イメージング装置(LUB、株式会社 Luxonus)を用いて、脂肪注入による再建乳房を検査し、血管画像の解析を行った。

【方法】片側乳癌術後に脂肪注入による全乳房再建を行った症例を対象とした。いずれの症例も最終手術から半年以上経過後に、光超音波イメージング装置を用いて、健側乳房と患側(再建)乳房内の血管走行の比較を行った。

【結果】症例は 4 例であり、1 例は純脂肪注入による再建、3 例は培養脂肪幹細胞付加脂肪注入による再建であった。健側乳房では中間層の脂肪組織や乳腺組織内に水平方向の血管の走行を認め、浅層(皮膚直下)からの血管と連続していたが、患側乳房の注入した脂肪が生着したと思われる中間層では、浅層の血管から細い血管が垂直方向に伸長しているが、水平方向の血管が少なく、途中で途切れていた。また一部では深層の血管からの血管の伸長も認められた。

【考察】光超音波イメージングはヘモグロビンの吸収が大きい近赤外レーザー光を用いることにより、非侵襲的に解像度の高い 3 次元の血管画像を得ることができ、遊離皮弁における手術計画や腫瘍の新生血管の描出にも応用されている。患側乳房内で観察された垂直方向の血管は血管新生により伸長した血管を観察している可能性があるが、更なる検証には脂肪注入前後で画像を比較する必要がある。

一般演題 (口演) | 一般演題 6 (血管・リンパ管)

J89

Vascular Malformations における PIK3CA 遺伝子変異の検討

玉懸 美菜実 (たまがけ みなみ)¹、岩崎 一磨¹、鈴木 綾乃¹、三浦 千絵子¹、今井 啓道¹、
長尾 宗朝²、青木 洋子³、尾崎 峰⁴¹ 東北大学病院形成外科² ファミリアクリニック卸町³ 東北大学病院遺伝科⁴ 杏林大学医学部付属病院形成外科・美容外科

【目的】近年 PIK3CA/Akt/mTOR 経路をはじめとする Vascular Malformations の遺伝子異常の検出により、mTOR 阻害薬などの薬物治療の有効性が注目されている。我々は、Klippel Trenanay Syndrome(KTS)などの症候性疾患が疑われる症例をはじめ、Arteriovenous Malformation(AVM)、Venous Malformation(VM)、Lymphatic Malformation(LM)症例群に対しても、切除および針生検による検体から、PIK3CA 遺伝子の解析を行い、薬物治療の併用の可能性を探ることとしている。

【方法】期間は 2022 年 4 月から 2024 年 9 月までに、東北大学病院形成外科および杏林大学病院形成外科において病変切除あるいは針生検を受けた Vascular Malformation 症例を対象とした。内訳は、臨床的に KTS と診断を受けている 13 症例、AVM 2 例、VM 18 症例、LM 5 例の合計 38 症例であった。摘出された検体より DNA を抽出し、次世代シーケンシングにより PIK3CA 遺伝子変異の解析を行い、その PIK3CA 遺伝子変異の解析を行った。

【結果】現時点(2024 年 5 月)で解析が終了しているもののうち、PIK3CA 変異が検出されたのは KTS 症例 4 例であった。KTS 5 例のうち、4 例で PIK3CA 遺伝子変異を確認し、うち 2 例は c.1633G>A (p.Glu545Lys)、1 例は c.3140A>T (p.His1047Leu)、1 例は c.1624G>A (p.Glu542Lys)といった KTS に典型的な hot spot 変異を確認した。残りの 1 例は、PIK3CA 遺伝子変異を認めなかった。

【考察】PIK3CA 変異が検出されなかった 1 例は KTS に典型的な臨床所見を呈していたものの、病変採取部が肉眼的に皮下の VM を呈する部位を採取して検体として DNA 抽出を行っていた。一方で、他の 4 例では microcystic LM を呈する部位を採取して検体として DNA 抽出を行ったことが、今回の差を生んだ可能性が考えられた。国内外の文献を渉猟し、検体の選択と遺伝子解析について考察した。

一般演題 (口演) | 一般演題 9 (再生医療)

J90

強化型人工脂肪を用いた脂肪再生

荻野 秀一 (おぎの しゅういち)¹、趙 倩楠²、加藤 優季^{2,3}、坂本 道治²、荒田 順¹、山岡 哲二⁴、森本 尚樹²¹ 滋賀医科大学 形成外科講座² 京都大学大学院医学研究科 形成外科学³ グンゼ株式会社 QOL 研究所⁴ 公立小松大学 保健医療学部

【目的】新たな乳房再建方法として、ポリ L 乳酸(PLLA)のメッシュを外殻としコラーゲンスポンジを充填した材料(人工脂肪)を開発した。ラットモデル、白色家兎モデルでの検討により内腔に形成された脂肪が1年以上維持されることを確認した。本材料は、細胞、細胞成長因子の付加なく生体内で脂肪に置換されるため、乳癌術後の再建にも安全に使用可能である。より大きな脂肪形成を目指し、人工脂肪 30 個をポリグルコール酸(PGA)のメッシュに充填した集合体をミニブタ腹部に埋植したところ、内腔に脂肪形成されたが、PLLA の吸収に伴い集合体の強度が失われ、1年以上維持できなかった。本研究では、組織圧耐性を増加させた人工脂肪を用い検討した。

【方法】内腔を支柱で補強した強化型人工脂肪(長軸 16mm、短 8mm)を作製した。強化型人工脂肪 30 個を PGA メッシュでまとめた集合体群と、周囲脂肪との接触面積を増加させるためにまとめず埋植する単独群に分け、ミニブタ雌の腹部乳腺下に埋植し検討した。埋植 12 か月まで、経時的に脂肪形成を MRI と組織学的に評価を行った。

【結果】MRI 評価により、埋植後人工脂肪の体積は徐々に減少し、埋植 12 か月で埋植前の約 40% (集合体群)と約 50%(単独群)となった。埋植 6 か月で、両群とも腹部脂肪と接する部位に脂肪形成を認め、形成された脂肪は人工脂肪体積の $13.3 \pm 3.1\%$ (集合体群)と $22.6 \pm 11.2\%$ (単独群)となり、両群間に有意差を認めなかった。埋植 12 か月では形成脂肪量が減少した。組織学的には埋植 12 か月で形成された脂肪はある程度残存したが、内腔が圧壊した。

【考察】強化型人工脂肪は PGA メッシュの使用の有無に関係なく脂肪形成可能であったが、12 か月以上形成脂肪を維持できなかった。ミニブタ腹部の組織圧が強く、脂肪形成の維持に大きく影響していると考えられるため、今後、材料形態の更なる検討、臨床での使用状況に合わせた埋植方法の検討を行い、より最適な材料の開発をする。

一般演題 (口演) | 一般演題 3 (皮膚創傷治癒 2)

J91

創部から分泌された滲出液内の創傷治癒に関わる細胞間ネットワーク因子の定量化の
試み

大山 拓人 (おおやま たくと)、谷 ありさ、鈴木 翔太郎、小柳 俊彰、自見 至郎、高木 誠司

福岡大学 医学部 形成外科

【目的】滲出液内には種々のサイトカインや増殖因子が含まれ、創傷治癒に向け複雑な反応を起こす。しかし、これら因子を実際に定量化した研究は少ない。今回創部から分泌された滲出液内の治癒因子の変動を見る目的で急性創傷である熱傷を中心に採取した滲出液内の炎症学的および増殖に関わる因子を定量化した。

【方法】2022 年 4 月より福岡大学病院に入院した急性の熱傷患者と慢性創傷患者を計 10 例用いた。創面上に綿球を 24 時間静置し、滲出液を吸収させ採取した。

滲出液はタンパク分解酵素阻害薬を含む RIPA 緩衝液で抽出し、測定まで -80°C で保存した。

滲出液内の IL10、 $\text{TGF}\beta$ 、 $\text{TNF}\alpha$ 、VEGF、HGF を ELISA 法を用い定量化した。

【結果】採集された滲出液は微量であったが、全ての因子の測定が可能であった。

各因子における経時的変動パターンが示され、特に熱傷後の $\text{TNF}\alpha$ の減少、IL10 の一過性上昇、VEGF 増加を認めた。

【考察】創傷治癒において、創部から産生されるサイトカインや増殖因子は創部での炎症の調整と肉芽増殖や血管新生に重要となる。今回の検討により、創部から分泌されたこれら因子を採取することが可能であることが示された。検討症例数は少ないものの、各因子分泌に生物学的パターンがあり、創内でのこれら因子のネットワークの存在が示唆された。

今後、症例数を増やし、急性および慢性創傷における創傷治癒に関わる細胞間ネットワーク因子の関連性をさらに明らかにしたい。

一般演題 (口演) | 一般演題 10 (レーザー)

J92

ナノサイズ微細水粒子 AIR (アイル) とヒト脂肪由来幹細胞培養上清液による女性の脱毛進行予防効果の検討

杉野 宏子 (すぎの ひろこ)

青山エルクリニック

【目的】ナノサイズ微細水(微細水)はスチーム粒子の 1000 分の1という小さな水粒子(AIR:アイル(株)アイシン開発)であり、皮膚によく浸透し、長時間滞留する性質を持つ。さらに皮膚に薬剤を塗付した後に微細水を放湿すると薬剤が皮膚に浸透しやすくなることが知られている。今回、微細水とヒト脂肪幹細胞培養上清液を女性型脱毛症患者の頭皮に使用し、毛直径の変化を調べ、脱毛予防効果を検討したので報告する。

【方法】脱毛傾向を自覚し、女性型脱毛症と診断された Savin Scale I-2~II-1 に相当し、同意取得時の年齢が 45 歳以上 59 歳以下の健常な女性を対象としたプラセボ対照二重盲検比較試験を行った。A 群(試験試料:微細水及び幹細胞培上清液付与)10 名、B 群(試験試料:幹細胞上清液のみ付与)12 名、C 群(試験試料:微細水及び生理食塩水付与)12 名であった。微細水は頭皮に幹細胞培養上清液または生理食塩水を塗布した後、20 分適用した。試験は 2 週間に 1 回、22 週まで試験試料を適用した後、24 週後、28 週後に経過観察を行い、初回観察(0 日)、12 週後、24 週後、28 週後にフォトリコグラムによる毛髪計測を行った。

【結果】毛直径の 24 週間後の相対値において、C 群のみ初回観察に対して有意な減少が認められた。A 群及び B 群では毛直径の減少が抑えられていることが確認されたが、有意な変化は認められなかった。しかし被験者ごとの変化に着目した場合、B 群よりも A 群の方がその減少を抑えている傾向があった。

【考察】微細水と幹細胞培養上清液を併用することにより、毛直径の減少を抑える効果が認められた。今後、育毛治療への臨床応用が期待される。

一般演題 (口演) | 一般演題 8 (AI ほか)

J93

患者向け顔面神経麻痺顔面スコアリングおよびリハビリテーションアプリの開発

矢野 智之 (やの ともゆき)¹、大野 森太郎²、嵯峨崎 天音²、高木 麻那²、岡田 亮²、半田 高広²、鍵本 慎太郎¹、辛川 領¹¹ がん研有明病院 形成外科² TOPPAN 株式会社

【目的】顔面神経麻痺はベル麻痺、ハント症候群、耳下腺悪性腫瘍切除における顔面神経の合併切除などによって発症する。薬物を用いた保存治療、神経移植などの手術治療が行われる。加えてリハビリテーションが顔面神経麻痺の治療におけるキーの 1 つである。リハビリテーションでは顔面神経麻痺については理学療法士や言語聴覚士が担当するが、嚥下、構音障害や四肢の運動障害への対応の優先順位が高く、リハビリテーションの介入が人手不足で困難となり、患者まかせになることもある。そこで患者が自分の麻痺の状況を定期的に把握し、自己流のリハビリテーションにならないように自宅治療をサポートするスマートフォンアプリの開発を TOPPAN 株式会社と行なったので報告する。

【方法】iPhone 用スマートフォンアプリを TOPPAN と共同で開発した。アプリは顔面の左右差のスコアリングとリハビリテーションのサポートから構成されている。前者は顔面の 5 つの表情と笑顔を撮影し、開発したアルゴリズムに沿って 0-100 点にてスコアリングを行なうものである。後者が、顔面神経麻痺のリハビリテーション動画に沿って、患者がアプリを見ながら自己マッサージを行なうものである。この際に各運動に対するゲーミング要素を用いたトレーニング要素、また異常共同運動に繋がるような動きに対するアラート機能を有している。

【結果】4 名の患者に対して形成外科外来にて概念実証実験を行なった。いずれの患者もスマートフォンアプリを用いた顔面スコアリングとリハビリテーションアプリを使用可能であった。一方でスコアリングについては、患者が思うよりも良好なスコアがでる傾向にあった。

【考察】スコアリングについては今後のアルゴリズムの変更にてアップデートを行なう予定である。患者のアプリ利用はスムーズであり、顔面神経麻痺のリハビリテーションの現場がかかえる問題を解決する可能性が示唆された。

一般演題 (口演) | 一般演題 5 (皮弁・マイクロサージャリー)

J94

3 次元 CG 画像生成ソフトウェア Viewtify

古谷 春乃 (ふるたに はるの)、加藤 基、南雲 英実、亀山 和稔、内田 達也、松本 洋

岡山大学病院 形成外科

【はじめに】穿通枝皮弁の挙上において、その栄養血管および穿通枝の走行を術前に把握することは手術の安全性を高める。造影 CT やその 3 次元構築画像を使用して評価を行うのが一般的となっているが、時間と手間がかかるのが難点である。対して 3 次元 CG 画像 (以下、3DCG) は、心臓手術を中心に近年注目される方法であり、術前評価の代用になりえるのではないかと考えた。

【目的】3DCG を用いた皮弁の血行評価法について現行の 3 次元画像と比較した有効性と課題を明らかにすることを目的とした。

【方法】2019 年から 2024 年の間に当科で DIEP flap を用いて乳房再建を施行した患者 20 名の皮弁穿通枝から本幹までの走行を 3DCG 生成ソフトウェア Viewtify® (株式会社サイアメント、日本) を使用して再評価した。実際に術前血管評価に使用した 3 次元解析画像と比較して、その正確性や作成の簡便さを評価した。

【結果】本システムを用いて深下腹壁動脈の筋肉内外の走行、穿通枝の立ち上がる場所や角度、複雑な解剖学的構造を詳細にとらえることが可能であった。術前評価に要した時間は 10 分程度と、現行の方法に対しても比較的短かった。また視認した血管走行についても高い整合性が得られた。一方で、画面操作および 3DCG 画面の長時間注視に若干の慣れを要した。

【考察】Viewtify® は CT や MRI の画像 DICOM データを瞬時に 3DCG に変換して可視化する新しいシステムであり、リアルタイムに任意の断面で画像を動かすことが可能である。また、裸眼立体視ディスプレイにも対応しており、3DCG を立体的に確認できるため立体構造を直感的に理解しやすい。これらの強みを活かして視覚的に、直感的に血行の走行を把握することができるため特に初学者においてより有用な手段であると考える。今後実際に術前の評価の一つとして使用することでその有用性を検討していきたい。

一般演題 (口演) | 最優秀一般演題セッション

J96

糖尿病難治性潰瘍マウスモデルに対するヒト脂肪組織常在性の血管内皮前駆細胞の
投与効果

齋藤 夏美 (さいとう なつみ)、戸代原 彬宏、玄 相詰、白土 タカ子、素輪 善弘、吉村 浩太郎

自治医科大学 医学部 形成外科学

【目的】 我々は、ヒト脂肪組織常在性の血管内皮前駆細胞 (Adipose-resident endothelial progenitor cells; AEPCs)を用いた血管新生再生医療の実現を目指している。これまでに、ヒト吸引脂肪から AEPCs を純化・培養する方法の確立 (Saito N., *et al.*, *Scientific Reports*, 2022)、および放射線障害性難治性潰瘍モデルに対する AEPC 投与による上皮化能の改善効果 (Mori M., *et al.*, *Plastic and Reconstructive Surgery*, 2024)を報告した。

本研究では、AEPCs の血管内皮前駆細胞 (EPC)としての特性 (血管新生能)を *in vitro* で維持しながら拡大培養する方法の確立、および糖尿病難治性潰瘍マウスモデルに対する創傷治癒能を検証する。

【方法】 AEPCs は純化直後に 3 条件の酸素濃度 (20%, 6%, 1%)環境で拡大培養し、細胞特性解析 (コロニー形成能、EPC マーカーの発現など)を実施した。

次に、ストレプトゾトシン誘導 1 型糖尿病 SCID マウスに難治性潰瘍を作製し、AEPCs、およびヒト脂肪幹細胞 (Adipose-derived stem cells; ASCs)を単独、ないし併用で投与した際の創傷治癒効果をコントロールと比較した。

【結果】 酸素濃度 3 条件では、1%酸素培養により EPC の特性を維持したまま拡大培養が可能であることが示唆された。さらに、AEPCs と ASCs 併用投与により、すでに知られている ASC 単独よりも創傷治癒能が改善することが示唆された。

【考察】 ASCs に加えて、AEPCs も臨床に利用可能な細胞源となりうることを示唆された。

Oral Presentation | Free paper (Nerve)

P02

Aligned core-shell fibrous nerve wrap containing Bletilla striata polysaccharide improves functional outcomes of peripheral nerve repair

Shih-Heng Chen

Dept. Plastic and Reconstructive Surgery, Chang Gung Memorial Hospital, Linkou, Taiwan

Background: Peripheral nerve injuries are commonly encountered in extremity traumas. Their motor and sensory recovery following microsurgical repair is limited by slow regeneration speed (<1 mm/d) and subsequent muscle atrophy, which are consequently correlated with the activity of local Schwann cells and efficacy of axon outgrowth.

Objective: To promote post-surgical nerve regeneration, we synthesized a nerve wrap consisting of an aligned polycaprolactone (PCL) fiber shell with a Bletilla striata polysaccharide (BSP) core (APB).

Methods: Material characterization including electromicroscopy and drug release were evaluated. *In vitro* studies included neurite outgrowth and Schwann cell activity assays. *In vivo* studies included the functional assessment of rat sciatic nerve transection/repair model as well as subsequent histology evaluation.

Results: Cell experiments demonstrated that the APB nerve wrap markedly promoted neurite outgrowth and Schwann cell migration and proliferation. Animal experiments applying a rat sciatic nerve repair model indicated that the APB nerve wrap restored conduction efficacy of the repaired nerve and the compound action potential as well as contraction force of the related leg muscles. Histology of the downstream nerves disclosed significantly higher fascicle diameter and myelin thickness with the APB nerve wrap compared to those without BSP.

Conclusion: The BSP-loaded nerve wrap is potentially beneficial for the functional recovery after peripheral nerve repair and offers sustained targeted release of a natural polysaccharide with good bioactivity.

P05**Evaluating the Impact of Facial Feminization Surgery on Transgender and Gender Non-Conforming Individuals: A Prospective Cohort Study**

Antoinette Nguyen, Clinton Morrison

University of Rochester School of Medicine

Introduction: Facial feminization surgery (FFS) encompasses a suite of cosmetic and reconstructive procedures aimed at altering masculine facial features to align more closely with societal perceptions of femininity. These procedures can include, but are not limited to, forehead contouring, jaw and chin reshaping, rhinoplasty, and Adam's apple reduction. The significance of FFS extends beyond the realm of aesthetic surgery, as it plays a critical role in the gender transition process for many transgender women and gender non-conforming individuals. The desire for facial feminization stems not only from the pursuit of personal identity alignment but also from the need to be socially recognized in their affirmed gender, which can significantly impact psychological well-being and social integration. Despite the crucial role of FFS in gender-affirming care, there exists a notable gap in the literature regarding quantitative assessments of its outcomes. This study aimed to evaluate the impact of FFS on transgender and gender non-conforming individuals using a novel quantitative metric, the Facial Feminization Outcome Score (FFOS).

Methods: In this prospective cohort study, 19 participants undergoing FFS between January 2023 and December 2023 were enrolled. The FFOS, which includes assessments of psychological well-being, social integration, and satisfaction with facial aesthetics, was calculated preoperatively, and at 6 months postoperatively. Scores ranged from 0 (worst outcome) to 100 (best outcome). Changes in FFOS over time were analyzed using paired t-tests and linear regression models to identify predictors of outcome improvement.

Results: The mean preoperative FFOS was 40 (SD = 15), indicating moderate dissatisfaction with facial aesthetics and its psychosocial impact. At 6 months postoperatively, the mean FFOS increased significantly to 70 (SD = 10) ($p < 0.05$), with further improvement to 75 (SD = 9) by 12 months ($p < 0.05$ compared to preoperative score). Notably, improvements in psychological well-being and social integration contributed most to the increase in FFOS. Younger participants and those with higher preoperative self-esteem experienced more significant improvements. The complication rate was 10%, predominantly consisting of minor complications that did not require surgical revision.

Conclusion: FFS significantly enhances facial aesthetics, psychological well-being, and social integration for transgender and gender non-conforming individuals, as demonstrated by marked improvements in the FFOS. The study highlights the transformative potential of FFS within the spectrum of gender-affirming care and emphasizes the necessity for standardized outcome measures to evaluate and improve surgical practices comprehensively.

Oral Presentation | Free paper (Breast)

P06

Non-invasive visualization of the midline-crossing arterial variation in the deep inferior epigastric artery perforator flap using photoacoustic tomography

Itaru Tsuge¹, Susumu Saito¹, Maria Chiara Munisso¹, Ayako Takaya¹, Chang Liu², Goshiro Yamamoto², Naoki Morimoto¹

¹ Department of Plastic and Reconstructive Surgery, Graduate School of Medicine, Kyoto University

² Department of Medical Informatics, Graduate School of Medicine, Kyoto University

Background: The importance of the subcutaneous arterial network crossing the midline in transverse abdominal flaps has been reported. Photoacoustic tomography can be used to noninvasively visualize subcutaneous vascular networks.

Objective: We applied this novel technology preoperatively in patients undergoing breast reconstruction to detect individual variations in the midline-crossing arteries.

Methods: Six patients scheduled to undergo breast reconstruction using free deep inferior epigastric artery perforator flaps were examined. Each scan of the 12×8-cm region took approximately 8 min. The accuracy of the tentative arteries evaluation defined by photoacoustic tomography was compared with the arterial phase detected by intraoperative indocyanine green angiography. The number of perforator vessels used for the flap, surgical time for flap elevation, and perfusion area ratio were compared with those of the control group.

Results: The average match rate between tentative arteries prediction by photoacoustic tomography and arterial-phase assessment by intraoperative angiography in 5 patients was 81.1%. Each midline crossing artery showed individual variations. The photoacoustic tomography group (PAT-1 to 5) showed 1.8 perforators per flap, 163 minutes for flap elevation, and 93% perfusion area, with no significant differences from the control group (N=5). A 63-year-old woman (PAT-6) with abdominal scars, including a midline abdominal incision, showed a preserved midline crossing artery. The planned single perforator deep inferior epigastric perforator flap was successfully applied.

Conclusion: Photoacoustic tomography noninvasively visualizes the subcutaneous midline-crossing arterial networks. Understanding individual vascular variations can support preoperative planning and surgical indication of abdominal flaps, especially in patients with postsurgical scars.

Oral Presentation | Free paper (Craniofacial/ Others)

P07

Real-time navigation for thinning of anterolateral thigh flap using photoacoustic imaging and projection mapping

Itaru Tsuge¹, Susumu Saito¹, Maria Chiara Munisso¹, Ayako Takaya¹, Chang Liu², Goshiro Yamamoto², Naoki Morimoto¹

¹ Department of Plastic and Reconstructive Surgery, Graduate School of Medicine, Kyoto University

² Department of Medical Informatics, Graduate School of Medicine, Kyoto University

Background: Thinning of anterolateral thigh flaps is challenging. An anatomical study showed variations in arterial branching patterns in the subcutaneous layer, which was suspected to be the reason for the high frequent thinning failures. The microdissection procedure is the only way to make the primary thinning procedure safer; however, its performance is not widespread due to its complexity and the risk of flap necrosis. Photoacoustic tomography noninvasively visualizes the subcutaneous vascular network.

Objective: We report the challenge of fusion with a real-time projection system, which enables real-time surgical navigation using indocyanine green emission signals, to make the flap thinning procedure more applicable.

Methods: A 69-year-old woman underwent half-tongue resection using the pull-through method for right tongue cancer. Preoperative photoacoustic imaging showed tentative arteries and veins using the S-factor, an approximate value correlated with hemoglobin oxygen saturation, by switching pulse-to-pulse wavelengths of 756 and 797 nm. PAT imaging was performed five days before the surgery. A 12×6-cm area took approximately 8 min. We used an indocyanine green test card cut into strips to show tentative artery lines by projection mapping. The transparent vascular map was laminated and sterilized.

Results: Medical imaging projection system captured the ICG fluorescence signals that penetrated the anterolateral thigh flap and continuously projected the purple area, guiding the position of the tentative subcutaneous arteries. Active bleeding was observed when we cut the marginal fat tissue near the projected purple line.

Conclusion: The fusion of photoacoustic tomography and real-time projection mapping is another innovation in navigational flap surgery.

Oral Presentation | Free paper (Skin/Burn/Wound Healing 1)

P09

Chilling in the Tropics: Management and Outcome of a Frostbite injury secondary to Refrigerant Burn, a case report

Lionico A Marquez, Jeffrey M Rafael, Karlo Capellan, Alexandra Tan-Gayos

Rizal Medical Center

Background: This case report highlights the course of an injury rarely encountered in a tropical country, attained through unusual means.

Objective: This paper aims to describe the course and management of a frostbite injury that is rarely encountered in the country. This paper also aims to provide information to aid in future management of similar injuries.

Methods: We are presented with a 32-year-old male, air-conditioning technician who came into the ER with a chief complaint of blisters over the left hand, after patient had direct exposure to refrigerant fluid. Patient arrived at our institution 1 hour post injury, where immediate debridement and dressing with silver sulfadiazine and moist to dry dressing was done. Patient was admitted and managed as a case of burn injury, by daily wound monitoring, cleaning and dressing, and provision of adequate pain control.

Results: Patient was sent home well with close follow ups at the out-patient department.

Conclusion: We are presented with a case of a cryogenic refrigerant injury who was seen and managed in a tertiary institution in the Philippines. Patient was treated from time of injury to 35 days post injury, or from time of disability to time of return to full functionality of affected limb.

Oral Presentation | Free paper (Breast)

P10

A RARE ENCOUNTER: BREAST IMPLANT CAPSULAR CONTRACTURE IMMEDIATELY PRECEDED BY HERPES ZOSTER, A CASE REPORT

Jeffrey M Rafael, Lionico A Marquez, Karlo Capellan, Alexandra Tan-Gayos

Rizal Medical Center

Background: This case report documents a rare occurrence of a patient presenting with a grade IV breast implant capsular contracture which is preceded by a herpes zoster infection affecting the post-operative site.

Objective: This case report investigates a rare case of periprosthetic herpes zoster infection potentially contributing to the development of grade IV capsular contracture in a breast implant recipient.

Methods: We present an 80-year-old female, initially diagnosed with varicella during her teenager years, who was complaining of pain from both postherpetic neuralgia and breast implant capsular contracture. Patient underwent breast implant explantation with partial capsulectomy. Specimens were sent for gram stain, culture studies and for histopathologic assessment to rule out infection and malignancy.

Results: Microbiological analysis of explanted tissues and fluids revealed no bacterial growth. Histopathological examination confirmed benign findings with no evidence of malignancy. The patient's post-operative course was uneventful and was discharged on post-operative day three. At follow-up visits, patient reported complete resolution of pain associated with both capsular contracture and postherpetic neuralgia and a fully epithelialized post-operative site.

Conclusion: Patient was managed promptly by removal of the breast implant and capsule to rule out possible infection and the possibility of an implant associated malignancy. Patient's main concern of pain, caused by the implant and as a sequela of the Herpes Zoster, was addressed and resolved according to the patient. This case report stresses the attention on this rare occurrence between herpes zoster infection and breast implant capsular contracture as management requires early diagnosis and prompt treatment.

Oral Presentation | Free paper (Regenerative medicine)

P11**Clinical study on autologous concentrated growth factors promoting skin regeneration**

Shuang-Bai Zhou, Poh-Ching Tan, Yun Xie, Qing-Feng Li

Shanghai Jiao Tong University School of Medicine, Shanghai Ninth People's Hospital

Background: Skin repair and regeneration are important issues in plastic surgery. Autologous Concentrated Growth Factor (CGF), a product containing multiple growth factors, may have the effect of promoting skin regeneration.

Objective: To evaluate the role of CGF in promoting tension-induced skin regeneration and promoting hair growth.

Methods: The authors conducted a serial studies to evaluate the efficiency of autologous concentrated growth factor (CGF) in promoting skin regeneration and hair follicle growth. (1) A single-center randomized controlled trial was conducted from 2016 to 2019. Participants undergoing skin expansion received either CGF or saline by means of intradermal injection on the expanded skin (0.02 mL/cm²), for a total of three treatments at 4-week intervals. The primary endpoint was the expanded skin thickness at 12 weeks, which was measured by ultrasound. (2) A double-blinded within-subjects randomized clinical trial was conducted on 16 male AGA patients who showed limited improvement after MXD treatment. Eligible participants received three CGF injections on half of the scalp and the placebo on the other side at 4-week intervals, and MXD was applied twice daily on both sides throughout the follow-up period. The primary endpoint was the hair growth ratio at V4.

Results: (1) In the RCT study of CGF treating expanded skin, 26 patients were enrolled and assigned to the CGF or control group. Compared with the control group, the CGF group had significantly increased skin thickness at 8 and 12 weeks. Compared with the baseline thickness, skin thickness was sustained in the CGF group at 8 weeks after treatment (−0.1 to 0.3 mm; $P = 0.711$) but decreased in the control group (0.3 to 0.7 mm; $P < 0.001$). At 12 weeks, the CGF group showed greater increases in surface area (control, 77.7 ± 18.5 cm²; CGF, 135.0 ± 15.7 cm²; 7.2 cm² to 107.4 cm²; $P = 0.027$). (2) In the trial of CGF treating AGA, each half of the scalp was randomly assigned to the MXD+CGF or MXD group. The MXD+CGF group had significant improvements in hair density, HG ratio, and T/V ratio compared with the MXD group over the follow-up period. Unexpectedly, the MXD+CGF treatment hastened HG, which was sustained for 3 months after discontinuation.

Conclusion: The findings of these studies indicate that it is practically feasible to improve skin regeneration and hair growth by applying autologous platelet concentrate therapy.

Oral Presentation | IPSRC Best paper session

P12**Development of Automated Assessment and Classification of Open Wound using Deep Learning Approaches**Yi-Syuan Shin¹, Chia-Ling Wu², Yu-Lin Chen², Shyh-Hau Wang², Yuan-Yu Hsueh¹¹ Department of Plastic and Reconstructive Surgery, National Cheng Kung University Hospital² Department of Computer Science and Information Engineering, National Cheng Kung University**Background:**

Wound care has long been a critical issue, with the advanced wound care market expected to exceed \$22 billion by 2024. Chronic wounds in elderly or diabetic patients necessitate prolonged monitoring. However, frequent visits to medical facilities can be burdensome, reducing patients' willingness to seek medical care, especially in the pandemic era. This reluctance can impede timely wound assessments, leading to delayed treatment and potentially worsening conditions. Moreover, effective wound assessment heavily relies on the experience of healthcare professionals, making it challenging and time-consuming to accurately evaluate wound conditions in critical cases.

Objective:

To develop a method for image-based automated wound assessment and tissue type classification.

Methods:

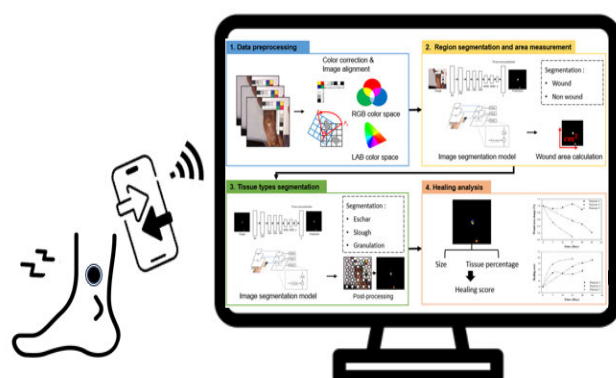
A dataset of 1,608 images was utilized, applying specific preprocessing techniques such as distortion correction, color calibration, color space transformation, denoising, and color space reduction. Four deep learning models were compared for wound and tissue segmentation.

Results:

The Feature Pyramid Network (FPN) model demonstrated superior accuracy in both tasks. In wound segmentation, the Intersection over Union (IoU) and Dice coefficient were 88.13% and 92.72% respectively. While in tissue segmentation, the IoU and Dice coefficient were 76.72% and 82.13% respectively. The analysis of wound images was completed in approximately 4 seconds.

Conclusion:

This system enables efficient real-time wound assessment by automatically calculating the wound area and tissue percentage to determine a healing score. This score evaluates wound healing status and the need for medical intervention.



Summary graphic: Our method provides efficient, real-time automated wound assessment and tissue type classification once the images of wound are captured.

Oral Presentation | Free paper (Nerve)

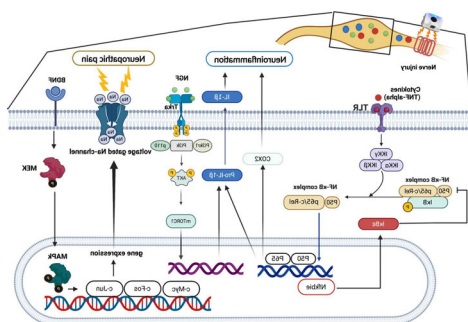
P13**Application of ultrahigh frequency transcutaneous electrical nerve stimulation for alleviation of neuropathic pain and neuroinflammation modulation in rat sciatic nerve chronic constriction injury**YU-WEN LIN¹, Szu-Han Chen¹, Wan-Ling Tseng¹, Wei-Tso Lin², Sheng-Che Lin³¹ National Cheng Kung University Hospital² Gimer Medical Co., Ltd, New Taipei City, Taiwan³ An-Nan Hospital, China Medical University

Background: A challenging complication in patients with peripheral compressive neuropathy is neuropathic pain. Excessive neuroinflammation and pain-related neuropeptide accumulation at the nerve injury site contribute to exaggerated neuropathic pain and functional loss. Currently, physical therapy such as transcutaneous electrical nerve stimulation (TENS) has demonstrated therapeutic potential, providing noninvasive and promising outcomes. However, the underlying regulatory mechanism remains unexplored. **Objective:** This study aimed to validate the therapeutic effect of ultrahigh frequency (UHF)-TENS in chronic constriction injury of adult rat sciatic nerve.

Methods: For therapeutic effect, Von Frey test was used to evaluate behavioral responses. Pain-related neuropeptide and inflammatory signals were analyzed in the injured site dorsal root ganglion (DRG) neurons through immunofluorescent staining. Furthermore, to explore the regulating molecular mechanisms, gene expression profile of neuroinflammatory pathways were investigated using RNA sequencing.

Results: Mechanical allodynia was alleviated through the application of UHF-TENS, which lasted for 3 days for a one-session therapy, without additional damage on the myelinated axon structure. Significant reduction of pain-related neuropeptide and inflammatory signals were observed in injured DRG neurons. RNA sequencing of differential gene expression of the sensory neurons revealed a significant downregulation in lipid and carbohydrate metabolism, autophagy, and NF- κ B pathway.

Conclusion: UHF-TENS provided a promising outcome for effectively and safely alleviating neuropathic pain. The decreased production of pain-related neuropeptide and inflammatory signals within the DRG neurons provided the therapeutic benefit. Possible molecular mechanisms by UHF-TENS might result from the modulation of the NF- κ B complex, toll-like receptor-7, and phosphoinositide 3-kinase/Akt signaling in sensory neurons.



P14**Research on the Optimization and Evaluation of an Autofluorescence Point-of-Care Device for Bacterial Species Identification**Daisuke Mito^{1,2}, Hideo Eda¹, Shin-ichiro Okihara¹, Masakazu Kurita³, Nami Hatayama⁴, Yusuke Yoshino⁴, Yoshinobu Watanabe², Katsuhiko Ishii¹¹ The Graduate School for the Creation of New Photonics Industries² Trauma and Reconstruction Center, Teikyo University Hospital³ Department of Plastic and Reconstructive Surgery, the University of Tokyo Hospital⁴ School of Medicine, Department of Microbiology and Immunology, Teikyo University

Background Rapid identification of bacterial species is essential for effective treatment of infectious diseases. Especially after surgical debridement of soft tissue infections, the species and antimicrobial susceptibilities need to be known as quickly as possible in order to use antimicrobials of the necessary and sufficient spectrum coverage. Conventional methods are accurate but time-consuming and require extensive sample preparation and specialised equipment.

Objective To develop a new point-of-care instrument for bacterial species identification using fluorescence spectroscopy based on autofluorescence, to evaluate the accuracy of bacterial species diagnosis using machine learning, and to discuss the instrument-loading requirements for this purpose.

Materials & Methods Autofluorescence of 10 clinically relevant bacterial strains was analysed using fluorescence spectroscopy. The diagnostic accuracy of varying the number and combination of excitation wavelengths was analysed using a machine-learning classification algorithm, and the optimal wavelengths were investigated using Bayesian optimisation.

Results There was general agreement between the algorithms on the optimal wavelength and number of wavelengths for bacterial species diagnosis. Autofluorescence spectra from approximately three or more wavelengths in the UV region gave diagnostic accuracy of more than 98.5%, which is equivalent to an exhaustive examination of all wavelengths.

Conclusions The results show that bacterial species may be accurately identified by measuring only a few key excitation wavelengths. This may create a rapid and cost-effective test method suitable for clinical diagnosis.

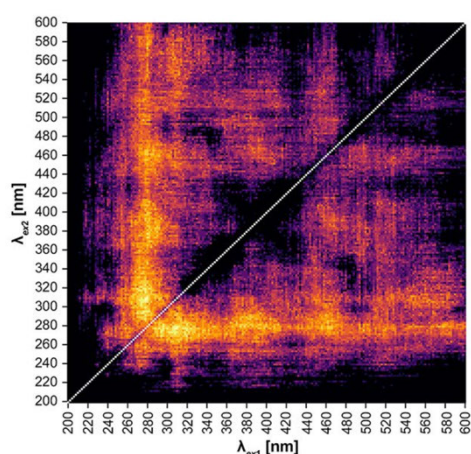


Figure 1 Distribution of diagnostic accuracy for each combination of two excitation wavelengths for each algorithm. The diagnostic accuracy of the bacteria species is pseudo-colored in the range from 0.9 to 0.99.

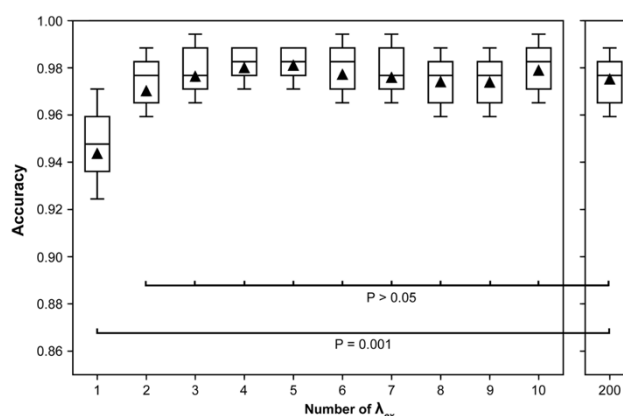


Figure 2 Change in the diagnostic accuracy for each number of excitation wavelengths. The best combination of 1 to 10 excitation wavelengths (left frame) and the use of all 200 excitation wavelengths (right frame) were compared when sample data were randomly cross-validated. The top of the box is 75%, the bottom is 25%, the horizontal line in the box is the median, and the triangle in the box is the mean. The P-values from the Dwass-Steel-Critchlow-Fligner (DSCF) test are listed at the bottom of the graph.

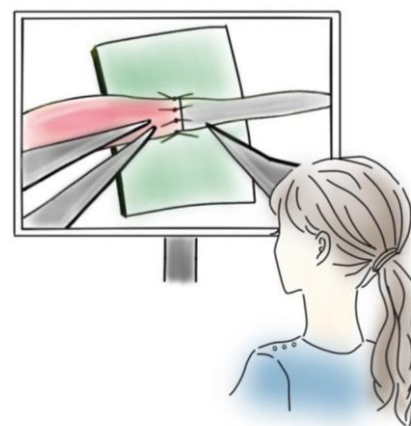
P15**Super Microsurgical Education Using Papers with Online Video Clips**

Satoshi Onoda, Kahori Tsukura, Kohta Kobayashi, Toshihiko Satake

Department of Plastic and Reconstructive, Aesthetic Surgery, Toyama University Hospital

Purpose

With the recent development of surgical microscopes and surgical instruments, as well as the widespread use of surgical treatments such as lymphatic venous anastomosis for lymphedema, opportunities for anastomosis of blood vessels and vascular vessels smaller than 1 mm have increased exponentially. In this presentation, the advantages of surgical technique education of super-microsurgery using papers with online video clips are reported.

**Methods**

In super-microsurgery, such as lymphaticovenular anastomosis, the diameter of the target vessel is small and difficult to handle, and the basic surgical technique of microsurgery, such as inserting a forceps into the lumen and applying a counter, is difficult. The most effective way to learn such super microsurgical techniques is for skilled surgeons to teach them to novices.

Results

We reported a paper (*Onoda S et al. J Vasc Surg Venous Lymphat Disord. 2023*) presenting super-micro surgical techniques for LVA in video format and have used it for surgical education. The advantages of viewing surgical procedures on video include being able to view them anywhere, the ability to view them many times, and the ability to zoom in on the detail. Other articles with surgical video clips with various situations of super-microsurgery are already published.

Discussion

Only a few surgeons are familiar with super microsurgical techniques, and in many cases, there are no surgeons in or near their own institutions. Since super-microsurgery is more dependent on the surgeon's senses than on verbal explanations, image training using videos is even more critical.

P16**Mechanical stretching can modify the papillary dermis pattern and papillary fibroblast characteristics during skin regeneration**

Poh-ching Tan, Shuang-bai Zhou, Qing-Feng Li

Department of Plastic & Reconstructive Surgery, Shanghai Ninth People's Hospital, Shanghai Jiao Tong University School of Medicine

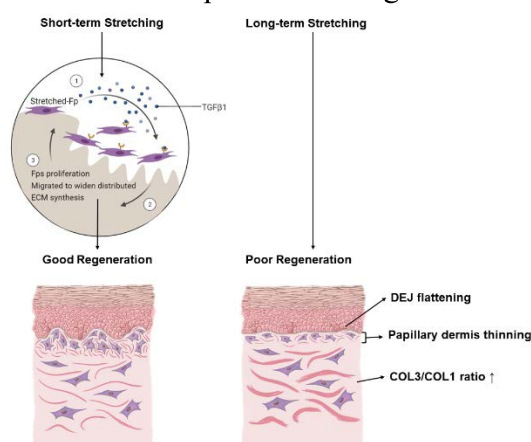
Background: The clinical use of mechanical stretching for skin repair is well-documented, yet its impact on specific fibroblast subpopulations remains unclear.

Objective: This study focused on evaluating changes in dermal structure and papillary fibroblasts (Fp) in regenerated human skin following skin expansion procedures.

Methods: Human regenerated skin samples were categorized into well-regenerated and poorly-regenerated groups based on observations, with histological verification of dermal extracellular matrix (ECM) deposition. Immunohistochemical analysis stained Fp and other lineage markers. By establishing a rat skin expansion model, researchers investigated ECM and Fp alterations in the papillary dermis through histological and molecular evaluations.

Results: Exhausted skin regeneration caused dermal-epidermal junction (DEJ) flattening, papillary dermis thinning, and an increase in the type III collagen (COL3)/type I collagen (COL1) ratio with upregulated hallmarks of aging. Well-regenerated skin displayed a notable increase in the Fp population. These findings aligned with the rat model, where upregulated TGF β 1 notably distinguished well-regenerated skin. Activation of the TGF β 1/Smad2/3 pathway improved exhausted skin regeneration and resulted in increased collagen content and Fp proliferation, while pharmacological inhibition of TGF β 1 action impacted well-regenerated skin. Short-term mechanical stretching that promoted skin regeneration enhanced Fp proliferation, extracellular matrix (ECM) synthesis, and increased TGF β 1 expression, leading to good regeneration.

Conclusion: This work shows the mechanism of mechanical stretching in well skin regeneration that enhances Fp proliferation and ECM synthesis via the TGF β 1/Smad2/3 pathway, and highlights a crucial role of Fps in stretching-induced skin regeneration. (Word count:250)



Oral Presentation | IPSRC APRAS award session 2

P17

Therapeutic Potential of Follicular Epithelial Cells Derived from Different Portions of Hair Follicle for Wound Healing and Epithelization

Bihang Zhang, Kotaro Yoshimura, Natsumi Saito, Yunyan Wu, Takako Shirado, Yoshihiro Toyohara, Bolun Li, Yoshihiro Sowa

Jichi Medical University

Background: Human hair follicle is consistent of epithelial stem cells, progenitor cells and various lineages of keratinocytes. It was presented that the different portions of human hair follicle showed different patterns of biomarker expressions.

Objective: This study investigated the therapeutic potential of follicular epithelial cells (FECs) derived from different portions of hair follicle for wound healing and epithelization.

Methods: A novel method was developed to isolate FECs from different regions of hair follicles: the upper and lower outer root sheath and the bulb epithelial cells, designated as UECs, LECs, and BECs, respectively. Proliferative capacities and biomarker expressions of cultured FECs were assessed, comparing them with epidermal epithelial cells (EECs). *In vivo* wound healing and epithelialization were evaluated using an immunodeficient NOD-SCID mouse model following topical treatment with each cell population. Histological analyses were conducted on the healed skin samples. Additionally, hair regeneration was examined after sacrificing the bulb of rat whiskers to evaluate clinical donor site deficits.

Results: BECs exhibited the highest proliferative capacity and contained the fewest differentiated CK10+ epithelial cells compared to other populations. All cell-treated groups, including FECs and EECs, demonstrated positive effects on wound healing and epithelization *in vivo* compared to the vehicle-treated control group, with the BEC-treated group showing superior outcomes. Histological examination revealed thinner and smaller scar areas and a greater number of surviving human-derived cells localized in the regenerated epidermis in the BEC-treated group. In the rat model, whiskers and follicles regenerated 2 months after bulb removal, albeit thinner and shorter.

Conclusion: Human scalp hair follicle-derived epithelial cells, particularly BECs, hold promise as therapeutic agents for promoting epithelialization due to their high proliferation and engraftment capacities. Minimal donor site damage was observed after sacrificing the follicular bulb, suggesting negligible hair loss.

Oral Presentation | Free paper (Aesthetic/ Gender/ Cancer)

P18

**Subfascial breast augmentation in transfemale patient:
A report of cases**

Jinho Lee

AB Plastic Surgery Clinic, Seoul, Korea

Background: Breast augmentation is an important part of gender-affirming surgery. One of the key decision in breast augmentation in trans-female patient is in which plane to insert the implant. A commonly cited disadvantage of subpectoral plane is animation deformity and implant displacement. Because of the relatively larger pectoralis muscle, subglandular augmentation was the most preferred option in transfemale patient throughout the past decade. However, dual-plane subpectoral pocket is also a useful plane, especially in thin patient without adequate soft-tissue. Subglandular plane and dual plane has its own advantages and drawbacks. Subfascial plane offers several advantages over these two techniques.

Objective: Focusing on the selection of pocket, the author sought to develop an ideal approach.

Methods: A retrospective chart review of patients for gender-affirming augmentation mammoplasty between 2020 and 2024 was performed. Seven Cases of gender-affirming breast augmentation surgery were performed. Patients assessments and outcomes were analyzed.

Results: Seven transfemale patients underwent augmentation mammoplasty. Three patients underwent with dual plane subpectoral pocket and four with subfascial pocket. One patient with dual plane pocket developed postoperative discomfort and animation deformity. The remaining six had favorable outcomes with smooth recovery. All patients were generally satisfied with the outcome.

Conclusion: There are significant anatomic differences is between cis-female and trans-female patient. Undoubtedly, selection of proper pocket plane is a key decision in trans-female breast augmentation. Considering all possible disadvantages of subglandular and dual-plane subpectoral technique, subfascial plane can be the primary option in transfemale patient who undergo breast augmentation. As the sample size is small, further investigation is needed.

Oral Presentation | Free paper (Skin/ Burn/ Wound Healing 1)

P19

The m6A-RNA epitranscriptomic pathway-pharmacological targeting of METTL3 to inhibit scarring.

Mayu Hosio^{1,2}, Mizuno Hiroshi¹, Esko Kankuri²

¹ Department of Plastic and Reconstructive Surgery, Juntendo University School of Medicine, Tokyo, Japan

² Faculty of Medicine, Department of Pharmacology, University of Helsinki, Helsinki, Finland

Background: Scar formation is a significant clinical challenge with negative aesthetic and functional impacts. N6-methyladenosine (m6A) RNA modifications, which are reversible and the most dominant epitranscriptomic modifications on RNA, contribute to the regulation of wound healing and scarring pathways.

Objective: We aim to investigate the role of m6A RNA modification in scar formation by targeting the methyltransferase METTL3 complex with small-molecule inhibitors and activators. Our objective is to identify potential therapeutic interventions for scar management.

Methods: Firstly, we review current literature on m6A and scar formation, focusing on its impact on gene expression, fibroblast activation, inflammation, and angiogenesis. Secondly, we propose a pharmacological approach involving the use of METTL3 inhibitors and activators to modulate m6A levels and assess their effects on scar formation in preclinical models.

Results: By targetedly altering m6A modification levels during scar formation, we anticipate that inhibiting METTL3 may attenuate scar formation by suppressing fibroblast activation, ECM deposition, inflammation. Conversely, activating METTL3 may promote scar resolution by enhancing wound healing.

Conclusion: Our study will elucidate the potential of pharmacologically targeting METTL3 as a novel therapeutic strategy for scar management. Future research should focus on elucidating the specific mechanisms underlying the effects of METTL3 modulation on scar formation, optimizing the pharmacological properties of METTL3 inhibitors and activators, and evaluating their efficacy and safety in preclinical and clinical settings. Overall, targeting METTL3-mediated m6A RNA modification holds promise for the development of innovative therapies for scar treatment.

P20

Therapeutic effects of high fluence light emitting diode-red light on burn hypertrophic scars

Kuo-Shu Hung¹, Po-Liang Ou²

¹ Division of Plastic and Reconstructive Surgery, Department of Surgery, National Cheng Kung University Hospital, College of Medicine, National Cheng Kung University

² School of Medicine, College of Medicine, National Cheng Kung University

Background:

Hypertrophic scars (HS) pose a significant challenge for burn patients post-healing, affecting around 70% of cases and causing pain, itching, and disfigurement, impacting quality of life. Common self-management methods like scar massage and silicone-based products often fall short in efficacy. Medical interventions such as corticosteroid injections, fat transfer, and laser therapy, while effective, require physician oversight and are invasive. Light emitting diodes, proven effective for acne and photoaging, hold promise for HS treatment. Red light, with a wavelength of 610 to 760 nm, can penetrate the dermal layer, inhibiting fibroblast proliferation in vitro without affecting survival, suggesting potential for HS treatment. However, clinical trials have yielded varied therapeutic outcomes, necessitating further research.

Objective:

To evaluate the therapeutic effects of high fluence light emitting diodes-red light (HF-LED-RL) on rat burn hypertrophic scar model.

Methods:

A rat paw burn wound model was established using a heated metal block. Complete wound healing with hypertrophic scar formation occurred within three weeks. HF-LED-RL therapy, administered for three weeks at varying treatment durations, was implemented. Following treatment completion, scar tissue and the paw of the contralateral hindlimb (as normal skin tissue) were collected for scar assessment, which encompassed histological analysis and protein analysis.

Results:

H&E staining showed a reduced scar elevation index in the HF-LED-RL treatment group. Masson's trichrome staining demonstrated decreased collagen fiber density in the treatment group. Western blot analysis revealed lower levels of both Vimentin and alpha-SMA in the treatment group.

Conclusion:

HF-LED-RL can improve burn hypertrophic scars in rat models.

P21**Characterization of vasospasm in femoral arteries of arteriosclerotic model rats: Induction of vasospasm and negative effect of the vasodilator treatment on the spasm releasing**

Yuki Matsuoka¹, Michika Fukui¹, Masakatsu Hihara¹, Toshihito Mitsui¹, Ryo Karakawa²

¹ Department of Plastic and Reconstructive Surgery, Kansai Medical University

² Department of Plastic and Reconstructive Surgery, Cancer Institute Hospital of the Japanese Foundation for Cancer Research

Background

Vasospasm characterized by abnormal vasoconstriction is one of the difficult problems and remains a direct cause of flap loss, but the relationship between vasospasm and arteriosclerosis has not been known. The objective of this study was to establish an animal model of arteriosclerosis for assessing vasospasm, and to clarify the relationship between arteriosclerosis and vasospasm.

Methods

Twelve-week-old male Sprague–Dawley rats were fed a diet supplemented with adenine and vitamin D (adenine/vitD). Body weight, blood, and femoral artery histopathology were assessed at 2, 4, and 6 weeks. Change in the femoral artery was examined by transmission electron microscope (TEM). Vasospasm was induced by administering epinephrine extravascularly into the femoral artery and released by the treatment with lidocaine as a vasodilator. During this period, the extravascular diameter and blood flow were measured.

Results

The rats in the adenine/vitD group developed renal dysfunction, uremia, hyperphosphatemia, and elevated serum alkaline phosphatase. Histological and TEM analyses of the femoral arteries in the treated rats revealed the degeneration of elastic fibers and extensive calcification of the tunica media and intima. Vascular smooth muscles were degenerated and osteoblasts were developed, resulting in calcified arteriosclerosis. Vasospasm in arteriosclerotic arteries was detected; however, vasodilation as well as an increase in the blood flow was not observed.

Conclusions

This study revealed the development of vasospasm in the femoral arteries of the arteriosclerotic rats and, a conventional vasodilator did not release the vasospasm.

E-poster

P22**Minimum Number of Sutures for Microvascular Anastomosis during Replantation**

Hyungsuk Yi, Byeong Seok Kim, Yoon Soo Kim, Jin Hyung Kim, Hong Il Kim

Department of Plastic and Reconstructive Surgery, Kosin University College of Medicine

Background: Microvascular anastomosis is crucial for successful replantation, yet it faces challenges with smaller vessels, where increased suture number can impede reperfusion.

Objective: To assess whether a reduced suture number using a 2-point suture technique can enhance reperfusion and survival rates in microvascular anastomoses during replantation.

Methods: We retrospectively reviewed medical records from January 2017 to December 2021 for patients who underwent replantation involving vessels smaller than 0.3 mm in diameter. We compared outcomes between cases utilizing traditional suture techniques (three or four sutures) and those using a 2-point suture technique.

Results: Of the 21 cases reviewed, 19 replantations were successful. The 2-point technique was used in 12 cases, with 11 successful outcomes. Traditional suturing was applied in nine cases, with eight successes. Survival rates were slightly higher in the 2-point group, and fewer conversions to composite grafts were required compared to the traditional suture group.

Conclusion: The 2-point suture technique appears to offer a viable alternative to traditional methods, potentially increasing survival rates and decreasing the need for composite graft conversion in microvascular anastomosis during replantation. Further studies with larger sample sizes could validate these findings.

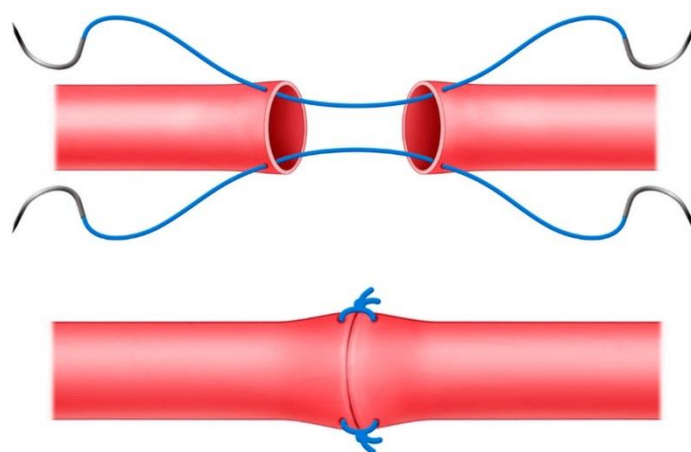


Figure 1. Schematic illustration of the 2-point suture technique.

Oral Presentation | Free paper (Skin/ Burn/ Wound Healing 1)

P23

Preliminary Elucidation of Generative Artificial Intelligence Chatbots in Interpreting Clinical Images of Pressure Injuries

Makoto Shiraishi, Koji Kanayama, Yuta Moriwaki, Daichi Kurita, Mutsumi Okazaki

Department of Plastic and Reconstructive Surgery, The University of Tokyo Hospital, Tokyo, Japan

Background: Since generative artificial intelligence (AI) has debuted in 2022, it greatly attract attention in many areas including medical fields. ChatGPT, one of the leading chatbots, released the model that can interpret the images in 2023.

Objective: To evaluate the accuracy of AI chatbots in staging pressure injuries through clinical image interpretation, we evaluated the potential usefulness of AI chatbots in staging pressure injuries using clinical images, which may be eventually helpful for early detection, facilitating subsequent treatment, and prevention of pressure injury deterioration.

Methods: A cross-sectional design was conducted to assess 5 leading publicly available AI chatbots. Mock images were downloaded and inputted into AI chatbots 10 times in November 2023. First, the scores in each session, from 0 to 10, were evaluated. Next, the accuracy in staging pressure injuries was compared for the 10 sessions.

Results: Among the 5 leading AI chatbots, only GPT-4 Turbo and BingAI Creative mode proceeded to the following study sessions. GPT-4 Turbo significantly outperformed BingAI in accuracy, especially in staging of pressure injuries. Overall, GPT-4 Turbo showed high accuracy across different stages, whereas, BingAI's performance was markedly lower as shown by t-test (83.0 % vs 24.0%; $P < .001$).

Conclusion: Among AI chatbots, GPT-4 Turbo was found to be highly effective in classifying pressure injuries, suggesting potential benefits in medical applications. Further advancement of AI chatbots along with increased amount of data input may aid in early detection and management of pressure injuries.

Oral Presentation | Free paper (Nerve)

P24

Adipose-derived stem cells via therapeutic modulation of neuroinflammation to recover peripheral compressive neuropathy

Stanley Szu han Chen^{1,2}, Yuan-Yu Hsueh^{1,2}

¹ Division of Plastic Surgery, Department of Surgery, National Cheng Kung University Hospital

² Institute of Clinical Medicine, National Cheng Kung University.

Background:

Compressive neuropathy is a common type of chronic traumatic injury for peripheral nerves. Clinical patients frequently present variable degrees of sensory and motor function impairments. To date, complete surgical decompression from the local compressive region remains the gold standard procedure. However, the surgical outcomes are unsatisfactory, with 10-25% of patients suffering from a recurrence of symptoms. In addition, sustained immune cells infiltration and overexpression of neuroinflammatory cytokine hinder nerve regeneration and functional recoveries. On the other hand, adipose-derived stem cells (ADSCs) have been shown tons of beneficial effects for neural regeneration, by neurotrophic and anti-inflammatory effects.

Objective

We hypothesize that local delivered ADSCs can promote neural regeneration and functional outcomes on severe compressive neuropathy via modulating local neuroinflammation.

Methods

We investigated the therapeutic outcome of ADSCs local therapy and neuroinflammation in our established animal models of compressive neuropathy. We verified the in vivo therapeutic effect of locally delivered ADSCs on a reproducible chronic constriction injury model, focusing on behavioral function, electrophysiology, and histological improvements.

Results

ADSCs improved the sensory and motor impairment of peripheral compressive neuropathy and promoted the electrophysiological neuromuscular system. Furthermore, in the histological finding, adipose-derived stem cells can facilitate axon remyelination and alleviate neuroinflammation after surgical decompression for the injured nerve.

Conclusion

For intractable compressive neuropathy patients, the immediate local delivery of adipose-derived stem cells might help to reduce symptom recurrence and promote functional recoveries via immunomodulation effect.

P25**Effects of Prophylactic Systemic Administration of Adipose Stem Cells on Late Radiation Skin Injury**

Yoshihiro Toyohara, Yoshihiro Sowa, Natsumi Saito, Takako Shirado,
Wu Yunyan, Zhang Bihang, Kotaro Yoshimura

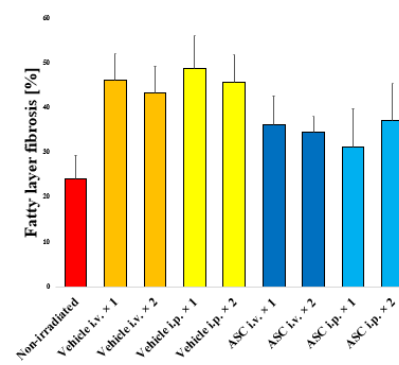
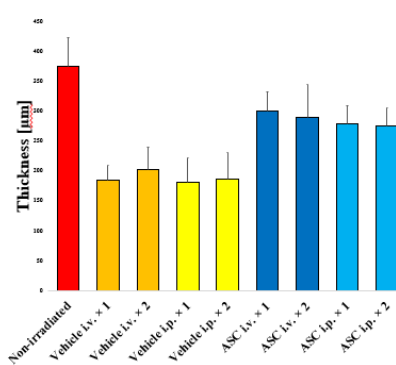
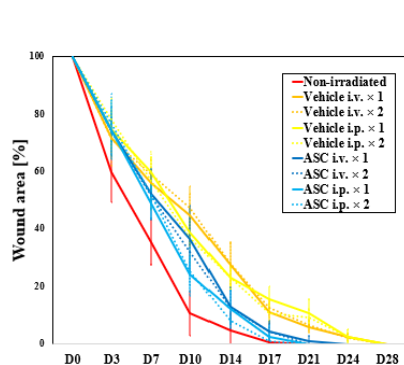
Jichi Medical University

Background: Radiation therapy is effective in inhibiting cancer cell growth, but has detrimental deterministic effects on normal tissue. Late radiation tissue effects that occur several months after irradiation include atrophy, fibrosis, and ischemia, which lead to delayed wound healing and intractable skin ulcers. Our previous studies have shown that prophylactic local administration of adipose-derived stem cells (ASCs) in combination with irradiation reduces late radiation disorders. For future clinical applications, this study investigated the effects of prophylactic systemic administration of ASCs on late radiation skin injury.

Methods: Nude mice were irradiated on the dorsal skin (total 40 Gy) and systemically administered with human ASCs (intravenous or intraperitoneal injection, once or twice). As control groups, a non-irradiated group and vehicle-treated irradiated groups were prepared. After 6 months, full-thickness skin wounds were created on the dorsal skin of the mice and observed for 28 days. Comparison of the wound healing process and immunohistological analysis of the tissues were performed.

Results: ASC-treated groups epithelialized faster than Vehicle-treated groups, although not as fast as Non-irradiated group (Fig.1). Histological analysis showed atrophy and fibrosis in the fat layer in Irradiated groups compared to Non-irradiated group, but these were suppressed in ASC-treated groups compared to Vehicle-treated groups (Fig.2 and 3). Engraftment of the injected ASCs was confirmed in the fat layer of some samples.

Conclusion: These results indicate that prophylactic systemic administration of ASCs in combination with irradiation can prevent delayed wound healing and histological damage.



Oral Presentation | Free paper (Aesthetic/ Gender/ Cancer)

P26**Effects of platelet-rich plasma with basic fibroblast growth factor on human adipose tissue**Tomoyuki Ito¹, Jin Zhengnan¹, Huang Guijuan¹, Rie Hirano³, Rika Tanaka^{1,2,3}, Hiroshi Mizuno^{1,2}¹ Department of Plastic and Reconstructive Surgery, Graduate School of Medicine, Juntendo University² Department of Plastic and Reconstructive Surgery, Juntendo University Hospital³ Division of Regenerative Therapy, Graduate School of Medicine, Juntendo University

Objective: Local injection of platelet-rich plasma (PRP) with basic fibroblast growth factor (bFGF) into subcutaneous fat is used for anti-aging in the cosmetic field. However, complications such as bulging in some patients receiving injections of PRP with bFGF have been reported and represent a serious problem in Japan. In this study, we evaluated the effects of PRP with bFGF on human adipose tissue in a murine model.

Methods: Subcutaneous fat tissue and peripheral blood were obtained from patients who underwent breast reconstruction with autologous tissue transfer and served for the subsequent experiment. 0.3 ml of the fat was injected into the dorsum of the 6-week-old female BALB mice, which mimic human subcutaneous fat. PRP was prepared from patients' peripheral blood followed by cryopreserved prior to use. 4 weeks after fat grafting, PRP, bFGF (1.67µg, 5µg, and 15µg), PRP with bFGF (1.67µg, 5µg and 15µg) and PBS were injected into the transplanted fat (n=9, each). Additional 4 weeks after administration, the specimens were harvested and served for histological and immunohistochemical analyses.

Results: PRP with bFGF (1.67µg and 5µg) group contributed to greater fat retention compared to other groups ($p < 0.05$). PRP with bFGF (5µg) and bFGF (1.67µg and 5µg) groups increased the expression of PPAR γ , a key transcription factor in adipogenesis ($p < 0.05$). However, fibrosis increased with increasing concentrations of bFGF ($p < 0.05$).

Conclusion: These findings suggest that the injection of PRP with low to moderate concentrations of bFGF may contribute to human adipose tissue maintenance or augmentation.

Oral Presentation | IPSRC Best paper session

P27

Mechano-induced arachidonic acid metabolism promotes keratinocyte proliferation during skin expansion

Shengzhou Shan, Jiahao He, Mengling Chang, Xusong Luo

Department of Plastic and Reconstructive Surgery Shanghai Ninth People's Hospital Shanghai Jiao Tong University School of Medicine

Background: Mechanical stretch induces keratinocyte proliferation and epidermal growth during skin expansion. Increased cell proliferation requires active metabolism of nutrients to produce more energy. However, how keratinocytes alter their metabolic profile to meet the energetic requirements in mechanical stretch-mediated skin expansion remains unclear.

Objective: To determine the cellular metabolic changes of keratinocytes during mechanical stretch-mediated skin expansion.

Methods: An in vitro Flexcell Tension system was used to stretch HaCaT cells. After stretching, HaCaT cells were examined by metabolomic analysis and molecular assays. An in vivo mechanical stretch-induced skin expansion model was established, and specimen of human expanded skin were used to verify the results of in vitro experiments.

Results: Here we showed that an enrichment for "Retrograde endocannabinoid signaling", which was the top-ranked signaling pathway in HaCaT cells after mechanical stretch, was observed. Moreover, the accumulation of the metabolic end-product arachidonic acid strongly suggested that mechanical stretch enhanced HaCaT cells proliferation through arachidonic acid anabolism. Supplementation of arachidonic acid could stimulate HaCaT cells proliferation in a dose-dependent manner. Furthermore, the study demonstrated the essential role of cytosolic phospholipase A2 (cPLA2) in arachidonic acid release as well as keratinocyte proliferation in mechanical stretch-mediated skin expansion.

Conclusion: Our data reveal a metabolic regulation mechanism by which mechanical stretch induces keratinocyte proliferation, thereby coupling cellular metabolism to the mechanics of the cellular microenvironment. The combination of mechanical stretch and metabolic regulation may contribute to the optimization of individualized skin expansion with high efficiency.

Fat Grafting for the Treatment of Velopharyngeal Insufficiency Secondary to Isolated and Syndromic Cleft Palate

Damian Palafox

Hospital Angeles Puebla

Background: While severe velopharyngeal insufficiency (VPI) can be treated with pharyngoplasty, retropharyngeal flap and other techniques, mild to moderate VPI cases can be treated with posterior pharyngeal wall augmentation.

Aim: To present the early experience with fat grafting for the treatment of mild to moderate VPI

Methods: Inclusion criteria: Mild to moderate VPI, patients with previous primary palatoplasty performed. All patients underwent videofluoroscopy to confirm diagnosis and classify VPI. Fat was not centrifuged but rather emulsified. Fat was injected into the posterior pharyngeal wall with a blunt canula (19 gauge), into the submucosal plane.

Results: Patients with mild to moderate VPI were considered for posterior pharyngeal wall augmentation by means of fat grafting. 10 patients underwent the procedure. 6 Male and 4 Female. Mean age: 11.9 years old. Mean Volume Injected: 5.2cc (range 3-7cc) Mean Follow up: 10.2 months (range 8-14 months). Post-operative evaluation included: Speech assessment, videofluoroscopy and perceptive evaluation of hypernasality (at 1,3,6,8 and 12months). Patients demonstrated improvement in hypernasality, voice resonance, and speech intelligibility. Improvement was greater in patients with isolated cleft palate sequelae when compared to patients with syndromic cleft palate.

Conclusion: The augmentation of the posterior pharyngeal wall by means of fat grafting, is well tolerated and preliminarily effective in cases of mild to moderate VPI. Long term follow up is further needed in order to evaluate fat graft retention and the need for a secondary fat grafting procedure.

Oral Presentation | Free paper (Skin/ Burn/ Wound Healing 3)

P29

Self-assembling MSC-sheet promotes wound healing increasing M2 macrophage polarization

Qiannan Zhao¹, Michiharu Sakamoto¹, Yuanjiaozi Li¹, Eiichi Sawaragi¹, Hang Dong¹, Hitoshi Kusano², Naoki Morimoto¹

¹ Department of Plastic and Reconstructive Surgery, Graduate School of Medicine, Kyoto University, Sakyo-ku, Kyoto, Japan

² PharmaBio Corporation, Kawasaki City, Kanagawa, Japan

Background: Mesenchymal stem cell (MSC) therapy holds promise for treating chronic wounds, but low cell density and short retention time limit efficacy.

Objective: This study investigates the therapeutic effects of self-assembling MSC-sheet in a mouse wound model, focusing on wound healing effects and macrophage infiltration.

Methods: MSC-sheets were prepared from human subcutaneous adipose tissue by PharmaBio Corporation, and characteristics were analyzed using histology. In vivo, the α MEM (control), MSC-suspension, and MSC-sheet were applied to full-thickness skin defects of C57BL/6J Jcl mice. Evaluation on days 7, 14, and 21 included the remaining wound area, neoepithelialization, granulation tissue, cell retention time, angiogenesis, and macrophage infiltration using Hematoxylin and Eosin, Azan, anti-human nucleoli (HN), anti-CD31, anti-CD68, and anti-CD163 staining. Macrophage polarization was evaluated using RT-PCR on days 3, 7, and 14.

Results: MSC-sheet had a multilayer structure (6-7 layers) containing ECM. In vivo, both MSC-sheet and MSC-suspension significantly reduced remaining wound area (day7 and day14), increased neoepithelialization (day14), granulation tissue formation (day7), angiogenesis (day7) and macrophage infiltration (day7 and day14) compared to the control group. MSC-sheet maintained MSC presence on day7 and induced greater M2 macrophage infiltration than MSC-suspension. RT-PCR confirmed the superior M2 macrophage-inducing properties of MSC-sheet.

Conclusion: MSC-sheet and MSC-suspension accelerated wound healing and increased M2 macrophage polarization. MSC-sheet, with multilayered structure and ECM, outperform MSC-suspension in promoting M2 macrophage infiltration and prolonging cell retention. Therefore, self-assembling multilayer MSC-sheet is a promising cellular delivery and treatment option for chronic wounds.

Oral Presentation | Free paper (Regenerative medicine)

P30

Systematic analysis of beneficial effects of platelet lysates on human adipose-derived stem cells

Sakurako Kunieda¹, Michika Fukui¹, Zhongxin Sun¹, Atsuyuki Kuro², Natsuko Kakudo¹

¹ Department of Plastic and Reconstructive Surgery, Kansai Medical University

² Department of Plastic and Reconstructive Surgery, Kansai Medical University Medical Center

Purpose: Human adipose-derived stem cells (hASCs) are the family of mesenchymal stem cells with self-renewal and differentiation potential into multiple cell-lineages. hASCs are applied to tissue reconstruction in plastic and aesthetic surgery, such as fat grafting, wound healing and scar remodeling. On the other hand, platelet lysates (PL), which contains various growth factor, is widely used in anti-aging and anti-inflammatory therapy. To clarify the preferential effect of PL on the ability of hASCs, systematic analysis including RNA sequence was performed.

Methods: hASCs were cultured without or with PL and FBS. The cell proliferation was examined by CCK8 assay. RNA-sequence was performed, using RNA from hASCs without or with PL and FBS, and obtained data were analyzed by GO analysis.

Results: The hASCs cultured with PL showed the proliferative activity more than with the standard condition containing FBS. The analysis by RNA-sequence showed that the genes involved in the proliferation and anti-stress were markedly upregulated in the PL group. RT-PCR confirmed that genes involved in the cell growth and cellular stress tolerance were upregulated, and differentiation markers were downregulated. Furthermore, when hASCs were treated with DNA damaging drug, PL group were more survived than FBS group.

Conclusion: PL showed the marked proliferation of hASCs, accompanied by protection against cellular stress.

P31

The Mechanism Study of ADSC Derived Exosomes LncRNA Promote Skin Closure

SHI XIONG^{1,2}, JUN ZHANG², JINLONG HUANG²

¹ Plastic Surgery Dept. Ningbo No.2 Hospital

² Affiliated Hospital of Nanjing University of Chinese Medicine

Background: Exosomes are vesicle structures with a diameter of 30-100 nm, and their main components are proteins, miRNAs, mRNA, DNA and lipids. Skin healing is a series of continuous complex interactions between cells and mediator in the body.. It is of great clinical significance to study stem cell-derived exosomes' influence and mechanism and their active components on skin healing.

Objective: To explore the role and potential mechanism of adipose stem cell-derived exosomes (Exos) (ADSCs) in promoting skin wound healing. The effects of Exos on the proliferation and migration of human dermal fibroblasts (HDFs), extracellular matrix (ECM) synthesis, and animal skin wound healing were also evaluated.

Methods: Adipose-derived stem cells (ADSCs) were isolated and cultured from human adipose tissue to induce ADSCs to secrete exosomes (Exos). The characteristics of the isolated Exos were identified using transmission electron microscopy and Western blot. The fluorescence-labelled Exos was co-cultured with human dermal fibroblasts (HDFs) to observe the absorption of Exos by HDFs. Cell models were transfected with different plasmids and long non-coding RNAs (lncRNAs). The effect of APS and Exos on skin healing was evaluated by constructing a rat skin wound model.

Results: In this study, we explored in detail the role of adipose stem cell (ADSC) -derived exosomes (Exos) on human dermal fibroblasts (HDFs) and the regulatory role of lncRNAs in this process, reinforcing our findings through rigorous statistical analysis.

Conclusion: The findings of this study are significant, demonstrating that ADSCs-derived exosomes (Exos) can promote the proliferation, apoptosis and migration of HDFs, and accelerate skin healing in rats. The mechanism is intricately related to lncRNA in Exos. lncRNA acts as a molecular sponge, thereby upregulating the expression of transforming growth factor beta receptor 1 (TGFB β 1), activating the TGF- β signaling pathway, and ultimately promoting skin healing. Exos promotes skin repair by regulating the lncRNA /TGFB β 1 axis, a crucial finding that could potentially revolutionize the field of wound healing.

E-poster

P32

Effect of basic fibroblast growth factor in perifascial areolar tissue transplant

Junya Oshima, Yoichiro Shibuya, Kaoru Sasaki, Mitsuru Sekido

Department of plastic, reconstructive, and hand surgery, University of Tsukuba

Background: Perifascial areolar tissue (PAT) transplant is a technique in which a sheet of connective tissue on the fascia is harvested and transplanted to the wound bed. PAT engraftment fails when the exposed area of tendons, bones, or artificial materials is large. On the other hand, combination of tissue transplant and basic fibroblast growth factor (bFGF) improves the survival rate of the transplanted tissue.

Objective: A wound model was created in which the artificial material was exposed on rats' backs.

Methods: All the rats underwent PAT transplant, but the rats were divided into 2 groups according to the PAT processing method beforehand. In 1 group, the PAT was immersed in water for injection before transplant (bFGF[-] group), and in the other group, the PAT was immersed in bFGF product (bFGF[+] group). Specimens were collected 7 days after surgery to assess the histologic thickness of the PAT and the gene expression in the PAT.

Results: The thickness of the PAT in the tissue slices was significantly higher in the bFGF(+) group than in the bFGF(-) group. Expressions of CD34 and COL3A1 were significantly higher in the bFGF(+) group than in the bFGF(-) group.

Conclusion: The results of this study indicate that adding bFGF to the PAT transplant may promote PAT engraftment and wound healing by increasing angiogenesis and may increase granulation formation, which may result in a stronger covering that prevents the prosthesis from being exposed.

Oral Presentation | Free paper (Skin/ Burn/ Wound Healing 2)

P33

Alteration of Inflammatory Response by Subcutaneous Transplantation of Burned and Frostbitten Skin

Rieko Shimizu, Tatsuyuki Ishii, Ayano Shimono, Kazuo Kishi

Keio university

Objective: Burns and frostbite are tissue injuries caused by changes in external heat; however, there are marked differences in the clinical course after injury. This is thought to be due to a change in the inflammatory response of the organism caused by the difference in heat. However, we hypothesized that tissue changes caused by differences in heat may cause changes in the inflammatory response to the surrounding tissue.

Methods: Third-degree burns and frostbite skin were prepared Using ICR mouse skin. The skin was transplanted under allogeneic mice. After various periods, the skin was collected along with the surrounding tissue, and the inflammatory response and structural changes in the tissue were observed under a microscope.

Results: In the burn model, prominent angiogenesis and inflammatory cell infiltration in the surrounding area, prominent destruction of dermal collagen fibers, and fusion of the extracellular matrix were observed. In contrast, the third-degree frostbite model showed little inflammatory reaction in the surrounding area, and the collagen fiber structure was preserved under light microscopy.

Conclusion: Differences in the inflammatory responses of burn and frostbitten skin to the surrounding environment were confirmed. It has been suggested that differences in tissue structure owing to differences in heat may cause differences in the respective clinical courses. The findings of this study indicate that, compared to frostbite, burns often present with hypertrophic scars and keloids. Future analyses of these mechanisms may be useful for preventing these conditions.

Development of an AI-Powered System for Automatic Four-Class Classification and Area Measurement of Skin Ulcers

Kazufumi Tachi, Koichi Gonda, Jyun Takami

Tohoku Medical and Pharmaceutical University

Background: Effective treatment of refractory ulcers relies on assessing tissue property and ulcer size. To overcome evaluation gaps between observers and those resulting from manual measurement, we developed AI-powered system to automate classification of tissue type and area measurement of each ulcer type.

Objective: To evaluate the accuracy and consistency of the AI-powered diagnosis system.

Methods: The system includes the UlcerAnalyzer unit for generating training data and a deep learning application for training neural networks. The UlcerAnalyzer offers user interface for and digitalization of manual classification of ulcer images into six classes: Background, Standard Area Sticker, Healthy Granulation, Marbled Granulation, Slough, and Necrotic. A dataset of 1,095 images, with 80% for training and 20% for evaluation, was created. This dataset trains the neural networks, forming the core of the AI model. The entire software framework and system components were designed and developed by the researchers themselves, all of whom are practicing plastic surgeons.

Results: Precision rates were: Background 99.2%, Sticker 95.5%, Healthy Granulation 0%, Marbled Granulation 79.2%, Slough 83.9%, Necrotic 79.8%. Overall accuracy was 99.3%. The system also automatically measured ulcer areas based on the sticker's area and displayed these measurements graphically (figure 1).

Discussion and Conclusion: The low performance in Healthy Granulation is due to limited data. Other classes showed fairly satisfactory results. Challenges included defining class boundaries, highlighting the need for the functional addition to UlcerAnalyzer that assists users in distinguishing subtle color differences. Features such as visual overlays to emphasize color intensity variations could make classification easier.

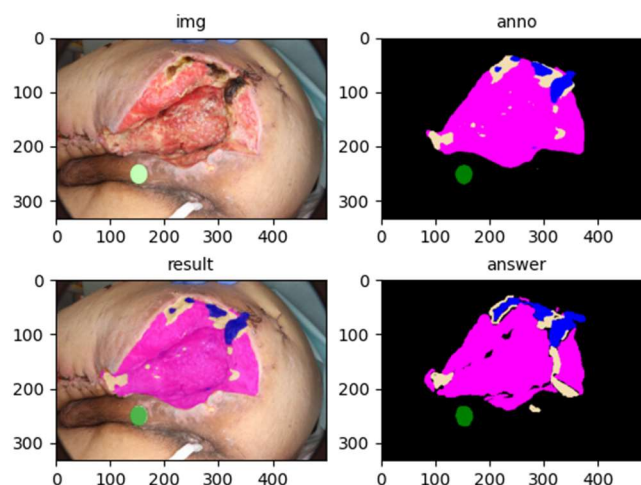
Figure 1. Example outputs from the AI model.

“img” : Original image used for inference.

“anno”: Output image from the trained AI model.

“answer” : Ground truth image.

“result” : Combined image of the original and AI model output.



Oral Presentation | IPSRC APRAS award session 2

P35

Investigation of Lymphatic flow dynamics using photoacoustic imaging system

Yushi Suzuki, Hiroki Kajita, Marika Otaki, Hayato Nagashima, Nobuaki Imanishi, Kazuo Kishi

Keio University School of Medicine, Department of Plastic and Reconstructive Surgery

Background: Exercise therapy is an optimal treatment for lymphedema. However, lymphatic vessels are tiny and transparent, making visualization and assessment of lymphatic flow difficult during exercise.

Objective: We evaluated the effect of exercise on lymphatic vessels using a photoacoustic imaging (PAI) device, a new modality that three-dimensionally visualizes tiny blood and lymphatic vessels with a high resolution of 0.2 mm.

Methods: PAI was performed on healthy volunteers using a LUB0 (Luxonus Inc.), and indocyanine green was administered subcutaneously to visualize lymphatic vessels. To simulate exercise, the electrical muscle stimulator G-TES (General Therapeutic Electrical Stimulator, Homer ION Laboratory Co., Ltd.) was used. G-TES can stimulate muscles between two belt electrodes and enable stimulation of the entire muscle of the limb as a substitute for voluntary movement. Lymphatic flow was assessed in three phases: at rest, during G-TES use, and after G-TES use. The medial lower leg lymphatic vessels were observed by video recording for 5 minutes, and the number of lymphatic pumps was evaluated.

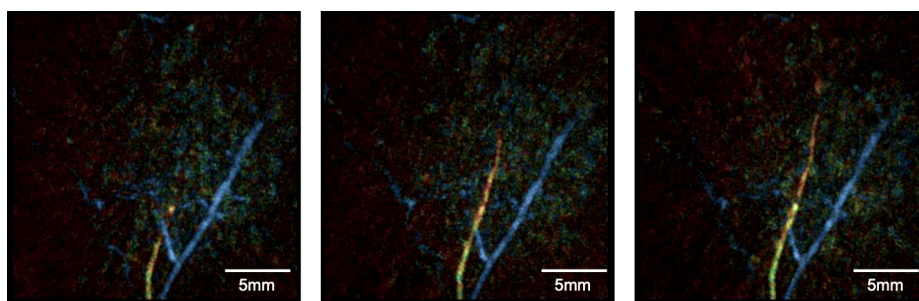
Results: Six healthy volunteers (one man, five women, mean age 51.5 ± 9.8 years) participated. The lymphatic pump frequency was 0.37 ± 0.17 times/min at rest, 0.47 ± 0.22 times/min during G-TES, and 0.80 ± 0.36 times/min after exercise. Significant differences ($p=0.048$) were observed between rest and post-exercise conditions.

Conclusion: This study confirms that exercise significantly enhances lymphatic pump activity, as shown by photoacoustic imaging. These findings reinforce the integral role of exercise therapy in effectively promoting lymphatic flow for lymphedema treatment.

PAI enables observation of lymphatic flow in high resolution. The figure was created by capturing the video.

Yellow: lymphatic vessels

Blue: veins



E-poster

P37

Transforming Aesthetic Surgical Education Using Artificial Intelligence

Austin Chen, Karim Bakri

Mayo Clinic, Rochester

Background: ChatGPT has potential as an educational tool and source of information for surgical education.

Objective: The aim of this study is to assess its usefulness in aesthetic surgery education via evaluation of the accuracy and appropriateness of its information.

Methods: Ten of the most common aesthetic procedures were identified. Two question stems were fed into ChatGPT for each, one requesting general information and the other requesting procedural steps. A medical student, junior plastic surgery resident, senior resident and faculty member reviewed the outputs. Medical student and residents evaluated information on a Likert scale (1-5) for usefulness in case preparation. Faculty graded information on a Likert scale (1-5) for accuracy and adequacy based on training level.

Results: Faculty evaluation of general information resulted in a median Likert of 5 (range of 4 to 5) for accuracy and PGY-2 level for adequacy (range of PGY1 to PGY 2). Faculty evaluation of surgical steps resulted in a median Likert of 4 (range of 2 to 5) and PGY-2 level for adequacy (range of PGY1 to PGY3). Medical students scored usefulness of ChatGPT extracted information with a median Likert of 5 (very useful) for both stems. Junior residents scored usefulness of both stems with a median of 3 (neutral), senior residents scored usefulness of both stems with a median of 2 (minimally useful).

Conclusion: These results suggest that ChatGPT has potential as an surgical educational resource, although at the present time perhaps just for junior level trainees.

E-poster

P39

Three-Dimensional Printing cells laden F127 on Gelatin/Alginate Scaffold Promote Wound Recovery

Yi-Wen Wang, Chen-Li Ma, Kai-Chieh Chou

Department and Graduate Institute of Biology and Anatomy, National Defense Medical Center, Taipei, Taiwan

Background: Full-thickness skin wounds are a severe clinical issue, leading to increased infection risks, pain, and economic burdens due to prolonged treatment. Recent advancements in 3D printing technology have facilitated the construction of tissue-engineered skin.

Objective: This study aimed to develop and assess a gelatin/alginate (G/A) 3D-printed scaffold using F127 to enhance cell distribution for treating large, full-thickness skin defects.

Methods: We analyzed the physical and biological properties of the cell-laden F127/G/A scaffold and its potential to promote wound healing. Mechanical strength was evaluated using a universal testing machine. Swelling and degradation rates were measured, and biocompatibility was assessed through CCK-8 assays and DAPI/PI staining. Fibroblasts and keratinocytes were layered onto the scaffold to simulate the dermis and epidermis.

Fluorescence microscopy was used to observe cell layering, and animal experiments were conducted to assess wound healing efficacy.

Results: The G/A scaffold demonstrated elasticity, withstanding a tensile force of approximately 1.5 N and a maximum elongation rate of 111.18%. The scaffold's swelling rate increased by 19% post-cross-linking and 43% after water absorption. It degraded by approximately 40% in PBS over 14 days. Fibroblasts proliferated and adhered well within the scaffold. Fluorescence microscopy confirmed successful layering of fibroblasts and keratinocytes, creating a dermis/epidermis structure. Transplantation onto full-thickness skin wounds in mice accelerated healing compared to controls.

Conclusion: These findings suggest that the developed 3D-printed tissue-engineered skin holds promise for future clinical wound healing applications.

Oral Presentation | IPSRC Best paper session

P40

Relationship between epidermal keratinocyte division and Keratin17 in skin texture formation

Toko Oida¹, Noriko Aramaki², Keisuke Okabe², Hikari Kajiwara³, Kazuo Kishi²

¹ Keio University School of Medicine

² Department of Plastic and Reconstructive Surgery, Keio University School of Medicine

³ Keio University Faculty of Pharmacy

Background: The mechanism underlying the formation of skin texture remains unknown. Our previous studies have demonstrated that Keratin17 (K17) plays a role in the formation of skin texture.

Objective: We investigated the relationship between cell proliferation and K17 expression.

Methods: (1) The depth of skin texture of embryonic day 15 (E15) K17KO and WT B6 mice was measured, and paraffin sections of the skin were immunostained with antibodies against PCNA, CyclinD1, and p-STAT3. RNA was extracted from K17KO and WT E18 skin, and separated into epidermis and dermis, and subjected to microarray analysis and real-time PCR. (2) CyclinD1 inhibition was performed using K17 overexpressing cells (K17OE) and non-target cells (NT). Additionally, the EGF Pathway Phospho Antibody Array was employed to examine the changes in signaling activity induced by K17OE.

Results: (1) K17KO displayed a significantly shallower skin depth than the WT, and PCNA staining demonstrated that cell proliferation in the epidermal basal layer was significantly suppressed in K17KO compared to WT. Epidermal microarray analysis and immunostaining results indicated that CyclinD1 expression in the cell proliferation cascade was significantly reduced in K17KO compared to WT. STAT3 phosphorylation was also significantly suppressed by K17KO. The phosphorylation of FAK and GAB2, which are EGF signaling molecules, was significantly reduced in K17OE compared to NT.

Conclusion: These results suggest that in epidermal keratinocytes, cell division is mediated by K17 expression and subsequent enhancement of Cyclin D1 and nuclear migration, which are involved in the formation of skin texture during the embryonic period.

P41**Investigation of keloid pathogenesis focusing on mechanical stress**

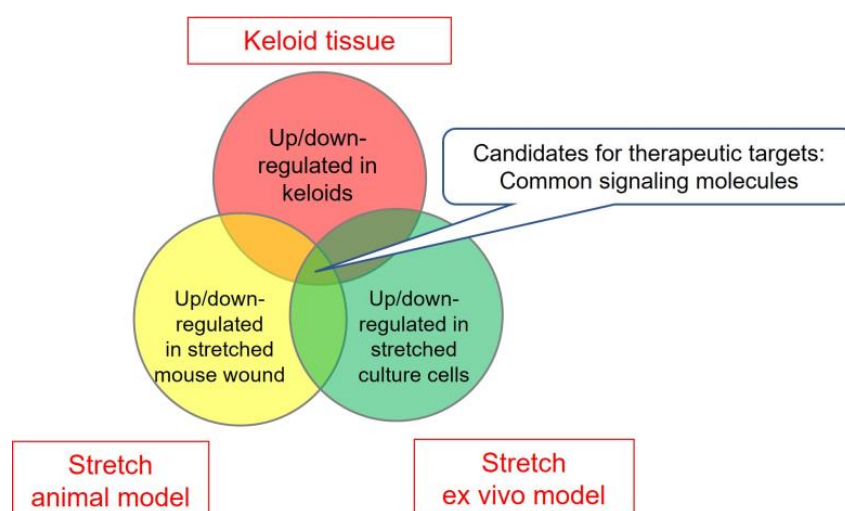
Keisuke Okabe, Riho Takayanagi, Yukari Nakajima, Tatsuya Kato,
Noriko Aramaki-Hattori, Kazuo Kishi

Department of Plastic and Reconstructive Surgery, Keio University School of Medicine

Background: Keloids are characterized by individual differences in susceptibility, specificity of the body site of predilection, and mechanical stress as an initiating and exacerbating factor. We will report on the current status of our research efforts, which integrate basic and clinical studies, with the aim of developing treatments that focus on mechanical stress.

Materials and Methods: Since there is no animal model that can reproduce the pathophysiology of keloids exactly, we developed a novel animal model and a culture model. Using both models, we attempted to comprehensively analyze and select genes whose expression is altered by mechanical stress loading. We also performed gene expression analysis using surgical specimens obtained from keloid patients and compared the results with those obtained from the models.

Results and Discussion: For the mouse model, the healing results were significantly altered when manual tension was applied daily after back wound creation in order to apply repetitive tension stimulation. For the culture model, fibroblasts derived from keloid patients were seeded into the artificial dermis and cultured while repeated tension stimulation was applied. Cytoskeletal changes and overall changes in gene expression were observed upon mechanical stress. In comparison to the keloid patient-derived tissues, there were genes that overlapped and changed in both cases, while there were genes that showed conflicting results. We believe that by organizing and comparing the similarities and differences between the results of the model and those of the patient tissues, we can get closer to the essence of the mechanism of keloid pathogenesis.



Oral Presentation | Free paper (Skin/ Burn/ Wound Healing 2)

P42

A clinical trial for quantifying wound healing regulatory factors in acute and chronic wounds

Arisa Tani, Takuto Oyama, Shiro Jimi, Satoshi Takagi
Fukuoka University Hospital

Background: Patients with wounds undergo either acute or chronic healing processes. In the favorable process, wounds are followed by a normal wound-healing process accompanied by different emerging tissues, such as granulation, neovascularization, and epithelization. However, some patients undergo an unfavorable process, resulting in unhealed and chronic wounds. Although many theories have been published, the pathogenesis is still uncertain.

Objective: Using clinically different wound patients in Fukuoka University Hospital with burns, bed sores, etc., exudates absorbed for 24 hours by cotton balls on the wound were collected in the presence of a proteinase inhibitor and stored in a deep freezer until use.

Methods: We focused on major regulatory compounds for wound healing, such as IL10, TGF β , TNF α , VEGF, and HGF. ELISA method was utilized for the quantification. The levels were compared with their clinical courses.

Results: All of the compounds were measurable during the study. IL10, TGF β , TNF, and VEGF showed similar variability during their clinical courses. In acute wounds, TNF and VEGF increased in the initial phase of wound healing, but they declined thereafter. On the other hand, in chronic ulcers, such changes were undetected.

Conclusion: Cytokines and growth factors play an important role in the genesis of inflammation, granulation, and epithelization in wounds. Here, the biologically important factors we selected in the wound exudates could be measured by ELISA methods. The change in the factors may indicate different tissue reactions in the clinical process, which could determine the genesis of acute and chronic wounds.

Oral Presentation | IPSRC Best paper session

P43**Exploration of Regenerative Factors in Murine Fetal Skin Wounds**Yukari Nakajima¹, Ward Nijen Twilhaar², Ikuko Koya², Yoshinari Ando², Akiko Minoda², Kazuo Kishi²¹ Plastic and Reconstructive Surgery of Keio University² RIKEN Center for Integrative Medical Sciences

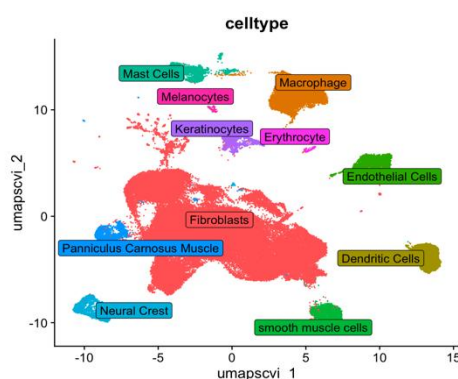
Background: Mammalian skin regenerates without scarring after injury until mid-gestation. We demonstrated that in murine, full-thickness skin incisions before embryonic day (E) 13 completely regenerate, including the skin texture, while from E14 to E16, the dermis regenerates but the texture does not. From E17 onwards, fibrosis occurs, resulting in scar formation.

Objective: To determine these changes, single cell analysis of the wound site was performed at various times after E13, 15, and 17.

Methods: We focused our analysis on the interaction between macrophages and fibroblasts. Among the genes identified, we figured out one gene with increased expression in macrophages on E17. Then we used knockout mice for this gene and observed the progression of its fetal skin wounds. Additionally, we analyzed the factors that induce complete regeneration on E13.

Results: When the recombinant protein of the gene, which had increased expression in macrophages on E17, was administered to the wound site on E13, the skin texture disappeared. Conversely, in embryos where this gene was knocked out, fibrosis was suppressed on both E15 and 17, when normal skin regeneration does not usually occur. Additionally, the cluster analysis revealed that macrophages can be categorized into several clusters, each with distinct gene expressions and roles. Notably, some factors released extracellularly when the skin is damaged on E13 appear to act on macrophages and dermal fibroblasts to promote regeneration.

Conclusion: The analysis at various time points following fetal skin wound allowed us to approach the mechanisms of complete skin regeneration and fibrosis.



Oral Presentation | Free paper (Others)

P45

First Attempt at Assessing the Effects of Animal-Assisted Therapy (AAT) on Plastic Surgery Patients

Risako Ito¹, Yuki Ando¹, Akinari Yoshizawa², Ami Kuwabara², Hiroaki Yamamoto³, Yuki Bando⁴, Kyoko Baba¹, Akira Takeda²

¹ Department of Plastic Surgery, Kitasato University Medical Center

² Department of Plastic and Aesthetic Surgery, School of Medicine, Kitasato University

³ Department of Psychiatry, Kitasato University Medical Center

⁴ Department of Pediatrics, Kitasato University Medical Center

【Introduction】

Animal-assisted-therapy (AAT) is a form of complementary medicine that utilizes the power of companion animals to enhance the mental or physical health of patients. Our hospital is a rare institution that conducts acute-phase AAT. We implemented AAT for acute-phase patients in the plastic surgery department. This is the first report assessing the effects of AAT on plastic surgery patients.

【Subjects and Methods】

Patients hospitalized with physical injuries, were included in the study. Patients self-assessed their condition using our own assessment form and the VAS. The assessment form comprised four items—anxiety, stress, adaptation, and communication—each rated on a five-point scale. Assessments were conducted before AAT intervention, after the first and the second intervention.

【Results】

There was a total of two cases. In both cases, self-assessment using the assessment form showed an improvement in psychological state after AAT intervention. Details of each case are outlined below.

Case 1: A 61-year-old female with diabetic foot gangrene requiring emergency admission and first toe amputation surgery.

Case 2: A 60-year-old male with untreated diabetes, admitted urgently for right diabetic foot gangrene, underwent below-knee amputation surgery.

【Discussion】

In our cases, both patients showed improvement in psychological state after AAT, suggesting its effectiveness for hospitalized plastic surgery patients with injuries resulting from trauma or treatment. By increasing the number of cases and further accumulating evidence, we anticipate recognizing the significance of AAT as complementary medicine and contributing to its expansion and improvement in patient care.

P46

A prospective and randomized study comparing ultrasound-guided real time injection to conventional blind injection of botulinum neurotoxin for glabellar wrinkles

Kuangyun Tang

Aesthetic Medicine Department, Stomatology Hospital, School of Stomatology, Zhejiang University School of Medicine

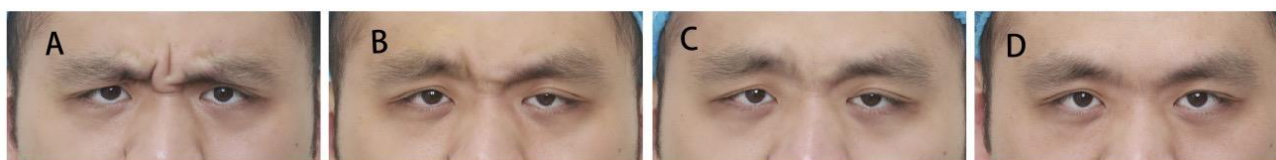
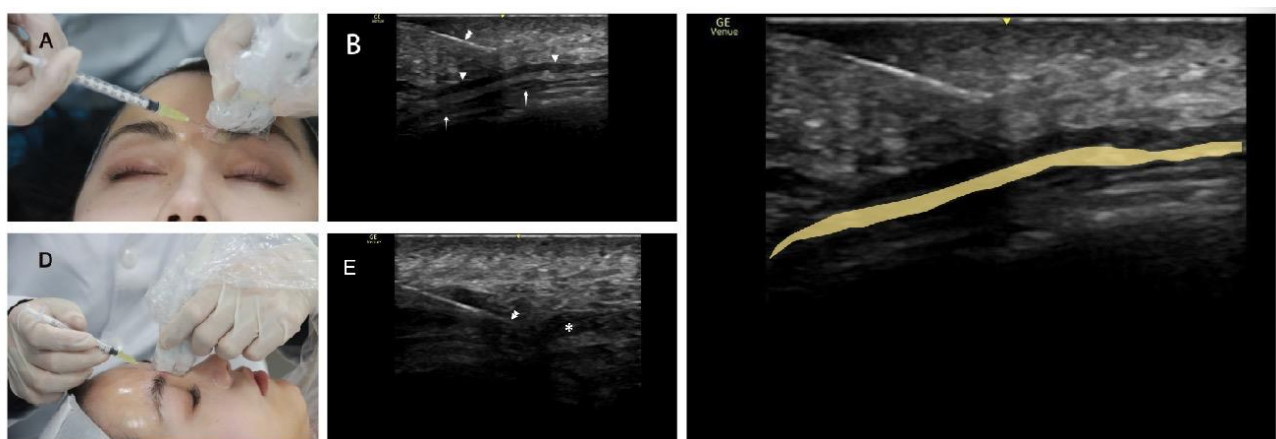
Background: Botulinum neurotoxin injections are the most frequently performed cosmetic procedures, but conventional blind injection for glabellar wrinkles remains to have some limitations.

Objective: We intend to directly inject botulinum neurotoxin into the glabella complex guided by real time ultrasound. We aim to propose a more efficient and safer botulinum neurotoxin injection strategy for glabellar wrinkles.

Methods: A total of 40 subjects with moderate to severe glabellar lines were enrolled in this study to receive botulinum neurotoxin injection, either through ultrasound-guided real time injection or conventional blind injection. Facial Wrinkle Scale and inter-brow distance (from 3D scanned face images) were used to evaluate the glabellar wrinkles improvement.

Results: The wrinkle score reduction was significant ($p < 0.0001$) immediately after the injection in ultrasound-guided injection group, but not in blind injection group ($p = 0.163$). Ultrasound-guided injection also showed a higher performance of wrinkle score reduction and more effective inter-brow distance increase over blind injection at Day 0, Day 1, Day 21 and Day 35 after initial treatment.

Conclusion: The results of the study confirmed that botulinum neurotoxin injection for glabellar wrinkles under ultrasound guidance achieves quicker onset of action and better final outcomes compared to conventional blind injection.



Injection effects: A. Glabellar frown lines at maximum frown before injection; B. The immediate improvement effect after injection; C. Effect on Day 21; D. Effect on Day 35.

Oral Presentation | IPSRC Best paper session

P47**The possibility of phagocytes playing a role to control wound healing process in newts**Kento Hosomi¹, Kazuaki Maruyama², Kyoko Imanaka², Isao Tawara³, Makoto Shiraishi⁴, Mitsunaga Narushima¹¹ Department of Plastic and Reconstructive Surgery, Mie university² Department of Pathology and Matrix Biology, Mie university³ Department of Community Hematology, Mie University⁴ Department of Plastic and Reconstructive Surgery, The university of Tokyo

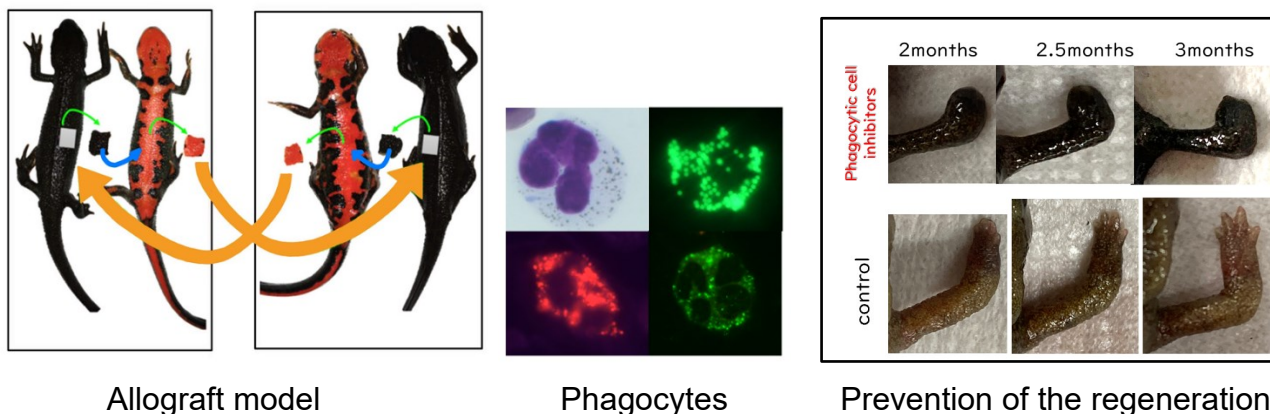
Background: Newts have incredible regenerative abilities. However, they lose the ability to regenerate limbs by phagocytic cell inhibitors. We investigate the immune system, which controls responses during wound healing, focusing on phagocytes. We discovered a unique and surprising response to allograft tissue, and its relationship with newt phagocytes.

Objective: The aim of this research is to detect phagocytes in newts and to elucidate how phagocytes play a role during wound healing process.

Methods: Newts were either allografted or autografted. Red skin from the abdomen was transplanted to the skin defect created on the back, which enabled us to find the border of the grafted red skin. Tissue samples were obtained at each postoperative period. In order to label phagocytes, fluorescent beads, Dil-liposomes were injected intravenously. After administration the phagocytic cells inhibitor, the progress of wound healing was observed.

Results: The allografts were well attached to the host tissue but were gradually replaced by the surrounding skin. Both fluorescent beads and Dil-liposome enabled us detect phagocytes in blood and subcutaneous tissue. Most of them were similar to neutrophils. At certain stages after allografting, large number of immune cells were infiltrated, not seen in autograft. Some of those cells were phagocytes. Phagocytic cell inhibitors prevented the newts from regenerating properly.

Conclusion: The unique response of newts to allografts was considered to be related to phagocytes. Elucidating the characteristics of these cells in detail could lead to uncover how to control unnecessary excessive inflammation and fibrosis.



P48

Mechanisms of Cartilage Degeneration Post Autologous Costal Cartilage Transplantation in Microtia Treatment

Arisa Kita^{1,2}, Shinji Kato², Kanna Nagaishi¹, Takatoshi Yotsuyanagi²

¹ Department of Anatomy 2, Sapporo Medical University

² Department of Plastic and Reconstructive Surgery, Sapporo Medical University

Background: In reconstructive surgery for congenital microtia, autologous costal cartilage transplantation is performed in two stages. While this therapeutic method indicates better postoperative outcomes than use of artificial materials, degeneration occurs in the transplanted tissue over the long-term. The mechanism of tissue degeneration remains unknown, and any methods to effectively suppress the degeneration have yet to be established.

Objective: The aim of this study was to elucidate the phenomena in the cartilage after heterotopic transplantation by histological evaluation and gene expression analyses.

Methods: Cartilage samples were obtained from 10- to 12-year-old patients with microtia. Fresh costal cartilage was obtained at the initial surgery. Heterotopically transplanted cartilage was obtained from subcutaneous adipose tissue at the second surgery, which was performed 6 to 12 months after the initial surgery. The transplanted cartilage was compared with fresh cartilage to analyze the alteration due to transplantation.

Results: The number of cells per unit area and the survival rate of cells were reduced in the transplanted cartilage tissue. There was no significant difference in the size of cells. The amount of proteoglycan in the cartilage tissue was reduced, and the expression of genes involved in matrix component were changed.

Conclusion: Preventing degeneration of cartilage tissue after heterotopic transplantation is important because costal cartilage is physically demanding during harvesting and the amount of harvested tissue is limited. This study provides insights into preventing cartilage degeneration after transplantation.

P49

iPSC-derived megakaryocytes and platelets accelerate wound healing and angiogenesis.

Kentaro Kosaka¹, Naoya Takayama², Sudip Kumar Paul², Koji Eto^{2,3}, Nobuyuki Mitsukawa¹

¹ Department of Plastic, Reconstructive, and Aesthetic Surgery, Chiba University Graduate School of Medicine, Chiba, Japan

² Department of Regenerative Medicine, Chiba University Graduate School of Medicine, Chiba, Japan

³ Department of Clinical Application, Center for iPS Cell Research and Application (CiRA), Kyoto University, Kyoto, Japan

Background: Platelet-rich plasma (PRP) shows efficacy in chronic skin wounds via multiple growth factors. However, it exhibits heterogeneity across patients, leading to unstable therapeutic efficacy. Human iPSC-derived megakaryocytes and platelets (iMPs) can provide a stable supply, holding promise as materials for novel platelet concentrate-based therapies. In this context, we evaluated the effect of iMPs on wound healing and validated lyophilization for clinical applications.

Methods: The growth factors released by activated iMPs were measured. The effect of the administration of iMPs on human fibroblasts and HUVECs was investigated in vitro. iMPs were applied to dorsal skin defects of diabetic mice to assess the wound closure rate and quantify collagen deposition and angiogenesis. Following the storage of freeze-dried iMPs (FD-iMPs) for three months, the stability of growth factors and their efficacy in animal models were determined.

Results: iMPs specifically released FGF2 and exhibited superior enhancement on HUVEC proliferation compared to PRP. Animal studies demonstrated that iMPs promoted wound closure and angiogenesis in chronic wounds caused by diabetes. We also confirmed the long-term stability of growth factors in FD-iMPs and their comparable effects to those of original iMPs in the animal model.

Conclusion: Our study demonstrates that iMPs promote angiogenesis and wound healing through the activation of vascular endothelial cells. iMPs exhibited more effectiveness than PRP, an effect attributed to the exclusive presence of specific factors including FGF2. In addition, lyophilization can contribute to their stable supply for clinical application. These findings suggest that iMPs provide a novel treatment for chronic wounds.

P50

Utilizing Virtual Reality for Suture Technique Education: Potential as an Auxiliary Tool for Independent Learning in Medical Students

Yuichi Hatsuoka, Shimpei Ono, Rei Ogawa

Department of Plastic, Reconstructive and Aesthetic Surgery, Nippon Medical School

Background: Plastic surgery requires precise techniques and advanced skills, making the learning of suturing skills crucial. Direct instruction by medical advisors is essential for medical student education, but time limitations restrict these opportunities. Simulated anatomical experiences like VR offer solutions, yet suture skill education via VR is uncommon. **Objective:** We created a VR movie for suture technique education to evaluate its potential as an auxiliary tool for independent learning.

Methods: Twelve interested medical students participated. After a PowerPoint and VR lecture, subjects performed skin stitches using a practice skin pad, without direct instruction. Post-exercise, students rated their confidence, comprehension, satisfaction, VR three-dimensionality, immersion, and discomfort on a 5-point Likert scale. An open-ended response section was included for overall feedback.

Results: The entire process took about 1.5 hours, with all students completing the skin suturing. Eleven students responded, with most feedback being positive, regardless of prior VR experience or grade level. Only one student reported any discomfort from the VR. Free responses highlighted a sense of realism, three-dimensionality, and the possibility of home study.

Conclusion: VR in teaching plastic surgery procedures offers a realistic learning experience without consuming instructor time. This tool promotes independent learning and could significantly enhance current educational methods.



E-poster

P51

Preliminary Investigation Comparing Intraocular Pressure in Glaucoma Patients Before and After Blepharoptosis Surgery: Potential Impact in Intraocular Pressure Based on Surgical Technique

Yuki Ohtake¹, Yusuke Kono¹, Emi Nishiyama², Risako Ito³, Yuki Ando³, Masashi Ishiguro⁴, Kyoko Baba³, Akira Takeda²

¹ Department of Ophthalmology, Kitasato University Medical Center

² Department of Plastic and Aesthetic Surgery, Kitasato University School of Medicine

³ Department of Plastic Surgery, Kitasato University Medical Center

⁴ Department of Aesthetic Surgery, Ageo Central General Hospital

Background: Glaucoma and blepharoptosis commonly coexist. In this study, we compared intraocular pressure before and after blepharoptosis surgery in patients with glaucoma, further investigating it by surgical procedure.

Objective and Methods: Glaucoma and blepharoptosis commonly coexist. In this study, we compared intraocular pressure before and after blepharoptosis surgery in patients with glaucoma, further investigating it by surgical procedure.

Results: In total, there were 8 cases (16 eyes), comprising 6 males and 2 females aged between 73 and 84 years. Blepharoptosis surgery techniques included levator muscle tucking in 5 cases (10 eyes), infra - eyebrow skin excision in 3 cases (6 eyes), and frontalis sling technique in 1 eye. Comparing pre- and postoperative IOP, 5 eyes had a decrease of 2 mmHg or more, 4 eyes had a decrease of 1 mmHg, 6 eyes had no change, and 1 eye had an increase of 1 mmHg. Of the patients whose IOP decreased by more than 2 mmHg, 3 cases (4 eyes) underwent levator muscle tucking, and 1 case (1 eye) underwent infra - eyebrow skin excision.

Discussion: In our cases, Blepharoplasty for glaucoma patients resulted in IOP reduction in about half of the eyes. By surgical procedure, levator muscle tucking suggested a greater potential for reducing intraocular pressure. Choosing levator muscle tucking seemed beneficial in cases of coexisting glaucoma and blepharoptosis. Our study results suggest the possibility of providing more meaningful surgeries tailored to patients' comorbidities.

P52

Fat Grafting for Facial Rejuvenation: A Systematic Review of Validated Patient-Reported Outcomes

Austin Chen¹, Austin Chen¹, Anmol Chattha², Bryce Hendren-Santiago², Daniel Wong², Summer Hanson², Jorys Jorge-Martinez¹

¹ Mayo Clinic, Rochester

² University of Chicago

Background: Fat grafting as an adjuvant procedure in facial rejuvenation has been increasing in use over time.

Objective: The aim of this study is to perform a systematic review of aesthetic facial fat grafting as an adjunct procedure in facial aesthetics and quantify validated patient reported outcomes measures (PROMs).

Methods: A systematic literature review was performed according to the Preferred Reporting Items for Systematic Reviews and Meta-Analyses (PRISMA) search strategy guidelines across 3 databases (MEDLINE, Embase, and PubMed) in December of 2022 identifying all articles describing facial fat grafting for aesthetic indications with validated PROMs.

Results: A literature database search revealed 909 articles. Review of these article abstracts revealed 138 articles. These 138 articles received a full article review, which lead to capturing 32 articles detailing some level of PROMs using our inclusion and exclusion criteria. A total of 9 of these studies were remaining after screening for articles only with validated PROMs. A total of 6 studies utilized the FACE-Q, 2 studies utilized the ROE-Q and one study utilized both the FACE-Q and ROE-Q. All single arm and double arm comparative studies reported improvement in FACE-Q or ROE-Q with fat grafting.

Conclusion: The use of fat grafting as an adjunct in facial rejuvenation showed promising patient reported outcomes to correct secondary rhinoplasty defects, as well as when used concomitantly in rhinoplasty and facelift surgery. However, one study showed no improvement in the perioral region.

Nipple-Sparing Mastectomy in Patients with Prior Breast Surgery: The Role of Autonomization in Preserving NAC Viability

Benedetta Agnelli^{1,2}, Monica Falaschi², Luigi Valdatta¹

¹ Division of Plastic and Reconstructive Surgery, Department of Biotechnology and Life Sciences, University of Insubria, Varese, Italy

² Division of Plastic, Reconstructive and Hand Surgery, Legnano Hospital, Legnano (Mi), Italy

Background: Breast reduction surgery alters the vascularization pattern of the nipple areolar complex (NAC), leading to a higher incidence of NAC compromise post-surgery. When patients with a history of breast reduction undergo nipple-sparing mastectomy, ensuring NAC viability becomes critical. The risk of vascular compromise is especially high in patients with surgery less than 12 months prior. The detection of a neoplasm at the histological evaluation of a breast reduction often requires prompt intervention, making autonomization techniques essential to enhance NAC survival rates.

Objective: This study presents our approach, implemented at our center, and compares it with data available in the literature.

Methods: We conducted a systematic literature review in line with the Preferred Reporting Items for Systematic Reviews and Meta-Analyses (PRISMA) guidelines. We utilized specific keywords and predefined MeSH terms across various search engines (Medline, Pubmed, Google Scholar databases). Concurrently, we assessed our own case series, reporting on complications and outcomes.

Results: Eight studies were identified, encompassing a total of 56 patients from the literature. The most commonly reported concern was the viability of the NAC. In our patient series, we did not encounter complications, except for one case of seroma.

Conclusion: The proposed autonomization technique for patients with previous breast reduction surgery helps reduce the risk of NAC compromise following nipple-sparing mastectomy, even with a short interval since the prior reduction. A larger case series is needed to confirm these findings.

Oral Presentation | Free paper (Skin/ Burn/ Wound Healing 3)

P54

Embryonic macrophages involved in skin regeneration

Shigeki Sakai, Keisuke Okabe, Noriko Aramaki, Yukari Nakajima,
Riho Takayanagi, Kazuo Kishi

Department of plastic and reconstructive surgery Keio university school of medicine

【Objective】 Mice regenerate their skin completely when they receive a wound by embryonic day 13. We have observed and studied that scar repair occurs without regeneration after the 14th day of gestation. Previous studies have confirmed that macrophages, which are F4/80 positive cells, accumulate prominently in the wounds of mice on day 13 of gestation. In this study, macrophages derived from fetal skin on gestational days 13 and 18 were isolated and transplanted to investigate the role of macrophages in skin regeneration in fetal mice.

【Methods】 The back skin of embryonic day 13 and 18 ICR mice was harvested and cells were separated by enzyme treatment. F4/80-positive macrophages were then collected by magnetic bead cell separation. They were transplanted into the back skin of embryonic day 14 mice to form a 1 mm full-layer skin defect and the wound was observed at 72 hours.

【Results】 In the transplantation experiments to the mouse dorsal whole skin defect on embryonic day 14, wounds transplanted with skin macrophages on embryonic day 13 showed less scarring grossly, whereas wounds transplanted with skin macrophages on embryonic day 18 showed scarring and edematous changes.

【Discussion】 We hypothesized that embryonic 13 skin macrophages have immature inflammatory pathways. Therefore, it is suggested that the inflammation-induced scar repair process does not function in embryonic 13 mice, while the inflammation-induced scar repair does in embryonic 18 mice.

Oral Presentation | Free paper (Skin/ Burn/ Wound Healing 2)

P55

Generation of self-assembled 3D human dermal tissue from fibroblasts

Hang Dong¹, Takashi Nakano¹, Hiroki Yamanaka¹, Michiharu Sakamoto¹, Jiro Ono³, Tetsuji Yamaoka², Naoki Morimoto¹

¹ Department of Plastic and Reconstructive Surgery, Graduate School of Medicine, Kyoto University, Kyoto, Japan

² Department of Clinical Engineering, Faculty of Health Sciences, Komatsu University, Komatsu, Japan

³ Tissue By Net Corporation, Saitama, Japan

Background:

Chronic wounds and large skin defects are major clinical challenges that urgently require effective strategies. Autologous cultured epidermis (CE) has been clinically used for wound healing. However, methods for dermis regeneration have not yet been established. Xenogeneic collagen has been used as many dermal substitutes, but it has limitations such as low vascularization, poor mechanical integrity, and poor compatibility with CE. Based on self-assembly, the creation of tissues or organs in vitro has become possible, which holds promise for creating dermal tissue.

Objective:

This study aims to develop a scaffold-free 3D dermal tissue composed entirely of fibroblasts and their extracellular matrix as a skin graft to promote skin wound healing.

Methods:

Fibroblast spheroids were fabricated on a non-adhesive surface and seeded into a 3D culture platform. A scaffold-free 3D dermal tissue was created through long-term culture and self-assembly of spheroids. We characterized its mechanical properties and biological characteristics in vitro and evaluated the wound healing effects compared to conventional artificial dermis in vivo.

Results:

The 3D dermal tissue demonstrated superior mechanical properties and higher collagen and glycosaminoglycan contents compared to the artificial dermis. In a murine model of full-thickness skin defects, the 3D dermal tissue promoted wound closure, re-epithelialization, and angiogenesis on days 7 and 14.

Conclusion:

We present a novel and reproducible method for creating scaffold-free 3D dermal tissue that effectively promotes skin wound healing. Our results demonstrate that the 3D dermal tissue will provide a transplantation strategy for future treatment of chronic wounds and large skin defects.

P56

Calcification of Achilles tendon in Werner syndrome

Shinsuke Akita¹, Hideyuki Ogata¹, Kahoko Yamada¹, Yoshihisa Yamaji¹,
Joceline Kadarman¹, Yuzuru Ikehara², Nobuyuki Mitsukawa¹

¹ Department of Plastic, Reconstructive, and Aesthetic Surgery, Chiba University Graduate School of Medicine,

² Department of Pathology, Graduate School of Medicine, Chiba University, Chiba, Japan.

Background: Werner's syndrome is a hereditary premature aging disease in which chronic wounds with characteristic calcification are extremely painful and difficult to treat. Chronic ulcers with calcification in the Achilles tendon area are particularly difficult to treat and cause amputation, but the cause of calcification has not been clarified.

Objective: The purpose of this study was to analyze the cause and course of calcification in Werner's syndrome.

Methods: Histological analysis of subcutaneous tissue deposits around chronic wounds in patients with Werner's syndrome was performed and compared to patients with peripheral arterial disease. Changes in calcium deposits in the Achilles tendon area on plain radiographs were observed and recorded over time in clinical cases. Lymphatic channels in the Achilles tendon area were also analyzed.

Results: The component of subcutaneous soft tissue calcification in Werner's syndrome was calcium phosphate, which was deposited in the lumen of the lymphatic vessels. There was a strong correlation between the amount of calcium deposition in the Achilles tendon area on the left and right sides, and in all 17 cases, the area of deposition increased over time, and according to the increase, the patients developed severe, difficult-to-heal ulcers in the Achilles tendon area that required surgical intervention. It was suggested that abnormalities in lymphatic flow in the Achilles tendon region exist in werner's syndrome.

Conclusion: Achilles tendon calcinosis in Werner's syndrome is always progressive, probably due to impaired lymphatic flow. Development of therapeutic approaches to calcification is required.

Oral Presentation | Free paper (Regenerative medicine)

P57**Preliminary Outcome of Herbal Extract Promotes Hair Regeneration by Enhancing M1/M2 Macrophage**Audry-Yun-Xuan Chan³, Chang-Cheng Chang^{1,2,3,4}, Tzong-Yuan Juang², Yi-Hsuan Su²¹ Division of plastic and reconstructive surgery, China Medical University Hospital, Taiwan² Department of Cosmeceutics, China Medical University, Taiwan³ Department of Medicine, China Medical University, Taiwan⁴ Aesthetic Medical Center, China Medical University Hospital, Taiwan

Background: Hair loss has become a concern. Recent studies suggest that M2 macrophage play a vital role in tissue repair and hair regeneration. Yet there is still lack of research to provide evidence for the role of M2 macrophage in hair regeneration. ON 101 ointment has been mentioned in previous studies to induce M1/M2 macrophage polarization and increase M2 macrophages. Therefore, we are using ON 101 in experiments to achieve an increase in M2 macrophages to promote hair regeneration.

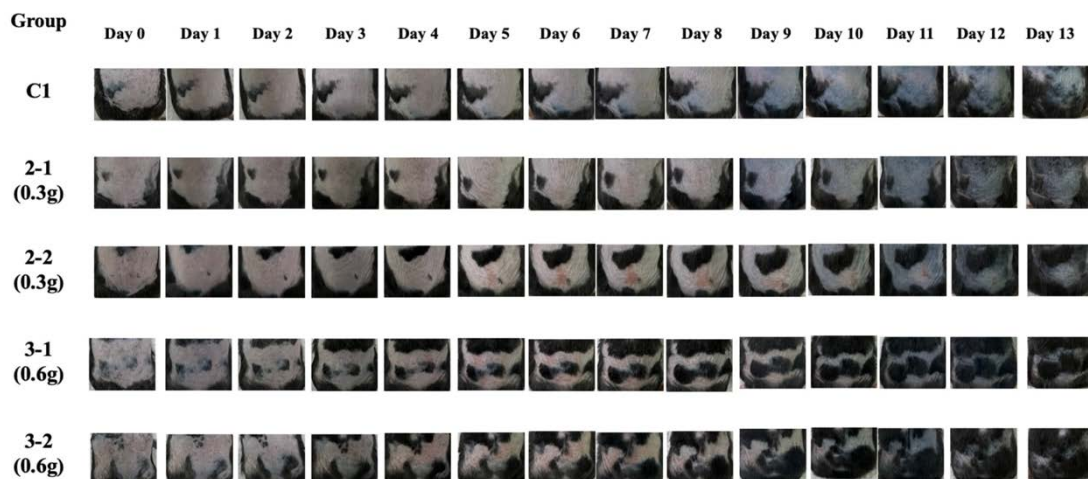
Objective: To explore herbal extract promotes hair regeneration by increasing M2 macrophage and investigate mechanism of M2 macrophage in hair regeneration.

Methods: C57BL/6 were divided into 3 groups randomly including (1) control group, (2) 0.3g ON101, (3) 0.6g ON101. Utilizing hair loss model by shaving and chemical depilation. Apply different two dosages of ON101 on mice back as the M2 macrophage-inducing agents and monitor hair growth in 2 weeks. H&E staining, Image J and dermatoscope were conducted to evaluate the effectiveness in hair regeneration.

Results: Compare to control group, treatment with the two different dosages of ON101 group has increased the hair growth significantly. H&E stain revealed that the higher dose of ON 101 showed stronger hair and the hair density was increased between two groups with different doses of ON 101.

Conclusion: In the preliminary experimental results, We find out that increase M2 macrophages by the mechanism of ON101 will enhance hair regeneration, which offers a therapeutic approach for hair loss conditions. Further research is needed to explore the underlying mechanisms. This has potentially leading to new clinical applications for hair loss patients.

Conditions of hair growth during 2 weeks



Oral Presentation | IPSRC Best paper session

P58

Single cell analysis toward further investigation of the pathogenesis of keloids.

Riho Takayanagi, Keisuke Okabe, Yukari Nakajima, Kazuo Kishi

Department of Plastic and Reconstructive Surgery, Keio University School of Medicine

Background: Keloids are fibrotic diseases that are triggered by skin damage and are characterized by the expansion of keloids beyond the area of skin damage into the surrounding normal skin. Although the cause of keloids is unclear, it is experimentally known that mechanical stress is involved. In this study, we performed single cell RNA sequencing (scRNA-seq) to investigate the pathogenesis of keloids, including mechanical stress and inflammation.

Methods: Keloid tissue and adjacent normal skin were collected with consent from four patients who underwent surgery at Keio University Hospital from July 2022 to September 2023. The samples were isolated into single cells and subjected to scRNA-seq.

Result: The keloid and normal skin cells were divided into 13 cell groups. Keloid tissue contained more vascular endothelial cells, mast cells, and Schwann cells than normal skin. Fibroblasts could be classified into four subclusters, characterized by an increase in mesenchymal fibroblasts in keloids. Regulatory T cells, which have been implicated in keloids in previous studies, were increased in keloids.

Discussion: These results may reflect angiogenesis and increased inflammation in keloids. The results for fibroblast subtypes are also consistent with previous studies and may contribute to fibrosis. Regulatory T cells suppress inflammation and are reported to be decreased in keloids, but their increase in keloids compared to adjacent skin may be related to the spread of keloids to surrounding normal skin.

Oral Presentation | Free paper (Breast)

P59

The Investigation of Therapeutic or Preventive Effects of Adipose Derived Stem Cells on Radiation Induced Capsular Contraction Around Implant in Mouse Model

Bolun Li, Kotaro Yoshimura, Sowa Yoshihiro

Jichi medical university

Background: Capsular contracture is a common and severe complication of breast reconstruction with breast implant, particularly in patients undergoing radiotherapy. Adipose derived stem cell (ADSC) has been reported to mitigate the capsular contracture around the implant.

Objective: This study aims to explore the effect of ADSCs on radiation-induced capsular contracture and its potential mechanisms.

Methods: 24 custom-made mini-implants were inserted into the dorsal side of 24 C57Bl/6 mice. All mice were divided into four groups, except control group, the rest 18 mice received fractionated radiation with a total dose of 40Gy to induce capsular contracture. 1-week post-radiation, group A received periprosthetic ADSCs injection, Group B received intraperitoneal ADSCs injection, Group C received periprosthetic solvent injection, and Group D served as the control with no injections. 180 Day after Radiation, all mice were sacrificed and examined grossly, histology and immunochemistry of periprosthetic tissue were also analyzed.

Results: The ADSCs injection groups showed less visible implant contour changes and a significant reduction in capsular thickness compared to the control group, which is confirmed by capsular histology. Furthermore, the expression levels of α -SMA and Collagen-I in the periprosthetic tissue of the ADSC injection groups were significantly lower than those in the control group.

Conclusion: Our research suggests that treatment with ADSCs can alleviate severe radiation-induced fibrosis and capsular contracture surrounding implants and the expression of α -SMA and Collagen-I in the periprosthetic tissue. This indicates the potential role of ADSCs for breast reconstruction using implants following breast cancer surgery, particularly for patients requiring radiotherapy.

Oral Presentation | IPSRC Best paper session

P60

A Novel Diagnostic Approach for Keloids Using Proton Nuclear Magnetic Resonance with Time-frequency Analysis of Serum

Guangpeng Xia¹, Teruyuki Dohi¹, Keiko Hirakawa^{2,3}, Mohamed Abdelhakim¹, Kaori Okihara², Nikki Terashi¹, Yoshimasa Kanawaku^{2,3}, Rei Ogawa¹

¹ Department of Plastic, Reconstructive, and Aesthetic Surgery, Nippon Medical School, Tokyo, Japan.

² Research Laboratory of Magnetic Resonance, Collaborative Research Center, Nippon Medical School, Tokyo, Japan.

³ Department of Legal Medicine, Graduate School of Medicine, Nippon Medical School, Chiba, Japan.

Background:

Keloid is a fibroproliferative skin disorder typically diagnosed through clinical features, lacking a specific diagnostic laboratory test.

Objective:

To evaluate the effectiveness of proton nuclear magnetic resonance (NMR) measurement of serum followed by time-frequency analysis in differentiating keloid cases from control subjects and identifying different stages/forms of keloids.

Methods:

Consecutive keloid patients were recruited prior to planned resection surgery and classified into character like Hypertrophic scars (HSs), character like Keloids (moderate and severe subgroups) based on the Japan Scar Workshop Scar Scale. Controls were recruited through convenience sampling. Serum samples underwent proton NMR and time-frequency analysis, followed by partial least-squares discriminant analysis (PLS-DA).

Results:

Seventy-four individuals (54 keloids and 20 controls) were enrolled. The PLS-DA score plots clearly demonstrated that the NMR-based approach could differentiate cases from controls, hypertrophic scar-like cases from keloid cases, and moderate-keloid cases from severe-keloid cases. Marked separation was observed between keloid and control groups, explaining 85% and 13% of the variance, respectively ($R^2=0.997$, $Q^2=0.958$). Fifty-four patients with character like HSs and character like keloids accounted for 68% and 30% of the variance, respectively, ($R^2=0.998$, $Q^2=0.970$). Twenty-four patients with moderate and severe keloids accounted for 98% and 2% of the variance, respectively, with notable separation ($R^2=0.979$, $Q^2=0.949$).

Conclusion:

Proton NMR measurement of serum followed by time-frequency analysis may serve as a diagnostic and prognostic tool for keloid cases. Further studies with larger samples and longitudinal design are needed to validate this approach.

Oral Presentation | Free paper (Nerve)

P61

Early Results of Optimized Nerve Management with Electrical Stimulation for Lower Extremity Neuroma

Jesse Chou, Janice Choi, Minton Cooper, Joseph Park, Bobby Chhabra, Brent DeGeorge

University of Virginia

Background: Nerve injury is the most common complication following foot and ankle surgery, with painful neuroma reported in up to 10% of procedures. Current treatment often yields varying degrees of pain relief. Electrical stimulation (ES) through peripheral neuromodulation is an emerging technology associated with improvement in nerve-related pain and acceleration of neural regeneration.

Objective: To assess the short-term outcomes of combining nerve reconstruction techniques with ES in providing early pain relief for patients with symptomatic lower extremity neuromas.

Methods: We describe a single-institution, prospective, cohort study including adult patients with lower extremity neuroma subjected to a nerve management procedure (neurolysis, targeted muscle reinnervation, or nerve allograft reconstruction) with concomitant peripheral nerve stimulator placement. Patients were treated postoperatively with ES (phase duration: 100uSec, pulse rate: 80 Hz) for 4 hours daily. Patient demographics, surgical details, and outcomes data were evaluated.

Results: Eight female patients (mean age: 49±13 years) were included. Peripheral nerve injuries were identified at the following locations: sural nerve (n=5), medial plantar nerve (n=1), tibial nerve (n=1), superficial peroneal nerve (n=2), and saphenous nerve (n=1). Mean Brief Resilience Scale (BRS) was 3.11 ± 0.61. At 3 months post-intervention, NRS Pain scores decreased from a mean of 8.5 ± 1.2 to 1.5 ± 1.2, PROMIS Pain Interference scores decreased from 61.5 ± 3.4 to 53.7 ± 4.9, and PROMIS Pain Behavior scores decreased from 65.8±3.5 to 56.1±4.2.

Conclusion: Early results of optimized neurotherapy with electrical stimulation demonstrates improved short-term pain relief for patients with symptomatic lower extremity neuromas.

Oral Presentation | Free paper (Skin/ Burn/ Wound Healing 1)

P62

Social Determinants of Health Associated with Prolonged Time to Treatment for Non-Traumatic Upper Extremity Conditions

Jesse Chou, Graham Grogan, Perry Bradford, Christie Schaeffer,
Brent DeGeorge

University of Virginia

Background: Social determinants of health (SDH) are defined by the World Health Organization (WHO) as conditions in which people are born, grow, live, work and age. The aim of this study is to examine the association of SDH on time to treatment for common non-traumatic upper extremity conditions.

Objective: To examine whether social determinants of health (SDH) factors are associated with time to treatment in common non-traumatic upper extremity conditions.

Methods: A national insurance claims–based database with patient records from the Centers for Medicare and Medicaid Services was used for data collection. Patients with diagnoses of wrist arthritis, carpal tunnel syndrome, cubital tunnel syndrome, stenosing tenosynovitis, Dupuytren’s contracture, De Quervain’s Tenosynovitis, medial epicondylitis, lateral epicondylitis, and thumb basal joint arthritis between 2005 and 2014 were identified. Primary outcomes included average time to treatment. Secondary outcomes included demographic variables and social determinants including education, employment, and other social factors.

Results: We identified 7,535,621 patients with non-traumatic upper extremity conditions. 437, 093 patients had associated social determinants of health (SDH). SDH patients had higher rates of COPD, obesity, substance use, and depression. Patients with non-traumatic upper extremity conditions and social determinants of health were more likely to experience increased average time to treatment.

Conclusion: In patients with non-traumatic upper extremity conditions, social determinants of health are associated with higher times to treatment.

Oral Presentation | Free paper (Patient Safety/ Education/ Leadership)
P63
Handcrafted Artificial Vessels for Supermicrosurgical Training

Toko Miyazaki, Maya Kanasaki, Reiko Tsukuura, Takumi Yamamoto

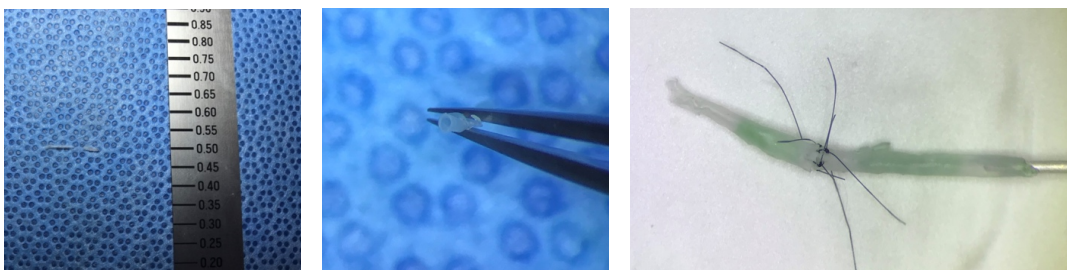
Department of Plastic and Reconstructive Surgery, National Center for Global Health and Medicine

Objective: In the field of reconstructive surgery, the technique of supermicrosurgery has enabled various kind of reconstruction, for example fingertip reconstructions and tissue transplantations using perforator flaps. However, a sophisticated supermicrosurgical skill is difficult to master especially for young surgeon before they experience many operations. Various living and non-living training models have been reported for supermicrosurgery, but none of them are perfect in terms of infectious risk and cost. We aimed to develop a new training material for supermicrosurgery.

Materials and Methods: Luminal structures or tubes were created using various materials including polyvinyl alcohol (PVA), polyvinyl acetate resin (PAR) and hydrocolloid (HC). Then we anastomosed the tubes and assessed patency with indocyanine green (ICG) injection. The characteristics of created tubes were recorded, and their feasibilities were evaluated by microsurgeons regarding anastomotic similarities to the real vessels and suitability for supermicrosurgical training.

Results: Average time and cost to create a 15-mm-long tube were 20.0 minutes (range, 50 seconds to 41 minutes) and 0.15 USD (range, 0.02 to 0.40 USD). Diameter of created tubes ranged from 0.35 to 2.00 mm (average, 0.71 mm). All the tubes could be anastomosed using 11-0 nylon with 15-micron needle. Anastomotic patency could be assessed in PVL tube and PAR tube (PART), whereas not in HC tube. Feeling of anastomosis in PART was most similar to that in the real vessels.

Conclusion: PART can be a training model alternative to previously reported training models, which allows supermicrosurgery practice with reduced infection risk and cost.



P64**Realization of XR technology applications in plastic and reconstructive surgery**

Kohei Mitsui^{1,2}, Mitsunaga Narushima¹, Banda Chihena¹, Kento Hosomi¹,
Chizuki Kondo^{1,2}, Kohei Hashimoto¹, Kosuke Yamagata^{1,2}, Kirito Kojima¹

¹ Mie University

² Aichi Medical University

【Objective】

The development of the XR (cross reality), multifunctional microscope and exoscope have led to reports of its application in surgery. The combination of the exoscope and smart glasses will provide an advantage in terms of education and surgical skill improvement. Simulations are also important in the fields of reconstructive and cosmetic surgery, and XR will play an important role here as well. We report on the research we are conducting to realize the clinical use of XR.

【Method and Results】

Microsurgery requires binocular vision of the projected image without blocking the field of view. We have already been able to perform vascular anastomosis using the exoscope (Orbeye®, Olympus, Japan) and smart glasses (MOVERIO BT-35E®, Epson, Japan) with a chicken wing in a face-to-face setting. The assistant could perform by projecting an image of the surgeon's field of view rotated 180 degrees. We also used exoscope and smart glasses during lymph venous anastomosis (LVA). The use of smart glasses would increase that variation compared to using monitors. In the simulation, the researchers are using a hologram software (Holoeyes®, Holoeyes, Japan) to simulate the reconstructed breast in patients undergoing breast reconstruction, with the goal of providing patients with a more realistic image of their reconstructed breast.

【Discussion】

However, there are still many issues to be solved to replace smart glasses alone, such as weight reduction, battery life, transmission speed, and price. After overcoming these challenges, the future of "one smart glass per person" following smartphones and wireless earphones will become a reality. After overcoming these challenges, the future of "one smart glass per person" following smartphones and wireless earphones will come true.

P65

Observation the skin at the site of pressure ulcers predilection using the sheet-type sensor

Tatsuya Kato, Hiroki Kajita, Yushi Suzuki, Kazuo Kishi

department of plastic and reconstructive surgery keio university school of medicine

Background: Pressure ulcers significantly reduce the QOL of patients and their families. Although various methods are currently being taken, pressure sore occurs in 20,000 patients every day in Japan. Preventive measure of their occurrence and worsening is vital.

Pressure sores are caused by a decrease in tissue blood flow due to prolonged external force. A combination of various risk factors such as reperfusion injury, displacement stress, friction, and skin infiltration is also important. To date, various studies have been conducted on pressure ulcers, but no reports have examined in detail the extent to which each risk factor affects the skin and how the skin reacts to each risk factor. This is because the monitor itself has a thickness and volume that interfere with the external force. The sheet-type sensor developed by Yokota et al. can be used for monitoring without interfering with external forces. We have observed mouse skin under pressure using the sheet-type sensor.

Objective: We investigated whether it is possible to observe the site of pressure sores in humans.

Methods: We applied a sheet-type image sensor to the preferred site of a pressure ulcers and observed changes in the skin in the sitting and lying positions. We also observed changes in the skin during the use of pressure-dispersing mattresses and cushions. We observed how the skin changed with pressure reduction and body movement.

Results: It was possible to observe the skin at the site of pressure ulcers predilection. The results suggest that the sheet-type sensor may be used to prevent pressure ulcers.

Conclusion: Currently, pressure ulcers is largely dependent on positional changes by nurses and caregivers, and complete prevention has not yet been achieved. The sheet-type sensor has shown the possibility of detecting risk by observing the skin under pressure, which has been difficult to do so far.

P66**Visualization of Chromosome-Specific Epigenetic Modifications for Fat Transplantation**

Yoshitaka Kubota, Kentarou Kosaka, Yoshihisa Yamaji, Shinsuke Akita,
Nobuyuki Mitsukawa

Chiba University

Introduction: Analyzing the properties of the cell groups within subcutaneous adipose tissue, which serves as the material for fat transplantation therapy, is crucial for maximizing therapeutic efficacy. However, epigenetic analysis, which is fundamental to cell function, has rarely been conducted. Using a platform capable of chromosome-specific analysis, we visualized the epigenetic state of subcutaneous adipose cells.

Methods: Human abdominal subcutaneous tissue was treated with collagenase and centrifuged. Ceiling culture cells (ccdPAs) were cultured for 7 weeks from the floating layer, and adipose-derived stem cells (ASCs) from the sediment layer. Among the epigenetic modifications, CpG methylation 450K assay and H3K4me3 ChIP-seq assay were performed. BigWig data were imported and analyzed using Subio Platform®.

Results: Of the RefSeq Genes in hg19, 64.9% had regions (Intervals) where H3K4me3 accumulated, indicating transcriptional regulation by H3K4me3. Additionally, 65.6% of these Intervals were located within 400 bp upstream or downstream of the transcription start site (TSS), suggesting transcription promotion. The peak values near the PPARG TSS were 16.2 for ASCs and 24.2 for ccdPAs. Similarly, the peak values near the RUNX2 P1 TSS were 21.5 for ASCs and 33.1 for ccdPAs, which corresponded with observations of cell differentiation capacity.

Among the H3K4me3 Intervals, 72.6% overlapped with CpG Islands. From the perspective of CpG Islands, 51.8% overlapped with H3K4me3. CpG Islands were more broadly distributed and were thought to regulate transcription independently or in combination with other histone modifications. Most CpG Islands overlapping with H3K4me3 had very low methylation rates, but occasionally, there were high methylation rates. This suggests an interesting coexistence of epigenetic modifications that act like transcriptional accelerators and brakes. Such unique overlaps were concentrated near chromosome ends, specifically near telomeres, and were rarely found near centromeres. Additionally, they were sparsely present on chromosome 1 but densely on chromosome 19.

Discussion: The era of large-scale data has also arrived for the analysis of cells in subcutaneous adipose tissue, but grasping the overall picture from the obtained large data is not necessarily easy. In this study, we were able to understand the epigenetic state of each chromosome. These results serve as a foundation for optimizing fat transplantation according to different objectives.

Oral Presentation | Free paper (Regenerative medicine)

P67

Regenerative effects of adipose-derived stem and its-extracellular vesicles on skin injury models

Kei Koizumi, Zhixiang Lin, Yoichiro Shibuya, Yukiko Imai, Junya Oshima, Kaoru Sasaki, Yukiko Aihara, Mitsuru Sekido

Department of Plastic and Reconstructive Surgery, Institute of Medicine, University of Tsukuba

Background:

Radiotherapy (RT) is one of three major treatments for malignant tumors. More than 50% of patients with malignant tumors undergo RT. Over 95% of patients undergoing RT may develop some form of radiation dermatitis or radiation-induced skin injury. This condition can affect the patient's quality of life during and after treatment. If severe, there is a risk of limiting the radiation dose or interrupting the treatment plan, which may negatively affect the treatment outcome.

Objective:

We established an *in vitro* and *in vivo* model of radiation-induced skin injury using human dermal fibroblasts (HDFs) and mouse, and examined and analyzed extracellular vesicles of adipose-derived stem cells (ADSC-EVs). We observed and evaluated the effects of ADSC-EVs on irradiated HDFs and murine wounds.

Methods:

Collagen gene expression was compared by qPCR to evaluate the *in vitro* models of radiation-induced skin injury established with HDFs and mice. Wound healing in the radiation-induced skin injury models by ADSC-EVs treatment was analyzed by gene expression, collagen synthesis and histological evaluation.

Results:

ADSC-EVs promoted wound healing *in vitro* and *in vivo* and collagen gene expressions were upregulated significantly.

Conclusion:

We established *in vitro* and *in vivo* model of radiation-induced skin injury and showed that ADSC-EVs play a beneficial role in the healing process; ADSC-EVs may be a promising therapeutic modality in the treatment of radiation-induced skin injury.

Oral Presentation | Free paper (Regenerative medicine)

P68

Regenerative effects of hiPSC-derived peripheral neuron/nerve progenitor on a nerve injury model

Kei Koizumi¹, Masahiro Sasaki^{1,2}, Yoichiro Shibuya¹, Zhixiang Lin¹, Junya Oshima¹, Kaoru Sasaki¹, Yukiko Aihara¹, Mitsuru Sekido¹

¹ Department of Plastic and Reconstructive Surgery, Institute of Medicine, University of Tsukuba

² Department of Plastic Surgery, Nional Hospital Organization Mito Medical Center

Background:

Research on peripheral nerve regeneration is lagging behind that of the central nervous system, but there are many patients and much progress is desired. Recently, human iPSC/ASC-derived induced peripheral neuron/nerve progenitor cells were developed by the National Institute of Advanced Industrial Science and Technology (AIST), Japan (Y Takayama, et al. Sci Rep. 2020 / Y Takayama, Y Shibuya, et al. PLoS ONE 2020). On the other hand, we have developed a murine model of facial nerve palsy which is advantageous, for example, for analysis using genetically engineered mice, modifying previously reported rat facial palsy.

Objective:

Using these cells and model, we launched an experimental system and project in collaboration with AIST to transplant iPSC-derived induced peripheral neuron/nerve progenitor (hiPSC-PN) into the mouse model of facial nerve palsy and evaluate their effect on peripheral nerve regeneration.

Methods:

In this pilot study, we evaluated the recovery of nerve function after transplantation of the iPSC-derived peripheral neuron/nerve progenitor cells into the mouse model of facial nerve palsy by evaluating nerve function which was facial palsy scale score evaluation modified by a previous paper and histological findings.

Results:

Weekly facial palsy scores were significantly improved in hiPSC-PN transplanted group than the control group after postoperative week 10. Facial nerve nuclei stained by a retrograde neuronal tracer dye Dil injected at whisker pad were detected more than the control group at postoperative week 14.

Conclusion:

Our results suggested that hiPSC-PN can be a therapeutic modality for peripheral nerve injury.

P69

Gelsolin released from macrophages is required for fibroblast migration during skin wound healing

Eri Toyohara^{1,2}, Fumiyuki Sasaki², Teruyuki Dohi¹, Rimpei Morita², Rei Ogawa¹

¹ Department of Plastic, Reconstructive and Regenerative Surgery, Nippon Medical School, Tokyo, Japan

² Department of Microbiology and Immunology, Nippon Medical School, Tokyo, Japan

Background: When skin is damaged, various kinds of cells migrate to the lesion and initiate wound healing process. In the inflammatory phase, neutrophils and macrophages infiltrate into the wound site to eliminate pathogens and prevent infection. In the proliferation and remodeling phases, fibroblasts and endothelial cells are activated and new granulation tissue is formed to fill the wound, which lead to re-epithelialization. Recently, we have identified that gelsolin, which is known as an actin-binding protein, as a novel negative regulator of NLRP3 inflammasome. Interestingly, gelsolin is abundantly secreted from macrophages along with NLRP3 inflammasome activation.

Objective: We aimed to clarify the role of macrophage-secreted gelsolin in wound healing.

Methods: We created macrophage-specific gelsolin conditional knockout (*Gsn*-cKO) mice and generated full-thickness excisional wound model. Re-epithelialization was observed every other day and we assessed the wounds with immuno-fluorescent staining. We also performed scratch assays using WT mice primary fibroblasts and recombinant gelsolin or *Gsn*-cKO mice bone marrow derived macrophages (BMDMs).

Results: *Gsn*-cKO mice showed reduced infiltration of α SMA or vimentin-expressing fibroblasts in the wound area, compared to control mice. Gelsolin-treated fibroblasts migrated faster than vehicle-treated fibroblasts. We also observed that co-culture of fibroblasts with LPS + nigericin-stimulated *Gsn*-cKO BMDMs led to faster migration than control BMDMs.

Conclusion: Macrophage-derived gelsolin is required for fibroblast migration during wound healing. Further investigation is required to clarify whether gelsolin has its receptor and what factors are involved in its signaling pathway.

P70

Pathological Analysis of Unstained Mouse Skin Tissue

Marika Otaki¹, Tatsuyuki Ishii¹, Yuta Asano², Mihoko Shimano², Imari Sato², Kazuo Kishi¹

¹ Department of Plastic and Reconstructive Surgery, School of Medicine, Keio University

² National Institute of Informatics

Background: Skin aging is characterized by fragmented and less dense collagen fibers in the dermis, along with disorganized fiber bundles. While there is currently extensive research on aging, skin thickness in the dermis is typically used as an evaluation of aging.

Objective: The objective of this study is to observe collagen fibers with a high degree of detail and elucidate the morphological alterations associated with aging. This investigation utilizes a proprietary high-frequency illumination microscopy analysis system to achieve precise observations and analyses.

Methods: Skin tissue was collected from the dorsal regions of young to aged mice, and observations were conducted using optical microscopy with Hematoxylin and Eosin staining, and electron microscopy. Unstained paraffin sections and TEM-fixed samples were examined with our system and compared with other images.

Results: Using a high-frequency illumination microscopy analysis system revealed distinct collagen bundles even in unstained conditions. Finer fibrous structures, presumed to correspond to collagen fibrils, were also observed. Comparison with SEM images showed similarities, indicating the potential to extract three-dimensional structural information from collagen bundles through this method.

Conclusion: While staining is typically performed to enhance structural clarity when observing paraffin sections under an optical microscope, our device allows observation without staining, eliminating the need for such procedures. Moreover, the potential to acquire structures previously masked by conventional staining suggests the possibility of conducting detailed morphological evaluations without electron microscopy. This method may contribute to establishing a technique for observing changes in collagen morphology in aging and scar.

Oral Presentation | Free paper (Regenerative medicine)

P71

Recent evaluation of cell assisted lipotransfer for soft tissue augmentation in our institution

Karen Sugai¹, Yoichiro Shibuya¹, Yukiko Imai¹, Kei Koizumi^{1,2}, Masahiro Sasaki¹, Yukiko Aihara¹, Kaoru Sasaki¹, Mitsuru Sekido¹

¹ Department of Plastic and Reconstructive Surgery, Institute of Medicine, University of Tsukuba

² Department of Plastic Surgery, Nional Hospital Organization Mito Medical Center

Background:

Cell-assisted lipotransfer (CAL) has emerged as a promising technique in aesthetic reconstruction, leveraging adipose-derived stem cells to enhance graft viability and contour restoration. This presentation aims to broaden understanding and utilization of CAL across diverse applications in aesthetic reconstruction. We present a case series showcasing the utility of CAL in various aesthetic deformities beyond breast reconstruction.

Objective:

Five patients underwent CAL for reconstruction. Cases included breast augmentation for congenital hypoplasia and concavity deformation after mastectomy and reconstruction using autologous tissue (3 cases), augmentation of congenital lower leg concavity (1 case), and post-tumor resection facial concavity (1 case).

Methods:

One CAL per patient was performed. Liposuction, stem cell isolation, and CAL were performed as per our protocol. Cell viability of transplanted SVF was evaluated using cell counter. Postoperative monitoring assessed outcomes and complications.

Results:

Cell viability of SVF was $90.74 \pm 5.5\%$. Across all cases, CAL demonstrated efficacy in enhancing volume and contour. Breast cases achieved improvements in size and shape with improved symmetry. In lower leg concavity correction, CAL resulted in relatively limited improvement in limb contour and symmetry due to its skin tension. Facial concavity correction exhibited remarkable aesthetic improvement post-CAL intervention. Complication was not appeared except pain.

Conclusion:

Our case series underscores the versatility and efficacy of CAL beyond breast reconstruction, showcasing its utility in addressing various deformities. CAL can offer reliable outcomes with minimal complications, natural-looking results and enhanced patient satisfaction.

E-poster

P72

Adipose-derived stem/stromal cells from young mice promote wound healing in aged mice through the regulation of ROS homeostasis by extracellular superoxide dismutase.

Toshihiro Fujiwara¹, Geoffrey Gurtner², Hisako Ishise¹, Kenichiro Kawai¹, Soh Nishimoto¹, Masao Kakibuchi¹

¹ Hyogo Medical University

² The University of Arizona

Background:

Excessive stress from reactive oxygen species (ROS) can impair the wound healing process. It has been reported that antioxidative ability decreases with age.

Objective:

Extracellular Superoxide Dismutase (SOD3) is a scavenger enzyme that regulates the degradation of superoxide, one of the ROS. We hypothesized that reduced expression of SOD3 in aged individuals may impair the efficacy of wound healing.

Methods:

Young wild-type, aged wild-type, and young SOD3 KO mice were used for all experiments. In the excisional wound healing model, wound closure time and levels of ROS stress in tissue samples were evaluated. Dermal fibroblasts and adipose-derived stem/stromal cells (ASC) were isolated and used to evaluate the potency of producing SOD3. Finally, in the excisional wound model of aged mice with ASC transplantation from young mice or SOD3 KO mice using collagen gel, the effect on wound healing was evaluated.

Results:

A decrease in the wound healing rate and an accumulation of ROS stress were observed in the in-vivo models of SOD3 KO and aged mice compared to young mice. Furthermore, extracellular ROS stress induced SOD3 protein expression in ASC of the young mice group more than in dermal fibroblasts. Finally, ASC transplantation from young mice, but not from SOD3 KO mice, reduced ROS stress levels in wound tissue and increased the wound healing rate in aged mice.

Conclusion:

We show that SOD3 may be a critical regulator of ROS stress in the wound healing process, especially in aging, and may contribute to the development of new therapeutic strategies.

E-poster

P73

A Report of Complications Associated with Cyanoacrylate Closure for Varicose Veins

Takayuki Ueda¹, Tatsuya Minakata¹, Yasuko Tanaka²

¹ Department of Plastic and Reconstructive Surgery, Osaka Saiseikai Neo Hospital

² Department of Plastic and Reconstructive Surgery, Kansai Medical University Hospital

Background:

The treatment of varicose veins began with stripping and high ligation. Endovenous thermal ablation (ETA) requires tumescent local anesthesia (TLA) and is associated with complications such as pain and subcutaneous bleeding. Cyanoacrylate closure (CAC) is a less invasive treatment that does not need TLA.

Objective:

VenaSeal Closure System (Medtronic, Minneapolis, USA), a new technique using CAC, was first approved by the US Food and Drug Administration (FDA) in 2015 and covered by health insurance in Japan since December 2019. The indication is for symptomatic primary varicose veins. Contraindications include a history of allergy to cyanoacrylate adhesives. Complications of CAC have not yet been widely reported, as clinical experience and data are accumulating.

Methods:

We have been performing stripping surgery for varicose veins since April 2014, ETA since July 2018, and CAC since July 2021. We conducted a retrospective study of CAC in 94 patients with 137 legs (116 great saphenous veins, 39 small saphenous veins) treated at our hospital from July 2021 to March 2024.

Results:

Postoperative complications such as phlebitis, allergy, and endovenous glue-induced thrombosis (EGIT) were observed. However, no serious adverse events such as deep vein thrombosis (DVT) and pulmonary thromboembolism (PTE) were observed. Ultrasound examinations were performed at 1 day, 1 month, and 3 months postoperatively.

Conclusion:

CAC is one of the treatments for varicose veins. We report a discussion of some relevant literature.

Oral Presentation | Free paper (Regenerative medicine)

P74

Using adipose-derived stem cells and its derivatives to promote regenerative medicine

Yoichiro Shibuya, Zhixiang Lin, Yukiko Imai, Kei Koizumi, Karen Saito, Yukiko Aihara, Kaoru Sasaki, Mitsuru Sekido

Department of Plastic and Reconstructive Surgery, Institute of Medicine, University of Tsukuba

Background:

Treatment options in various wounds and tissue defects include conventional reconstructive techniques as well as stem cell-based therapies, which have been increasingly studied in recent years. In order to increase therapeutic options, we have been developing stem cell-based therapies from the basic to the clinical level.

Objective:

In this presentation, we will describe our efforts to date to develop stem cell-based therapies to accelerate healing of hard-to-heal tissue at our institution.

Methods:

Adipose derived stem cell (ASC), its conditioned medium and extracellular vesicles (EV) were isolated and evaluated. *In vitro* and *in vivo* models of tendon, refractory skin ulcers and collagen lattice model of scar contraction were established. ASC and ASC-EV were applied to evaluate its regenerative effects.

Results:

Significantly accelerated tendon healing was observed in ASC -transplanted murine Achilles tendon model. Radiation ulcer models healed significantly faster and in better quality in ASC-EV treated group than in controls. ASC conditioned medium suppressed scar contractures in the *in vitro* collagen lattice model of scar contraction.

Conclusion:

ASC and its derivatives can be a promising treatment option when difficult treatments are anticipated.

P76

The Sweat Secretion in the Pedicled Volar Skin Flaps in Rats

Kyoichi Murakami, Kentaro Tanaka

Department of Plastic and Reconstructive Surgery, Graduate School of Medical Sciences, Tokyo Medical and Dental University

Background: Eccrine sweat glands, one of the skin appendages, have some important roles to maintain homeostasis: keeping body temperature stable, providing the skin with moisture, preventing bacterial infections, etc. Free tissue transfers often involve moving skin paddles, but there are few reports on the function of skin appendages in transferred tissue.

Objective: The purpose of this study is to investigate how the eccrine sweat glands function in transferred tissue and whether the factors, such as ischemic stress or reinnervation, influence the recovery of their function.

Methods: We established the method to elevate the volar skin as a pedicled flap and transplant it to the abdominal wall in Sprague-Dawley (SD) rats, because eccrine sweat glands exist only in the volar skin in rats. The sweat secretion in the flaps were assessed by iodine-starch sweat test.

Results: The sweat secretion were observed in innervated volar flaps (with tibial nerve), but not at all in denervated volar flaps (without tibial nerve). The innervated volar flaps which had suffered ischemic stress by the clamp of the perfusing vessels for three hours secreted almost the same amount of sweat as the innervated volar flaps without ischemic stress. The re-innervated volar flaps (with tibial nerve cut and sutured) began to sweat latter than the innervated flaps.

Conclusion: The flaps transferred into the recipient sites without cholinergic nerves don't seem to sweat. Ischemic stress doesn't seem to affect the flap sweating. Reinnervation makes flaps sweat even in recipient sites without cholinergic nerves.

P77

Mechanical isolation of adipose derived stem cells from fresh and cryopreserved: A Comparative analysis

Nur Azida Mohd Nasir¹, Sadia Farhana¹, Yew Chun Kai^{1,2},
Siti Fatimah Noor Mat Johar^{1,2}, Wan Azman Wan Sulaiman^{1,2},
Amirul Ashraf Ahmad Shan Wani^{1,2}

¹ Reconstructive Sciences Unit

² Hospital Universiti Sains Malaysia, 16150 Kubang Kerian, Kelantan

Background: Adipose-derived stem cells (ADSCs) have gained prominence as an ideal stem cell source. While enzymatic and mechanical techniques exist for ADSC isolation, mechanical methods are preferred for their cost-effectiveness, speed, and preservation of cell phenotypes despite yielding fewer cells. Developing efficient non-enzymatic techniques is crucial for clinical applications.

Objective: A comparative analysis of the yield quality of hADSCs, cell viability, and phenotypic preservation from fresh and cryopreserved tissue will be discussed in this presentation.

Methods: Adipose tissue samples were obtained from tissue blocks and lipoaspirates, with portions cryopreserved at varying temperatures and durations. The tissue was finely minced using scalpel blades and centrifuged to isolate the stromal vascular fraction (SVF). Cell viability was assessed using trypan blue exclusion and a hemocytometer. Flow cytometry was employed to verify and quantify hADSCs based on surface antigens CD29, CD34, CD73, CD90, and CD105. Differentiation assays into adipocytes, chondrocytes, and osteocytes were validated with Oil Red O, Toluidine Blue, and Alizarin Red staining, respectively.

Results: The mechanical isolation method successfully produced a substantial number of viable ADSCs from fresh adipose tissue and an adequate number from cryopreserved samples. The cells maintained their phenotypic characteristics and differentiation potential.

Conclusion: Mechanical isolation is an effective method for obtaining SVF and hADSCs from both fresh and cryopreserved adipose tissue, demonstrating its potential for autograft treatments. The ability to cryopreserve adipose tissue before isolating hADSCs allows for flexibility in timing, enhancing the practicality of delayed therapeutic interventions.

P78**Cytokine analysis of secondary lymphedema in patient with gynecologic cancer. A case-control study**

Hsiang-Wei Hu

Department of Plastic and Reconstructive Surgery, National Cheng Kung University Hospital

Background:

Lymphedema is most frequently caused secondary to cancer-related lymphadenectomy, radiotherapy and chemotherapy in developing countries. Secondary lymphedema accounts for 25~70% gynecological cancers patients. This condition is linked with chronic inflammation, tissue fibrosis, and adipose deposition. Due to the local inflammation observed as disease progression, we hypothesis that inflammatory cytokines profile may be different between lymphedema and non-lymphedema patients after cancer treatment. These cytokines may assist to identify development of secondary lymphedema in the future.

Objective:

To identify the cytokine profile in patients underwent gynecologic oncology surgery with and without secondary lymphedema over lower extremities.

Methods:

We enrolled 18 gynecological patients whom received gynecologic cancer surgery from 2018 to 2021 at National Cheng Kung University Hospital (NCKUH) for this case-control study. Nine patients with lower limb lymphedema after surgery are experimental group, whereas the other 9 patients without lower limb lymphedema after surgery are labeled as control group. Blood serum were collected and cytokine array analysis was done with semiquantitative protein profiling. Cytokine array images were analyzed using ImageJ software.

Results:

In cytokine array, 4 cytokines(CCL2, CCL4, CCL5 and angiogenin) were highly expressed in serum of all 18 secondary lymphedema patients as compared with the case group.

Conclusion:

The results suggest that CCL2, CCL4, CCL5 and angiogenin are the potential markers for developing secondary lymphedema.

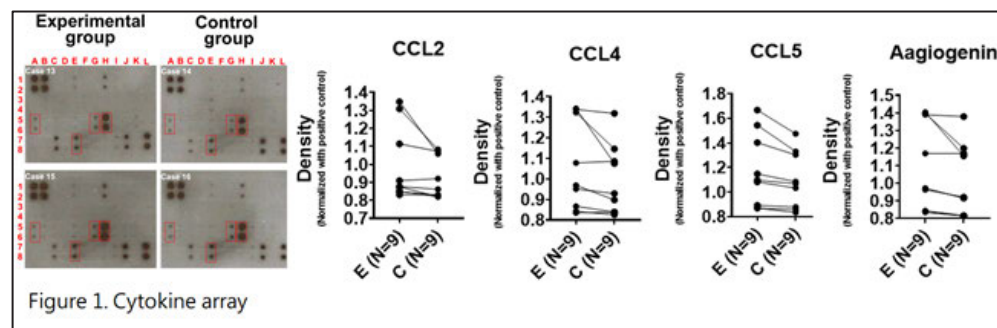


Figure 1. Cytokine array

P79

Eyelid in Morbihan disease is pathologically chronic lymphedema and super-microsurgical treatment can reduce the risk of the recurrence after skin excision

Shinsuke Akita¹, Kentaro Kajiya², Enkhtuul Gantumur², Kazuki Takagaki², Nao Itai², Nobuyuki Mitsukawa¹

¹ Department of Plastic, Reconstructive, and Aesthetic Surgery, Chiba University Graduate School of Medicine,

² Shiseido Co., Ltd., MIRAI Technology Institute, Yokohama, Japan

Background: Morbihan disease is an eyelid edema associated with histological abnormalities in the lymphatic vessels. We hypothesized that the pathogenesis of Morbihan's disease may be similar to that of secondary chronic lymphedema of the extremities.

Objective: The purpose of this study was to explore the clinical and histological similarities between Morbihan's disease and chronic lymphedema, and to examine the efficacy of the super-microsurgical lymphaticovenular anastomosis (LVA) to Morbihan's disease.

Methods: The histological differences including three-dimensional microstructures were examined in 5 patients diagnosed with Morbihan's disease by indocyanine green (ICG) lymphography and 5 patients with acquired ptosis of the eyelid as a control group. Postoperative recurrence rates were compared between the patients who underwent debulking surgery plus LVA (study group, n =7) and the patients who underwent debulking surgery (control group, n = 6) for Morbihan disease.

Result: The eyelid skin of the patients with Morbihan disease showed signs of changes in the microstructure of capillary lymphatic in the dermis, which is characteristic of chronic lymphedema in advanced stage. The recurrence rate within 1 year after surgery was significantly lower in the study group than in the control group (1/7 vs 5/6, respectfully, p = 0,03).

Conclusion: The Morbihan disease may be treated as a lymphedema of the eyelids in both pathologically and clinically.

P80

Risk of Congestive Heart Failure and Mortality Following Lymphovenous Anastomosis: A Nationwide Population-based Retrospective Cohort Study

Jeong Yeop Ryu, Joon Seok Lee, Kang Young Choi, Jung Dug Yang, Ho Yun Chung

Department of Plastic and Reconstructive Surgery, Kyungpook National University School of Medicine

Background: Lymphovenous anastomosis (LVA) enables lymphatic fluid to drain into the venous system. However, no study has investigated the association between LVA and heart failure (HF) caused by fluid overload in blood circulating system.

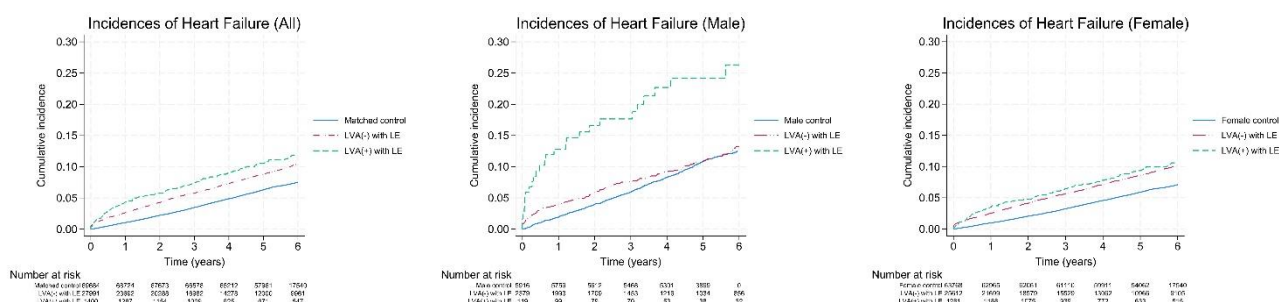
Objective: Purpose of our study was to determine whether LVA increases the risk of HF and mortality.

Methods: This nationwide study evaluated total of 1,400 lymphedema patients who underwent LVA and two control cohorts with 28,000 lymphedema who did not undergo LVA and 70,000 age- and sex-matched participants from the Korean National Health Insurance database were included. Other cardiovascular risk profiles and comorbidities were obtained during National Health Insurance Service – Health Screening. The incidence, adjusted risk for HF, and mortality were evaluated.

Results: Adjusted HRs for HF were 1.20 (confidence interval [CI], 1.03–1.40) and 1.30 (CI, 1.12–1.50) referenced by the general population control cohort and patients with lymphedema without LVA, respectively. In stratified analyses, the risk was notably greater in males compared to females, higher in younger individuals as opposed to older ones, and further elevated within the BMI range of 18.5 to 25.

Conclusion: LVA is associated with an increased HF risk, independent of cardiovascular risk factors and of associated comorbidities. This association is prominent in participants aged <50 years, in males, and in the normal-to-obese (BMI ≥ 18.5 kg/m²) group. Among patients with lymphedema, LVA did not significantly affect mortality.

Figure. Kaplan–Meier curves for the incidence of heart failure events in patients with lymphedema who underwent lymphovenous anastomosis and control cohorts. (A) all, (B) male, and (C) female.



P81

Macro-, Micro-, and Nano-Fat Grafting: Art, Philosophy, and Clinical Decision-Making

Chia-Chun Lee¹, Su-Shin Lee¹, Tsai-Ming Lin^{1,2}

¹ Department of Surgery, Kaohsiung Medical University Hospital, Kaohsiung, Taiwan

² Charming Institute of Aesthetic and Regenerative Medicine (CIARS), Kaohsiung, Taiwan

Background: Human autologous fat grafting has a robust 131-year history of clinical applications, extensively used in aesthetic, reconstructive, and regenerative surgeries. Its advantages include ready availability, biocompatibility, and an inherent lack of allergenicity, making it a preferred choice among surgeons.

Objective: This study aims to clarify and standardize the terminology related to macro-, micro-, and nano-fat grafting for clinical applications, enhancing understanding and consistency in clinical practice.

Methods: Utilizing principles of evidence-based medicine, this research involved an extensive review of literature spanning the past two decades, supplemented by a comprehensive meta-analysis, to accurately define the classifications of macro-, micro-, and nano-fat grafting.

Results: Our findings underscore that regardless of terminology, the success of fat grafting procedures hinges critically on meticulous attention to detail during the harvesting, processing, and transplantation phases. Effective manipulation of these stages is paramount for optimizing clinical outcomes.

Conclusion: Considering the dual demands of volumetric enhancement and tissue rejuvenation in fat transplantation, we advocate for micro-fat grafting, defined by graft parcel sizes between 1/60 and 1/240 mL. This approach significantly reduces potential morbidity and maximizes long-term outcomes in volume restoration and rejuvenation, eliminating the use of impractical terms and focusing on clinically actionable results.

Oral Presentation | Free paper (Regenerative medicine)

P82

Achieving the Balance in Autologous Fat Transplantation: Harmonizing Volumization and Rejuvenation

Hsiao-Chen Lee^{1,2}, Su-Shin Lee², Tsai-Ming Lin^{2,3}

¹ Division of Plastic Surgery, Department of Surgery, Kaohsiung Municipal Siaogang Hospital, Kaohsiung, Taiwan

² Division of Plastic Surgery, Department of Surgery, Kaohsiung Medical University Hospital, Kaohsiung, Taiwan

³ Charming Institute of Aesthetic and Regenerative Medicine (CIARS), Kaohsiung, Taiwan

Background: Autologous fat transplantation is a pivotal technique aimed at restoring volume deficits and achieving simultaneous tissue rejuvenation. These dual objectives are crucial for long-term maintenance and minimization of post-procedural complications.

Objective: This research assesses the long-term efficacy of the Micro-Autologous Fat Transplantation (MAFT) technique in facial fat grafting, specifically evaluating its capacity for volumetric enhancement and tissue rejuvenation.

Methods: We conducted a longitudinal study involving a cohort of patients over 50 years old, followed for a period of five to ten years. This study focused on the periorbital area and included a total of 350 cases to evaluate the enduring outcomes of fat transplantation.

Results: The findings revealed substantial improvements in periorbital hollows, crow's feet, prominent eye bags with/without lower eyelid laxity, and moderate baggy eyes with tear trough deformity/infra-orbital dark circle. Notably, these areas showed desirable long-term effects, contrasting with other regions affected by skin laxity, tear troughs, and dark circles, which did not exhibit similar improvements.

Conclusion: The MAFT technique has established itself as an effective, straightforward, and durable method in fat grafting. It not only ensures significant volume restoration but also enhances skin quality, evident in the marked reduction of wrinkles and dyspigmentation. These benefits underline the reliability and clinical value of MAFT, making it a commendable surgical approach for achieving lasting rejuvenation and volumetric results.

Oral Presentation | IPSRC APRAS award session 2

P84**Efficacy of treating diabetic chronic ulcers using adipose-derived stem cell-conditioned medium**

Sangchul Hyun, Yoshihiro Toyohara, Shino Higai, Saito Natsumi, Yoshihiro Sowa, Kotaro Yoshimura

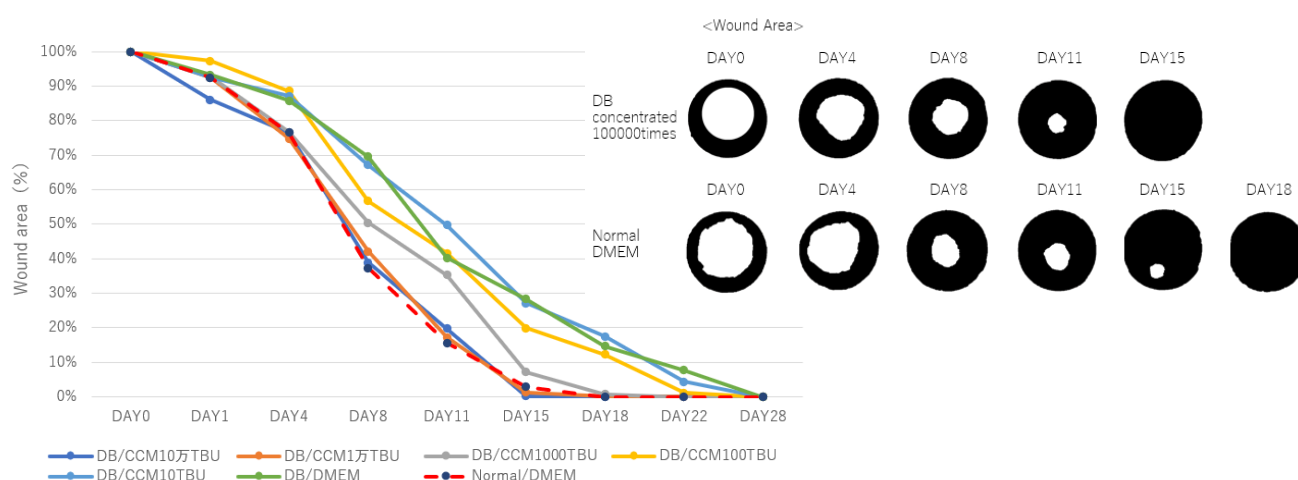
Department of Plastic Surgery, Jichi Medical University, Japan

【Background】 The number of patients with diabetic refractory ulcers is increasing in Japan. However, it is resistant to conservative treatment, such as traditional ointment application. Conditioned medium (CM) from adipose derived stem cells (ASCs) may have therapeutic effects on it.

【Methods】 A novel xeno-free medium was adopted to culture ASCs and get its CM. The ASC-CM's components of cytokines and growth factors were quantified. Then, wound was made by using biopsy punch on the dorsal skin of diabetic mice and ASC-CM with different concentrations was applied Locally (the group with ASC-CM concentrated 100,000 times, 10,000 times, 1,000 times, 100 times, 10 times, and DMEM group without ASC-CM, 6 groups) , while another group of healthy control was applied with DMEM during 14days. Skin samples harvested at day 28 were analyzed with histologic examinations.

【Results】 Comparing the groups applied with ASC-CM concentrated 100,000 times, 10,000 times, 1,000 times, 100 times, 10 times, and DMEM over 14 days (It was observed for 28 days), the higher the concentration of ASC-CM, the faster the wound healing rate in diabetic mice. In particular, the diabetic mice treated with the 100,000 times concentrated solution showed a wound healing rate almost identical to that of the healthy control mice.

【Conclusions】 The ASC-CM contained growth factors and cytokines and stimulate fibroblast proliferation. ASC-CM assist in wound healing and tissue regeneration in diabetic mice, and it was found that the higher the concentration, the more effective it is. This suggests that ASC-CM could be used as an effective tool for healing diabetic refractory ulcer and wound.



Oral Presentation | Free paper (Nerve)

P85**Micronized cellular adipose matrix (MCAM) promotes the therapeutic effect of an artificial nerve conduit in peripheral nerve gap injury**Seiji Sawai¹, Yoshihiro Sowa², Tsunao Kishida³, Shinji Tsuchida⁴, Ryo Oda⁴, Osam Mazda³, Kotaro Yoshimura², Kenji Takahashi⁴¹ Department of Orthopedic Surgery, Jyujiyo Takeda Rehabilitation Hospital² Department of Plastic and Reconstructive Surgery, Jichi Medical University³ Department of Immunology, Kyoto Prefectural University of medicine⁴ Department of Orthopedic Surgery, Kyoto Prefectural Univ of medicine

Background: The stromal vascular fraction (SVF) isolated from adipose tissue has been shown to be beneficial for treating peripheral nerve injuries. Micronized cellular adipose matrix (MCAM) is an SVF-rich micronized fat tissue obtained by a series of simple mechanical processes.

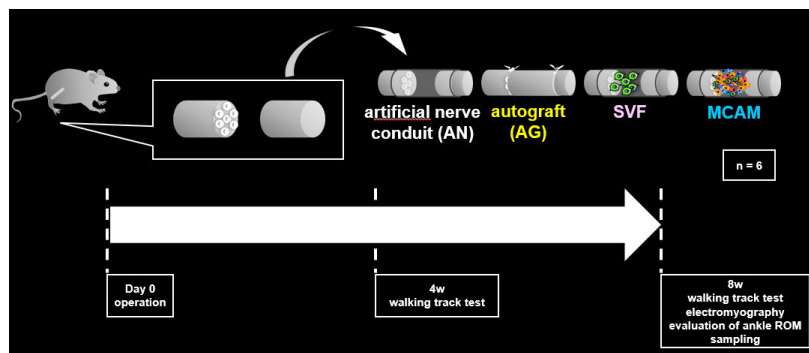
Objective: To assess the therapeutic effect of MCAM for peripheral nerve injury.

Methods: Microscopic evaluation of the cell phenotype was performed to determine the adipose-derived stem cell (ADSC) content of the MCAM. An artificial nerve conduit (ANC) filled with MCAM was implanted into a sciatic nerve defect in immunodeficient mice.

Comparisons of this treatment with an autograft, an ANC filled with SVF cells, and an ANC alone were made based on electrophysiologic characteristics, sciatic function index, histological analyses of regenerated nerve fiber and myelination using electron microscopy, and the preventive effect on innervated muscle atrophy.

Results: MCAM contained many cells with a phenotype and differentiation potency similar to ADSCs. The implantation experiment indicated that MCAM enhanced the efficiency of functional and structural recovery, while preventing atrophy of the innervated muscle. These effects were significantly improved than in the ANC alone group and comparable to those in the SVF group, whereas the improvement did not reach the same level of autograft group.

Conclusion: Injection of MCAM into an ANC accelerated nerve regeneration compared with use of an ANC alone and this effect, which indicate that MCAM is a promising transplant material for treatment of peripheral nerve injury and an alternative to use of SVF cells.



P86**Comparative study of fetal facial shape between Japanese and North American populations**

Motoki Katsube¹, Siddharth Vora³, Yutaka Yamagichi², Natsuko Utsunomiya^{1,2}, Joy Richman³, Virginia Diewert³, Naoki Morimoto³, Shigehito Yamada²

¹ Plastic and Reconstructive Surgery, Kyoto University Graduate School of Medicine

² Congenital Anomaly Research Center, Kyoto University Graduate School of Medicine

³ Oral Health Sciences, University of British Columbia

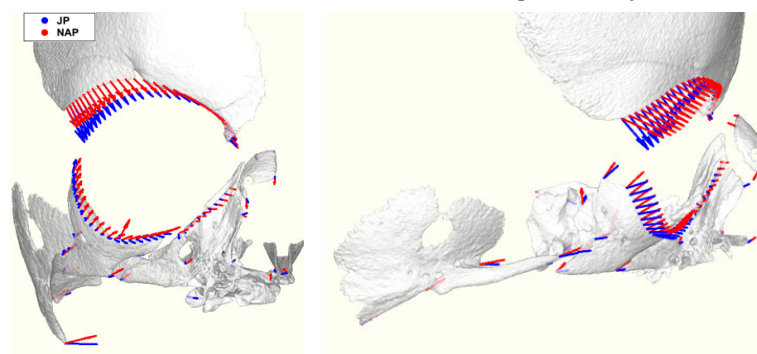
Background: Understanding population differences in human facial skeleton and the time during ontogeny when they arise, is of great interest. The facial shape may be determined during fetal development hence, population differences are presumed to occur in that period.

Objective: The aim of this study was to investigate the morphological population differences in shape and growth trajectories of the midface and the mandible during the middle trimester using 3D μ CT scans of human fetal specimens from Japan and Canada.

Methods: Twenty-two preserved conceptuses from the Congenital Anomaly Research Center at Kyoto University and 20 from University of British Columbia, with a CRL ranging from 99 to 198 mm, were imaged using μ CT scans. The midfacial skeletons and the mandible were digitally segmented. Landmarks and semi-landmarks on the surfaces were digitized. A generalized Procrustes analysis and a principal component (PC) analysis were performed. To evaluate the shape difference between Japanese (JP) and North American populations (NAP), multivariate analysis of variance and linear discriminant (LD) analysis were utilized. Growth trajectories for each population were calculated from the multivariate regression and drawn in PC space. The shape changes along LD axis and allometric vector were visualized.

Results: Statistically significant shape differences were noted in the midfacial skeleton ($p < 0.01$) between JP and NAP. The LD axis demonstrated that the area with the most difference was the upper orbit. Notably, the distinct orbital growth trajectories for the Kyoto and UBC specimens were already established in the smallest specimens and gradually increased with growth during the period investigated here (figure). The mandible did not show significant shape differences between JP and NAP.

Conclusion: A significant shape difference in midfacial skeleton already exists at the second trimester between JP and NAP. Furthermore, this difference gradually increases with growth.



P87

Different Timing of Nanofibrillar Collagen Scaffold Implantation Affects the Lymphangiogenesis in Splinted Hindlimb Lymphedema Mouse Model

Joceline Theda Kadarman, Shinsuke Akita, Nobuyuki Mitsukawa

Department of Plastic, Reconstructive, and Aesthetic Surgery, Chiba University, Japan

Background: Secondary lymphedema is a common disorder associated with acquired functional impairment of the lymphatic system. BioBridge™ is a highly aligned nanofibrillar collagen scaffold with promising results in various preclinical and pilot clinical studies. It induces both angiogenesis and lymphangiogenesis in rat and pig lymphedema models. However, different implantation timing of BioBridge™ and the effect on the lymphedema progression in a splinted hindlimb lymphedema mouse model have not been observed.

Objective: to investigate the effect of different implantation timing of BioBridge™ from the affected hindlimb to the unaffected contralateral side in a splinted hindlimb lymphedema mouse model.

Methods: Splinted hindlimb lymphedema was created by removing inguinal and popliteal lymph nodes and closing the incision with silicon splinting. A 3,5 cm length BioBridge™ was implanted 1 day (early implantation) and 7 days (late implantation) after the lymph node resection surgery. Hindlimb circumference (6 mm from the heel) was measured every 3-4 days and ICG lymphography was performed weekly. After 28 days, mice hindlimbs were sacrificed for histological analysis.

Results: Compared to late implantation, early implantation of BioBridge™ showed better results in reducing the hindlimb circumference of the affected side. After 28 days, BioBridge™ was still observed in the same position, and regeneration of new lymphatic vessels was observed inside it which was confirmed by anti-LYVE-1 immunohistochemistry staining.

Conclusion: Early implantation of BioBridge™ prevented lymphedema from reaching a severe stage. Therefore, early implantation of BioBridge™ in the clinical setting should be considered.

P88

Weekday Timing and Surgical Outcomes: The Impact of Surgery Day on DIEP Flap Success

Cole Holan, Alex Pazelli, Jorys Martinez

Mayo Clinic

Background

The timing of surgical procedures is known to influence clinical outcomes in various procedures, but its impact on Deep Inferior Epigastric Perforator (DIEP) flap surgeries remains uncertain.

Objective

This study aims to investigate whether the day of surgery affects the clinical outcomes of DIEP flap surgeries.

Methods

This retrospective chart review included patients aged 18 years and above who underwent DIEP flap surgery. Patients were divided into two groups: Group 1 had surgery on Monday and Thursday, while Group 2 had surgery on Wednesday, Thursday, and Friday. Statistical analyses included the Shapiro-Wilk test, Independent Student's t-test, and Chi-square test, with a p-value of less than 0.05 considered statistically significant.

Results

A total of 183 DIEP flap cases were included. Group 1 had 114 patients, and Group 2 had 69 patients. The mean lengths of surgery and anesthesia in Group 1 were 8.78 hours and 9.78 hours, respectively, compared to 8.13 hours and 9.10 hours in Group 2. The average lengths of stay were 3.74 days for Group 1 and 3.68 days for Group 2. Complications occurred in 36.84% of Group 1 and 27.53% of Group 2. Eight flap losses were reported, with Group 2 experiencing more flap losses ($p < 0.001$).

Conclusion

Our study demonstrates that the day of surgery is related to worse outcomes. Undergoing DIEP flap surgery closer to the weekend is associated with a higher risk of flap loss. Further prospective studies with larger sample sizes are required to confirm our findings.

Oral Presentation | Free paper (Regenerative medicine)

P89

The role of versikine/versican in dermal papilla

Noriko Aramaki-Hattori¹, Suneel Apte², Keisuke Okabe¹, Shigeki Sakai¹, Kazuo Kishi¹¹ Keio University School of Medicine² Department of Biomedical Engineering, Lerner Research Institute, Cleveland Clinic

Background and Objective: Extracellular matrix versican was reported to play an important role in mesenchymal condensation in mice hair and hair induction, and thereafter, similar results were reported in humans. We investigated versican degradation in the hair cycle of C57BL/6 mice, studying the effects of versikine, a versican degradation product, on dermal papilla cells. **Methods:** C57BL/6 mice whiskers and pelage were collected, and frozen sections prepared. Versikine was immunostained. The ADAMTS (a disintegrin and metalloproteinase with thrombospondin motifs) family comprises proteases that can degrade versican. Skin from 1-day-old ADAMTS1 and ADAMTS9 knockout mice was used to investigate ADAMTS expression in papilla cells using LacZ staining. Dermal papilla cells were isolated from the whiskers of C57BL/6 mice, and expression of Adamts-1,4,5,9 was investigated by RT-PCR assay. In addition, to study its effect on hair papilla, versikine was added to isolated papilla cells and the proliferative ability of the dermal papilla cell was investigated. **Results:** The dermal papilla cells in mice skin during anagen phase were positive for versikine immunostaining, but not during the catagen phase. LacZ immunostaining showed ADAMTS1 and ADAMTS9 expression at the dermal papilla cells suggesting that versican degradation had occurred. Isolation-cultured dermal papilla cells revealed *Adamts* expression by RT-PCR. In cell proliferation assay, the versikine-added dermal papilla cells group, a significant increase in proliferative ability was compared to control group. **Conclusions:** Our findings suggest that versican is degraded by ADAMTS molecules in the dermal papilla cell, and produces versikine, thus affecting the proliferation of dermal papilla cells.

Oral Presentation | IPSRC Best paper session

P90

Potential benefit of vascularized lymph node transfer on cancer progression

Erika Guilpain Kusajima^{1,2}, Taku Maeda², Kosuke Ishikawa², Takahiro Miura², Emi Funayama², Yuhei Yamamoto²

¹ Department of Plastic Surgery, Caress Sapporo Tokeidai Memorial Hospital

² Department of Plastic and Reconstructive Surgery, Faculty of Medicine and Graduate School of Medicine, Hokkaido University

Background: Lymphedema is considered to increase the risk of cancer progression. Recent reports have indicated that vascularized lymph node transfer (VLNT) may improve the impaired immunity in lymphedema but there has been limited number of reports concerning anti-cancer immunity.

Objective: This study aims to explore the effects of VLNT on the dynamics of early tumor immune response in mouse models.

Methods: Forty-seven 8-week-old C57BL/6N male mice were divided into three surgical groups: VLNT involving transferring a vascularized inguinal lymph node flap post-popliteal lymph node removal, popliteal lymph node dissection model, and control. Postoperative lymphatic flow was monitored with indocyanine green lymphography, and B16-F10-luc2 melanoma cells were implanted in the ipsilateral footpad. The proportion of dendritic cells in the transplanted nodes was assessed by CD11c immunohistochemistry, and metastases to the lungs and lymph nodes were evaluated quantitatively by luciferase assay.

Results: After VLNT, lymphatic reconnection was observed in 59.2% of mice. The proportion of dendritic cells was significantly higher in the VLNT group with lymphatic reconnection than in the naïve lymph node. The tumor burden of lung metastases was significantly less in the VLNT group with lymphatic reconnection compared with the lymph node dissection group.

Conclusion: Metastasis decreased in mice with reconnected lymphatics after VLNT. A possible explanation was that lymphatic restoration may have contributed to the tumor immune response by allowing dendritic cells migration to lymph nodes.

P91

Unveiling the three-dimensional vascular architecture of keloids using tissue-clearing techniques

Long Nguyen¹, Teruyuki Dohi¹, Haruko Takano², Shigetomo Fukuhara²,
Rei Ogawa¹

¹ Department of Plastic, Reconstructive, and Aesthetic Surgery, Nippon Medical School, Tokyo, Japan.

² Department of Molecular Pathophysiology, Institute of Advanced Medical Sciences, Nippon Medical School, Tokyo, Japan

Background: Tissue opacity is primarily attributable to the absorption and scattering of light, which prevents our awareness of the actual 3-dimensional structure. Tissue-clearing techniques have advanced in recent years in various medical fields, using both human and animal samples. In this study, we applied tissue-clearing techniques for the first time on scar tissue to detect the atypical structure of keloid, especially focusing on its vascular structures.

Methods: During the clearing process, chemical treatments were used to eliminate light-blocking and light-scattering components; then, antibodies were employed to detect structural abnormalities in keloid vessels. Finally, the samples were immersed in a clearing liquid to obtain a uniform refractive index and acquire transparency.

Results: Skin and scar samples were successfully rendered optically transparent. Changes in the histological morphology of keloid blood vessels, such as density, diameter, number of branches, and branching points, were verified using highly accurate 3-dimensional images. The values were as follows: density ($19.7 \pm 9.3\%$), diameter ($12.3 \pm 3.5 \mu\text{m}$), number of branches/ μm (1.4×10^{-2}), and branching points/ μm (0.7×10^{-2}). The vascular characteristics and associated factors in different structural regions of normal skin and keloid scars also showed substantial variations.

Conclusion: This study investigated keloid vascular characteristics using tissue-clearing techniques, revealing the distinctive vascular structure in keloids. The findings suggest that the development of these characteristic blood vessels plays a crucial role in keloid formation and may be associated with its pathogenesis.

P92**Optimizing scarless double chin treatment: Systematic plan through combining surgical, energy based, and manual techniques**

Dina M Badawi

Cairo university

Background: The importance of a tightened sculptured neck and submental region is highlighted nowadays in the trending selfie photos. Surgical liposuction of submental fat may address one component of the double chin problem, other components like loose skin and sluggish lymphatic circulation need attention.

Objective: Evaluating the impact of applying manual lymphatic massage and radiofrequency energy to the submental area following surgical liposuction on aesthetic outcome, patient's satisfaction, and safety.

Methods: A prospective study included patients seeking scarless treatment for double chin deformity. Our plan involved three subsequent steps: PAL of submental fat, manual lymphatic massage, and radiofrequency energy. Follow up continued for 6 months. At each visit, photos were taken, complications were recorded, and visual analogue scales were used to evaluate the pain and patient satisfaction.

Results: 42 patients were included, mean age 38.1. Complications reported were edema, pain and transient marginal mandibular nerve paralysis. The pain scores were highest on the first visit. The mean satisfaction score on the final visit was 8.76 (Fig.1). None of the patients asked for further surgical neck lift.

Conclusion: Adding manual lymphatic massage and radiofrequency energy to the submental area in the early post-liposuction period may be considered a satisfactory, simple, reproducible, rapid, and safe plan for scarless neck rejuvenation.

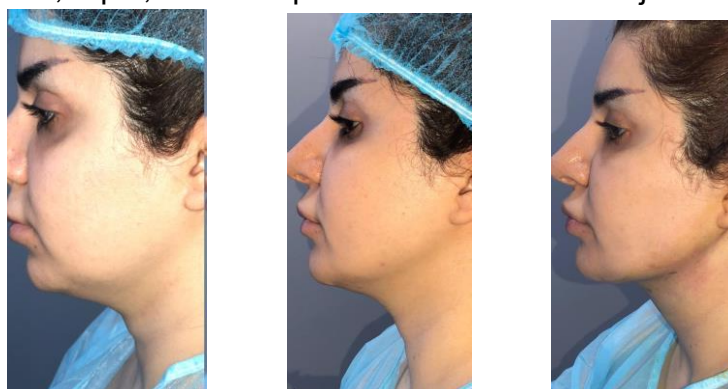


Fig. (1): A: Before liposuction of double chin. B: after performing PAL of submental fat. C: After completion of manual massage and radiofrequency

Oral Presentation | Free paper (Nerve)

P93

Electrical stimulation and its effects on sympathetic regeneration after peripheral nerve injury

Tina Tian^{1,2,3}, Patricia J. Ward^{2,3}

¹ Medical Scientist Training Program, Emory University School of Medicine, Atlanta, GA USA

² Neuroscience Graduate Program, Laney Graduate School, Emory University, Atlanta, GA, USA

³ Department of Cell Biology, Emory University School of Medicine, Atlanta, GA USA

Background: Peripheral nerve injuries (PNIs) are common, and the current standard of care relies on the slow and inefficient process of spontaneous regeneration. Electrical stimulation (ES) enhances motor and sensory regeneration; however, its effects on sympathetic regeneration is unknown.

Objective: Understand the acute and long-term effects of ES on sympathetic regeneration.

Methods: To study acute ES effects, 1 hour, 20 Hz stimulation was applied to transected and repaired mouse sciatic nerves. ES was compared to a conditioning lesion (CL) and sham. Axonal regeneration was evaluated after 2 weeks via immunohistochemistry.

To study long-term ES effects, sweating recovery was tracked with a pilocarpine assay for 12 weeks after sciatic nerve transection, with and without ES. Reinnervation of the most distal sweat glands was assessed via immunohistochemistry, and neurons reinnervating the foot and tibialis anterior (TA) were fluorescently labeled. Purines in the gastrocnemius were quantified using high-performance liquid chromatography to evaluate mitochondrial metabolism.

Results: ES and CL do **not** enhance sympathetic regeneration but do enhance motor/sensory regeneration acutely. ES does not improve long-term sweating recovery and may decrease reinnervation of the most distal sweat glands. ES improves motor/sensory reinnervation, but **not** sympathetic reinnervation, of the foot. Motor/sensory reinnervation of the TA is nearly complete by 12 weeks, but sympathetic reinnervation remains **incomplete**. Finally, ES does not improve injury-related mitochondrial metabolism deficits.

Conclusion: ES does not enhance sympathetic regeneration. Despite the return of motor reinnervation of more proximal muscles 12 weeks post-PNI, alterations in mitochondrial metabolism persist, likely due to decreased sympathetic reinnervation.

P94

Sustained BMP-2 Release by Peptide Amphiphilic Nanofibers Enhances Craniomaxillofacial Bone Regeneration by Mitigating Early Inflammatory Response

Akishige Hokugo¹, Zachary Brooks¹, Nathan Sigel¹, Taro Inagaki¹, Satomi Arimoto¹, Samuel I. Stupp^{2,3,4,5,6}, Reza Jarrahy¹

¹ Regenerative Bioengineering and Repair (REBAR) Laboratory, Division of Plastic and Reconstructive Surgery, Department of Surgery, David Geffen School of Medicine, University of California Los Angeles

² Simpson Querrey Institute for BioNanotechnology, Northwestern University

³ Department of Materials Science and Engineering, Northwestern University

⁴ Department of Chemistry, Northwestern University

⁵ Department of Medicine, Northwestern University

⁶ Department of Biomedical Engineering, Northwestern University

Background: Bone morphogenic proteins (BMPs) are pivotal in craniomaxillofacial surgery for bone reconstruction. However, their side effects, such as severe edema and local inflammation, limit their use. Nanoscale peptide amphiphiles (PAs) self-assemble into nanofibers and can act as sustained-release carriers for biological molecules, supporting tissue regeneration.

Objective: This study investigates the impact of PA gels on the osteogenic differentiation of bone marrow stromal cells (BMSCs) in vitro and bone repair and inflammation in craniomaxillofacial bone defect models in vivo.

Methods: BMP2 release from PA gels was analyzed. Human BMSCs were treated with growth medium or medium containing BMP-2 and PAs. Osteogenic differentiation was assessed using quantitative RT-PCR for osteogenesis-specific genes. Bone defects were created in rabbit calvaria and rat maxilla and treated with collagen material containing BMP2 with or without PA gels. Control groups included collagen material only. Bone tissue and surrounding soft tissue were harvested for radiographic and histologic analyses and inflammation-related gene expression. Immunohistochemical (IHC) staining was performed for inflammatory responses.

Results: BMP2 was released from PA gels in a sustained manner, significantly increasing osteogenic activity in BMSCs compared to controls. In bone defect models, collagen with low-dose BMP2 incorporating PA gels showed robust bone regeneration, comparable to high-dose BMP2 without PAs. Inflammatory markers were elevated in high-dose BMP2 groups but normalized in groups treated with BMP2 incorporating PAs, consistent with IHC findings.

Conclusions: PAs with low-dose BMP2 may be a viable alternative to high-dose BMP2 in craniofacial surgery, offering reduced inflammation and effective bone regeneration.

P95**Artificial Intelligence and Patient Information: Assessing Utility of ChatGPT for Patient Information on Lymphedema and Lipedema**

Luis Antezana MD¹, Anab Mohammed BS², Austin Chen MD¹,
Cole Holan MD, MBA¹, Jorys Jorge Martinez¹, Karim Bakri MBBS¹

¹ Division of Plastic and Reconstructive Surgery, Mayo Clinic, Rochester, MN, 55902

² Mayo Clinic Alix School of Medicine, Rochester, MN, 55902

Background

Artificial intelligence (AI) chatbots like ChatGPT have potential as search engines and sources of patient information.

Objective

To evaluate readability and accuracy of lymphedema and lipedema information from ChatGPT compared to the Lymphatic Education and Research Network (LERN).

Methods

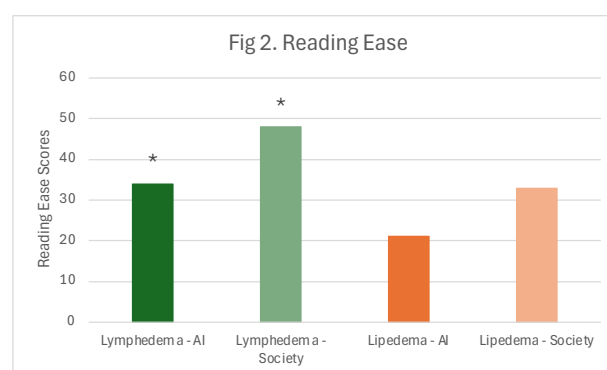
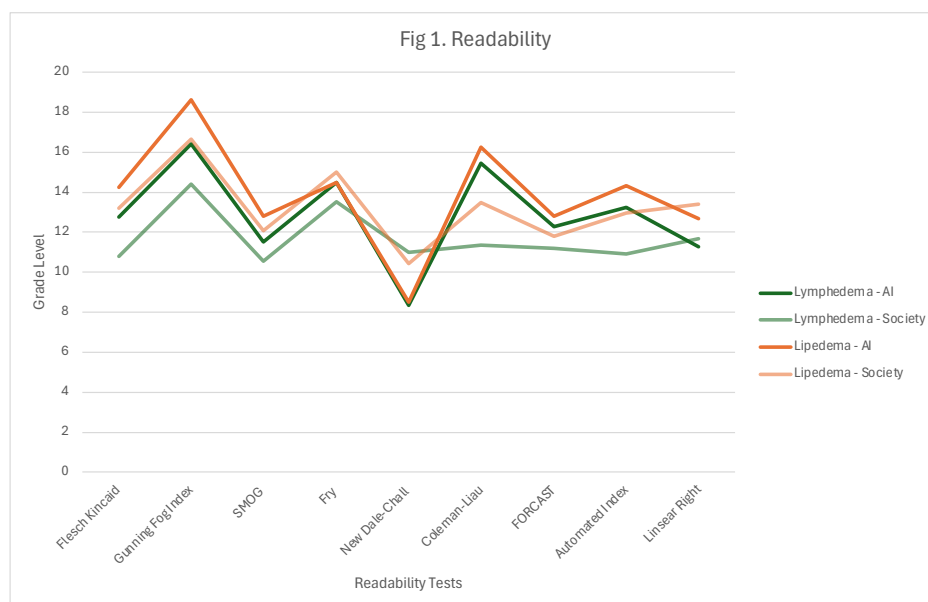Answers to 28 FAQs from LERN and ChatGPT outputs were analyzed using 10 readability tests. Readability & Ease scores were compared using independent t-tests. Fig 1. & 2. Accuracy was assessed by subjective comparison to LERN information.

Results

The mean reading grade level for lymphedema and lipedema patient information extracted from the LERN website was 11.7 at the high school junior grade level and 13.2 at the entry college level respectively. The mean reading ease score was 48 and 33 at the difficult level respectively. The mean reading grade level for lymphedema and lipedema information extracted from ChatGPT was 12.86 at high school senior grade level and 13.85 at the entry college level. The mean ChatGPT reading ease scores was 34 (lymphedema) and 21 (lipedema), falling in the difficult/very difficult categories. There was a significant difference in both reading grade level and reading ease ($p < 0.05$) between LERN and ChatGPT extracted lymphedema information, but no difference in lipedema patient information. The ChatGPT text was accurate although shorter in length and scope. Further queries yielded more comprehensive information.

Conclusion

While above average reading levels, ChatGPT lymphedema information was significantly more difficult than LERN's. Integrating readability measures and verification into AI outputs may improve their usefulness for patient queries as these technologies are adopted.



Oral Presentation | Free paper (Aesthetic/ Gender/ Cancer)

P96**Institutional Experience of Female Perineal Reconstruction Post-EMPD - A Rare Entity's Reconstructive Challenge**

Luis Antezana, Nicole Sanchez Figueroa, Kelly Bruce, Cilby Williams, Christin Harless, Nho Tran, Aparna Vijaysekaran, Jorys Jorge Martinez

Division of Plastic and Reconstructive Surgery, Mayo Clinic, Rochester, MN, 55902

Background

Female perineal extramammary Paget's disease (EMPD) is a rare condition requiring multidisciplinary management. Previous research showed margin-controlled surgery improved outcomes for female genital Paget's disease compared to traditional excision.

Objective

This study aims to analyze demographics, surgical interventions, and complications in vulvo-perineal EMPD patients undergoing wide local excision (WLE) or Mohs resection followed by reconstruction.

Methods

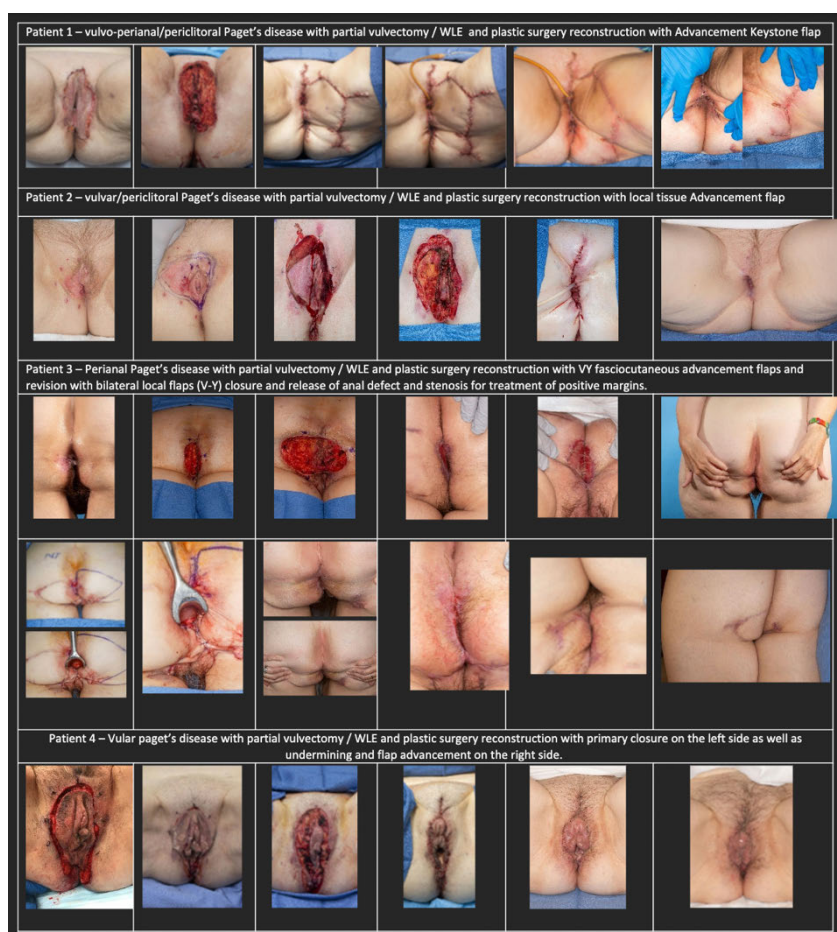This observational trial enrolled adult patients with histologically confirmed female genital EMPD. Relevant data were collected and analyzed.

Results

62 patients were identified (mean age 66, 97% Caucasian). Vulvar lesions were most common (76%), followed by perianal (33%), periclitoral (17%), and vaginal (6%). 56% had lesions in only one area.

Partial vulvectomy/WLE was the predominant excision (79%). Advancement flaps were the most used reconstruction (48%), followed by rotational flaps, skin grafts, and primary closure. Mean lesion size for flap reconstructions was 15x12cm. 85.7% involved radical vulvectomy and 73% had multifocal lesions.

Reconstructions were typically performed simultaneously with excision. One case deferred reconstruction using Integra® for later skin grafting due to indeterminate biopsy borders. Complications included wound separation (43%), surgical site infection (14%), and hematoma (2%).

**Conclusion**

This study provides valuable data on demographics, surgical approaches, and outcomes for vulvo-perineal EMPD reconstruction, guiding optimal technique selection for this challenging condition.

Oral Presentation | Free paper (Skin/ Burn/ Wound Healing 1)

P97

Effects of Plasma-activated Lactate Ringer's Solution (PAL) on Mice Skin

Katsumi EBISAWA¹, Kae NAKAMURA^{2,3}, Shin-ichi HIGUCHI¹, Hiromasa TANAKA², Hiroaki KAJIYAMA³, Shinya TOYOKUNI⁴, Masaaki MIZUNO⁵, Kazunobu HASHIKAWA¹

¹ Department of Plastic Surgery, Nagoya University Graduate School of Medicine

² Center for Low-temperature Plasma Sciences, Nagoya University

³ Department of Obstetrics and Gynecology, Nagoya University Graduate School of Medicine

⁴ Department of Pathology and Biological Responses, Nagoya University Graduate School of Medicine

⁵ Center for Advanced Medicine and Clinical Research, Nagoya University Graduate School of Medicine

Background:

It has been demonstrated that nonequilibrium atmospheric pressure plasma (NEAPP) irradiated lactate ringer's solution (plasma activated lactate ringer's solution: PAL) has potential role on medical applications. But, there is no study concerning to PAL application in human.

Objective:

We investigated that effects of PAL for healthy skin and wound on mice.

Methods:

We made excisional wound-splinting model using diabetic mice, and divided into three groups: control group, lactate Ringer's solution (Lactec) group, and PAL group. We evaluated wound healing with wound photos, and histological examination. And, we also evaluated local effects of PAL administration on normal skin and the systemic effects on organs through histological examination.

Results:

Diluted PAL group promoted wound healing and epithelialization compared to control and Lactec groups. On the other hand, non-diluted PAL group had a tendency to decrease both. We found no adverse events in either cases.

Conclusion:

We demonstrated that PAL topical application was safe and PAL enhanced wound healing on mice skin defect model. In future, we will try PAL application on human skin.

E-poster

P98

Comparative response to VEGF between normal and arteriovenous malformations endothelial cells

Ho Yun Chung^{1,2}, Tae Hwan Park¹, Suin Kwak^{1,2}, Eun Jung Oh^{1,2}, Hyun Mi Kim^{1,2}, Joon Seok Lee¹, Jeong Yeop Ryu¹

¹ Dept. of Plastic & Reconstructive Surgery, School of Medicine, Kyungpook National University

² CMRI, School of Medicine, Kyungpook National University

Background: Arteriovenous malformations (AVMs) that result from abnormal connections between artery and vein are rare but potentially life-threatening condition.

Objective: This research aimed to explore and assess the impact of vascular endothelial growth factor (VEGF) on the pathophysiological processing of AVMs. Additionally, the findings are being used to formulate an innovative strategy for treating AVMs.

Methods: Endothelial cells (ECs) were cultured from normal and AVM tissues and treated with VEGF. Immunofluorescence imaging and tube formation assay were performed to evaluate EC proliferation and angiogenesis. Real-time PCR was used to analyze gene expression.

Results: Immunoreactivity of CD31 was found in $82.00 \pm 0.52\%$ of the AVM ECs area, which was significantly higher than normal ECs ($78.23 \pm 0.84\%$). In the tube formation assay, the number of junctions and total vessel length in each condition were significantly greater in AVM ECs group than normal ECs group. In analysis of angiogenesis-related genes using real-time PCR, FSTL1, MARKS, and CSPG4 showed significantly higher expression in AVM ECs group than normal ECs group under all conditions. Among them, the expressions of MARCKS and CSPG4 significantly were increased in AVM ECs group under VEGF treatment condition. Therefore, the angiogenic effect of VEGF in AVM ECs was increased compared to normal ECs.

Conclusion: Through this study, it is demonstrated that the higher degree of response to VEGF in AVM ECs than normal ECs could be an important factor for stimulating downstream angiogenesis in AVMs. These results are expected to help understand the pathophysiology of AVMs and provide basic knowledge for new treatment strategies.

E-poster

P99

MicroRNA-135b-5p as a potential biomarker in the endothelial cells of arteriovenous malformations

Ho Yun Chung^{1,3}, Joon Seok Lee¹, Gyeonghwa Kim^{2,3}, Hyunbin Kim¹, Eun Jung Oh^{1,3}, Hyun Mi Kim^{1,3}, Suin Kwak^{1,3}, Keun Hur^{2,3}

¹ Dept. of Plastic & Reconstructive Surgery, School of Medicine, Kyungpook National University

² Dept. of Biochemistry and Cell Biology, School of Medicine, Kyungpook National University

³ CMRI, School of Medicine, Kyungpook National University

Background: Arteriovenous malformations (AVMs) are the congenital vascular anomalies with a poor prognosis. AVMs are considered intractable diseases, as there is no established approach for early diagnosis and treatment.

Objective: This study aims to provide new evidence by analyzing microRNAs (miRNAs) associated with AVM. We present fundamental evidence for early diagnosis and treatment of AVM by analyzing miRNAs in the endothelial cells of AVM.

Methods: Endothelial cells (ECs) isolated from AVMs and normal tissues and cultured. Both ECs were used for profiling and validation of miRNAs. Comparative analysis of miRNAs expression differences between normal and AVM tissues was performed. Selected miRNAs were subsequently analyzed under hypoxia and VEGF treatment.

Results: Fourteen up-regulated and seven down-regulated miRNAs were detected in profiling assay. Among them, miR-496, miR-135b-5p, miR-132-3p, miR-193a-5p and miR-193b-5p in up-regulated group and miR-137 and miR-30a-3p in down-regulated group were selected based on a literature review related to angiogenesis. miR-135b-5p, miR-193a-5p and miR-137 identified as candidate miRNAs with statistically significant differences in validation assay. Under hypoxic conditions, a comparison revealed a marked upregulation of miR-135b-5p in AVM compared to normal, correlating with increased endothelial activity. VEGF treatment demonstrated no significant increase in miR-135b-5p in normal, however, a surge in AVM. Under both hypoxia and VEGF treatment, comparison indicated a down-regulation of miR-135b-5p in AVM, although not reaching statistical significance.

Conclusion: Through this study, it was determined that miR-135b-5p is implicated in the pathophysiology of AVM and might play an important role as a potential biomarker on AVMs.

Oral Presentation | Free paper (Nerve)

PAO

Pain surgery using nerve flaps: ultra-micromorphological changes and clinical applications

Toshiro Mese, Isao Koshima, Wataru Otsuka, Go Kishi, Syuhei Yoshida

Plastic & International center for lymphedema, Hiroshima University

Background: So far, we have conducted basic searches such as free nerve transfer and vascularized nerve transfer, and based on the results, we have attempted several pedicled/free nerve valve transfer techniques. We will provide an overview of the basic work we have done so far and report on the application of nerve graft nerve flaps with blood circulation in clinical cases.

Methods: [Basic search] We performed vascularized and free sciatic nerve transfer for rats, and used electron microscopy specimens to quantify the tissue of regenerated axons 1 to 6 months after surgery, and found that nerve regeneration in the vascularized group was superior in the distal lower limb region.

[Breakdown of clinical cases] We have performed total 173 vascularized nerve transfer out of 226 cases with nerve injuries (133 cases of males, 93 cases of females, aged 5-79 years). The reconstructed nerves were in 88 cases of upper extremities, 26 cases of lower extremities, 87 cases of facial nerves, and 19 cases of trigeminal nerves. The main pedicled nerve transfer technique was nerve bundle transfer 37, nerve bundle turn-over 17, free grafts included simple nerve flap 71, nerve flaps (ALT 4, SCIP 2, TAP flap 5, deep peroneal nerve-extensor toe tendon (joint) 3), 29 lateral femoral cutaneous nerves, 28 deep peroneal nerves, and 7 sural nerves.

Results & conclusion: There were 4 cases of emergency vascular pedicle reanastomosis, 1 case of total flap necrosis, and 2 cases of partial necrosis. Long-term results varied between cases. Nerve bundle transfer and nerve flap transplantation have made effective nerve bypass possible, opening the possibility of new nerve reconstruction techniques such as prevention of various nerve paralysis.

PA1

Smooth Muscle Cell Regeneration within Human Lymphatics and Long-Term Follow-up After LVA

Wataru Otsuka¹, Toshiro Mese¹, Hirohumi Imai^{1,2}, Syuhei Yoshida¹,
Isao Koshima¹

¹ Hiroshima University Hospital

² Cancer Institute Hospital of Japanese Foundation for Cancer Research

Background: In 1996, we first introduce autonomic contraction of lymphatics in the clinical field and described smooth muscle regeneration within lymphatics of human lymphedema. The present investigation was series carried out to study the relation between ultrastructural findings of lymphatics and long-term results after mLVAs.

Objective and Methods: A series of 11 patients with upper or lower limb lymphedema were treated with single or mLVAs. As for upper limb, The average number of LVA was 4.8, and followed up for average of 7.3 years after surgery. A total of 12 biopsied lymphatic channels were obtained from various levels of limbs and the specimens were observed ultrastructural changes.

Results: Evaluation of surgical effects was made mainly by photos and criteria of judgement was decided as 5 categories: 1. Functional recovery, 2. Excellent, 3. Improved, 4. Constant, 5. Worse. Regarding the operative effect in the arms, 4 cases showed excellent and one with constant. As for the legs, 3 cases showed improvement or more, and 2 were constant. There was no correlation between preoperative severity and results of mLVAs. It was found that remaining function of lymphatics could be estimated by ultrastructural observation, especially for smooth muscle cells. endothelial cells, and proliferation of collagen fibrils.

Conclusion: mLVAs are essential for treatment of lymphedema. The postoperative prognosis can be estimated not by the preoperative history and symptoms, but ultrastructural pathology of lymphatics, which seems to be the most reliable evaluation.

Oral Presentation | Free paper (Craniofacial/ Others)

PA4

Correlation Between Microtia Ear Deformity and Middle Ear Development in 3D CT Scans.

Takashi Kurabayashi, Hirotaka Asato, Kohei Umekawa, Takuya Iida
Dokkyo Medical University

Background: There is a correlation between the auricle deformity in microtia and the degree of middle ear development. However, middle ear development is often good, even in the lobule type, which is considered to have experienced developmental disturbances at an early stage of auricular formation.

Objective: To investigate which auricular shapes are associated with poor middle ear development using 3D CT scans.

Methods: 3D CT scans of 221 auricles from 189 microtia patients, which show the relative relationships of the skin, auricular cartilage, and skull, evaluated the position and shape of the auricle in lateral views and compared with the Jahrsdoerfer scores, indicators of middle ear development.

Results: It was found that the concave part between the upper and lower auricle components, referred to as position X, is closely related to middle ear development. Thus, the auricles were divided into two groups: the upper position group, where position X is at or above the temporal line, and the lower position group, where position X is below the temporal line. A comparison of the Jahrsdoerfer scores between the two groups was conducted using an unpaired t-test. It was found that the Jahrsdoerfer score in the lower position group was significantly lower than in the upper position group by 4.0 ± 0.8 (0.95 CI) (one-sided p-value $< 4.0e-16$, $df = 72.2$).

Conclusion: It was found that the positional relationship between position X and the temporal line is closely related to the development of the middle ear.

PA5

Live-Streaming Using Modified Head-Mounted Smartphone as An Assisting Learning Tools For Fisher Unilateral Cleft Lip Repair.

Jasmine Athiyya Wibowo¹, Prasetyanugraheni Kreshanti¹,
Narottama Tunjung Hariwangsa¹, Nandita Melati Putri¹, Ardi Findyartini²,
Indri Aulia¹, Tommy Toar Huberto Purnomo¹, Sugeng Supriadi³

¹ Division of Plastic Reconstructive and Aesthetic Surgery, Department of Surgery, Faculty of Medicine, Universitas Indonesia

² Department of Medical Education, Faculty of Medicine, Universitas Indonesia, Jakarta, Indonesia

³ Department of Mechanical Engineering, Faculty of Engineering, Universitas Indonesia, Kampus UI, Depok, Indonesia

Background: The Covid-19 pandemic has significantly impacted healthcare services, including surgical education, due to restrictions in the operating room (OR) and cancellation of elective surgeries. Institutions have implemented various strategies, such as simulation and virtual learning, to mitigate these effects.

Objective: This study evaluates the effectiveness of learning surgical operations through live-streaming using cost-effective technologies.

Methods: Twenty-six residents were randomly assigned to a control group, observing Fisher unilateral cleft lip design in the OR, and a treatment group, learning through live streaming with operator's point of view. Residents recreated the design on anatomical models. The designs were evaluated by two attendings.

Results: Assessors' reliability was satisfactory (Cronbach's alpha = 0.637), with no significant inter-assessor differences (ANOVA $p = 0.519$). The treatment group scored lower ($M=12.23$) than the control ($M=13.57$, $p = 0.03$), but visualization significantly predicted scores ($\beta = 0.721$, $p < 0.001$). Surveys showed 73% satisfaction with live-streaming, but 63% felt additional in-person learning was necessary. In contrast, 62% of the control were very satisfied with direct observation, but noted limitations due to the sterile environment.

Conclusion: The use of live-streaming with a head-mounted smartphone offers an effective alternative for surgical education, particularly in situations with limited OR personnel. Implementing live-streaming or video-assisted technology could enhance learning opportunities, but considerations such as a stable internet connection and debriefing sessions are essential to improve interaction between students and attendings.

PA6

Development and Evaluation of Novel Interlocking Three-Dimensional Plate 2.0 System for Managing Mandibular Fractures

Prasetyanugraheni Kreshanti¹, Deni Noviana², Bambang Pontjo Priosoeryanto³, Aria Kekalih⁴, Ahmad Jabir Rahyussalim⁵, Sugeng Supriadi¹, Mendy Juniaty Hatibie⁶, Chaula Luthfia Sukasah¹

¹ Division of Plastic Reconstructive and Aesthetic Surgery, Department of Surgery, Faculty of Medicine, Universitas Indonesia

² Division of Surgery and Radiology, School of Veterinary Medicine and Biomedical Sciences, IPB University, Bogor, Indonesia

³ Division of Veterinary Pathology, School of Veterinary Medicine and Biomedical Sciences, IPB University, Bogor, Indonesia

⁴ Department of Community Medicine, Faculty of Medicine, Universitas Indonesia, Indonesia

⁵ Department of Orthopaedics and Traumatology, Faculty of Medicine, Universitas Indonesia, Dr. Cipto Mangunkusumo Hospital, Jakarta, Indonesia

⁶ Division of Plastic Reconstructive and Aesthetic Surgery, Department of Surgery, Faculty of Medicine, Sam Ratulangi University, Manado, Indonesia

Background: Mandibular fractures are the most common craniomaxillofacial fractures, often causing mastication disturbances. Management typically involves 2.0 system plates and screws, such as three-dimensional (3D) plates, but conventional 3D plates have limitations. Their fixed shape makes it difficult to avoid fracture lines or vital anatomical structures. To address this, an interlocking 3D plate was developed with adjustable components to avoid critical structures and maintain stability.

Objective: This study aims to analyze the biomechanics, biocompatibility, bone healing, and usability of the novel interlocking 3D plate.

Methods: Finite element analysis established the feasibility of the interlocking 3D plate design. Biomechanical evaluation used ten goat mandibles to assess mechanical strength and stability. Biocompatibility and bone healing were evaluated in an animal study with 28 goats. Biocompatibility was assessed through radiological and histopathological (Hematoxylin-Eosin staining) evaluations of inflammatory responses. Bone healing was assessed through bone density and Mason Trichome staining. Usability was tested by nine plastic surgeons who assessed comfort and application time on a synthetic mandibular model.

Results: The biomechanical evaluation showed that the interlocking 3D plate better-maintained fracture stability while allowing controlled micro-movement. Biocompatibility results indicated lower tissue reaction and inflammatory response compared to the standard plate. The interlocking 3D plate facilitated faster bone healing, with significant improvements in bone formation and density. The usability study demonstrated that the interlocking 3D plate was as easy to use as the standard plate, with no significant differences in application time.

Conclusion: The interlocking 3D plate shows significant potential as a viable alternative for managing mandibular fractures.

PA7

An Analysis of Independent Risk Factors Related to Burn Mortality in Adults. Is There a Correlation Between Patient Volume and Mortality?

Julia Bartkova¹, Dušana Selecká¹, Anna Příbojová¹, Paul Cederna²

¹ Department of Burns and Plastic Surgery, Institution Shared with the University Hospital Brno, Faculty of Medicine, Masaryk University, Czech Republic

² Department of Surgery, Section of Plastic Surgery, University of Michigan Health System, Ann Arbor, Michigan

Background:

There are many critical factors that impact the outcomes following burn injuries in adults. Understanding these factors in the most severely burned patients, could help to reduce mortality and improve their care. In particular, our goal was to determine the independent risk factors associated with mortality in burn patients.

Methods:

A retrospective analysis of all adults burn patients (>18 years old) admitted to ICU in the single Burn Unit, from 2005-2022, was performed.

Results:

1192 adult burn patients met the inclusion criteria. 113 patients died of their burn injuries with 60% being male. The average extent of burn was 47% in all cases. Majority of fatal burn victims (66.1 %) were from an urban region. Most fatal burn occurred in patients over the age of 60 years. Burn injuries leading to in-hospital mortality occur more often in the home environment (59.3%). In both, women and men, the predominant etiological agent was the flame. Most patients (90.2%) had an abbreviated burn severity index (ABSI) score of more than 8. We observed a decrease in the mortality of adult burn victims during the Covid-19 pandemic period. On the average, patients were hospitalized longer during the covid-19 period (9.8 days vs. 11.8 days) and underwent more surgeries (3.0 vs 5.2).

Conclusion:

Male gender, older age, presence of full thickness burns, greater extent of burn injury, flame as the etiological agent, and an ABSI score of more than 8 are among the most important factors associated with high mortality in burn patients admitted to the ICU.

PA8

**Age-Based Epidemiological Insights into Burn Injuries:
Distinguishing Patterns in Pediatric and Adult Cohorts**

Julia Bartkova^{1,2}, Kristián Kanuščák³, Barbara Bugarová⁴, Dominika Miklišová², Dušana Selecká², Livia Petrásšková², Janusz Rucki², Paul Cederna⁵

¹ Department of Burns and Plastic Surgery, University Hospital Brno, Jihlavská 20, 62500 Brno, Czech Republic

² Faculty of Medicine, Masaryk University, Kamenice 5, 62500 Brno, Czech Republic

³ Department of Surgery, Hospital Kyjov, Czech Republic

⁴ Faculty of Medicine of the Slovak Medical University, Bratislava, Slovakia

⁵ Department of Surgery, Section of Plastic Surgery, University of Michigan Health System, Ann Arbor, Michigan

Background:

Burn injuries manifest differently across age groups, warranting a nuanced examination of their epidemiological dynamics. This study endeavors to discern age-specific patterns of burn injuries, focusing on pediatric and adult cohorts, while also considering the influence of rural and urban environments.

Methods:

A retrospective study was conducted on all pediatric burn patients (<18 years old) admitted to a single Burn Unit from 2005 to 2022, and on all adult burn patients (>18 years old) admitted from 2016 to 2022. The study analyzed demographic data, burn severity, and treatment methods for both pediatric and adult groups, with a comparison of burn injuries occurring in rural versus urban settings.

Results: A total of 2,604 children who met the study criteria were identified, with 34.3% coming from rural areas. In the adult cohort, 1,378 individuals met the study criteria, with 37.3% originating from rural areas. Specifically, in patients from rural regions transportation to the burn center on the day of injury occurred in 82% of pediatric patients and 58% of adult patients. Generally, treatment in the OR on the day of admission happened 8.14% of the time in pediatric patients and 13.4% in adults. There were differences in these outcomes for adults patients coming from rural (13.86%) and urban environments (8.98%). Burns were more prevalent in males across both pediatric and adult populations. **Conclusion:** By comparing burn injuries sustained in different settings, we aim to unveil distinct epidemiological insights that inform targeted interventions and enhance clinical management strategies tailored to specific age groups.

Oral Presentation | IPSRC Best paper session

PA9

AI-Driven Age Estimation for Evaluating Non-Surgical Facial Rejuvenation Techniques

Khaled Alameddine, Karim Bakri

Mayo Clinic, Division of Plastic Surgery, Rochester, MN. USA

Background: Our study introduces an innovative AI model designed to estimate perceived age from facial characteristics, aiming to enhance the evaluation of non-invasive procedures.

Objective: To accurately assess the impact of non-surgical facial rejuvenation techniques on perceived age, facilitating the customization of treatments to each patient's unique facial aging profile.

Methods: Employing a deep convolutional neural network (DCNN), we initially trained the model on the extensive ImageNet dataset and further refined with 523,051 pre-annotated facial images. The Xception architecture was selected for its superior feature extraction capabilities. This model was further refined and tested on a set of 10,000 patient faces from the Mayo Clinic's database. Regression analysis and softmax probability were utilized for precise age estimation (Agbo-Ajala et al., 2022).

Results: The AI model demonstrated a high accuracy rate of 91.8% in estimating the perceived age of patients prior to non-surgical treatments, with a standard deviation of 4.3 years. Post-treatment, the AI model identified an average perceived age reduction of 6.8 years across all patients, with significant variation among different non-surgical techniques. Treatments such as dermal fillers and Botox showed the most pronounced age-reduction effects. Heat maps were utilized to identify specific facial regions that contributed most to the AI's age predictions, showing a strong correlation between these regions and the areas targeted by non-surgical treatments.

Conclusion: By leveraging advanced AI technology to refine aesthetic treatment evaluation, this study underscores the potential for personalized non-surgical interventions, contributing to the advancement of patient-specific rejuvenation strategies in the field of aesthetic medicine

References

Agbo-Ajala O, Viriri S, Oloko-Oba M, Ekundayo O, Heymann R. Apparent age prediction from faces: A survey of modern approaches. *Front Big Data*. 2022 Oct 26;5:1025806. doi: 10.3389/fdata.2022.1025806. PMID: 36387012; PMCID: PMC9644213.
<https://pubmed.ncbi.nlm.nih.gov/36387012/>.



PBO**Development of a 3D-Printed Chest Wall for DIEP Flap Anastomoses: Integrating Radiology Imaging, 3D Printing, and Special Effects Artistry for Hyper-Realistic Medical Simulation**

Nicole Sanchez Figueros, Anita Mohan, Christian Hanson, Scott Odorico, Christin Harless, Jorys Martinez, Jonathan Morris, Aparna Vijayasekaran

Mayo Clinic Rochester, MN


Background: High-fidelity simulation in surgical training has significantly enhanced precise skill development, especially in complex procedures like micro-anastomosis. This project introduces a hyper-realistic DIEP Flap Chest Reconstruction Micro-Anastomosis Trainer that replicates real-life surgical settings. By integrating radiology imaging, 3D printing technologies, and traditional special effects artistry, we aimed to create an anatomically accurate and tactilely realistic training model to improve training and outcomes.

Objective: To develop an anatomically accurate and tactilely realistic training model for micro-anastomosis practice, enhancing surgical training effectiveness.

Methods: The project began by selecting patient data from radiology images, ensuring the inclusion of relevant anatomical details. Digital modeling of these features was conducted using advanced software tools, allowing for precise manipulation and refinement. Various 3D printing technologies were employed to fabricate different components of the trainer, including FDM, SLA, and SLS methods. Additionally, traditional sculpting techniques using oil-based clay were utilized to craft the intricate details of the skin surface. Silicone molding techniques were employed to replicate the texture and elasticity of human skin, ensuring tactile realism.

Results: The phase I of this project successfully achieved a hyper-realistic trainer, meticulously replicating the intricate chest wall and DIEP flap anatomy. Clinician feedback highlighted its exceptional ability to simulate real surgical conditions, affirming its efficacy in enhancing surgical skill acquisition. Phase II will include validation in mastery lab to assess trainees improvement.

Conclusion: This project underscores the potential of merging advanced technologies to enhance surgical training. Future refinement will broaden the model's applicability to various training scenarios, ultimately improving patient outcomes.



Oral Presentation | Free paper (Breast)

PB1

Effect of Inframammary Fold Skin Dome on Dehiscence Rates in Breast Reduction Surgery

Nicole Sanchez, Tony Huang, Aparna Vijayasekaran, Christin Harless, Jorys Martinez-Jorge

Mayo Clinic, Rochester MN

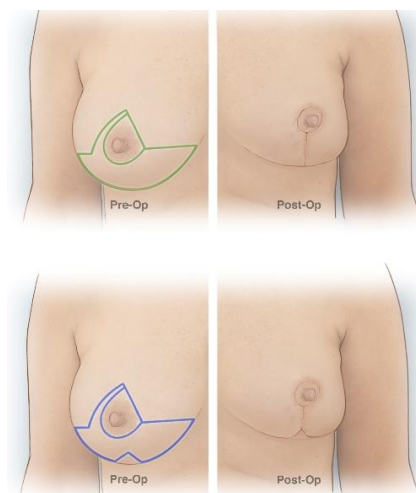
Background: Breast reduction surgery aims to alleviate symptoms of macromastia through various techniques, including the superomedial pedicle and wise-pattern. The inframammary fold (IMF) plays a crucial role in breast aesthetics and postoperative complications. Variations in IMF skin dome incision may impact outcomes, with potential implications for patient satisfaction and surgical success.

Objective: to investigate the influence of inframammary fold (IMF) Dome incision on surgical outcomes in wise-pattern breast reduction surgery. Specifically, it seeks to assess the association between IMF Dome incision and dehiscence rates

Methods: A retrospective chart review was conducted on patients who underwent wise-pattern breast reduction surgery between 2014 and 2023 at a single institution. Patients were categorized based on the presence or absence of IMF Dome incision. Data on demographics, comorbidities, surgical details, and complications were collected. Statistical analyses, including Pearson Chi Square and logistic regression.

Results: Of the 133 participants (245 breasts), 42 had surgery without IMF Dome incision, while 91 did. Significant BMI differences were noted ($p = 0.003$), with all radiotherapy patients undergoing IMF Dome incision. The overall dehiscence rate was 19.5%, showing a trend towards lower rates with IMF Dome incision. Logistic regression revealed excised breast weight significantly affected dehiscence ($p = 0.0059$). Other factors, including adjuvant therapies and comorbidities, did not predict dehiscence.

Conclusion: IMF Dome incision in wise-pattern breast reduction surgery shows promise in reducing dehiscence rates. Excised breast weight significantly influences dehiscence occurrence. These findings highlight the importance of meticulous surgical technique and careful patient selection to optimize outcomes in breast reduction surgery.



PB3

Evolution of eyelid surgery with innovative AI tools

Seung Han Song

Department of Plastic and Reconstructive Surgery, Chungnam National University

Background: The integration of AI technology in plastic surgery presents significant advancements in patient outcomes and surgical precision.

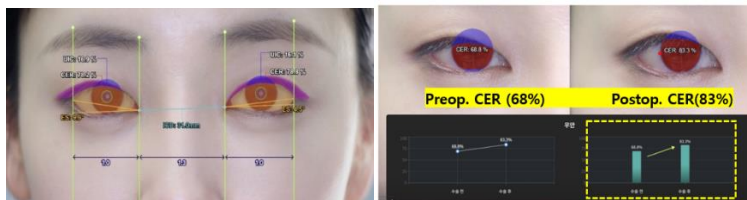
Objective: This presentation highlights an AI-driven tool specifically designed for eyelid surgery consultations and planning. By analyzing eye morphology, this tool aids surgeons in making precise, data-informed decisions that align with the patient's unique anatomical features and aesthetic preferences.

Methods: Key functionalities of the AI tool include automatic diagnosis of ptosis severity and eyelid skin laxity, comparison with the patient's ideal appearance, and simulation of post-surgery outcomes. These features enable the creation of accurate surgical plans, enhancing symmetry and natural appearance. The tool improves the efficiency of pre-operative consultations and elevates patient satisfaction through clear visual representations of expected results.

Results: Clinical trials have shown a 30% reduction in consultation times and a 20% increase in patient satisfaction. The AI tool's ability to tailor surgical plans to individual needs ensures personalized patient care and optimal results.

Conclusion: This presentation will explore the AI tool's technical framework, provide case study examples, and discuss future applications of AI in aesthetic surgery. Attendees will learn how to implement this technology to improve surgical planning and patient communication, setting new standards in the field of plastic surgery.

Harnessing AI for eyelid surgery marks a new era of precision and personalization, driving forward the capabilities of plastic surgeons and enhancing overall patient care.



Oral Presentation | Free paper (Others)

PB4**Carcinogenesis within free Latissimus-Dorsi flap donor site. A case report and literature review.**

James Moore, Abby Young, Duncan Taylor

Sir Charles Gairdner Hospital, Nedlands, Perth, 6009 WA

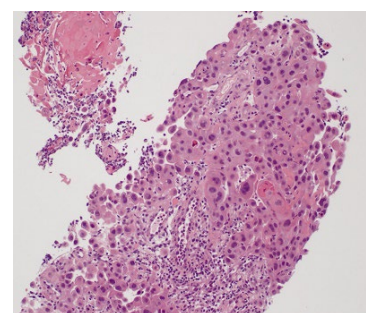
Cutaneous squamous cell carcinoma (SCC) represents a prevalent and devastating disease in areas with high UV exposure and fair-skinned individuals. It may spread locally or distantly via lymphatic and hematogenous routes. Management involves oncological control followed by reconstruction by plastic surgical teams. Free tissue-transfer represents the pinnacle of described surgical solutions. (1)

A 64-year-old gentleman underwent a Latissimus-Dorsi free muscle flap to reconstruct a large full-thickness deficit left by resection of invasive scalp SCC. At one year follow-up, SCC was found present in fluid analysis from a persistent seroma at the donor site. After surgical deliberation, a palliative route was pursued.

Free-flaps in head and neck oncological reconstruction are fraught with morbidity, both at the donor and defect site. (2) Commonly reported are surgical site infections (SSI), flap complications. Carcinogenesis within free flap donor sites is a rare occurrence consigned to case reports within scientific literature. The theory of iatrogenic implantation of malignant cells has been mooted. (3)

Biography:

1. Hallock, G. G. (2023). The Reconstructive Toolbox. *Archives of Plastic Surgery*, 50(4), 331–334. <https://doi.org/10.1055/S-0043-1769619>
2. Lutz, B. S., Wei, F. C., Chen, H. C., Lin, C. H., & Wei, C. Y. (1998). Reconstruction of scalp defects with free flaps in 30 cases. *British Journal of Plastic Surgery*, 51(3), 186–190. <https://doi.org/10.1054/BJPS.1997.0182>
3. Pichardo, P., Purdy, N., & Haugen, T. (2020). Implantation of Squamous Cell Carcinoma in a Free Flap Donor Site. *The Annals of Otology, Rhinology, and Laryngology*, 129(9), 935–940. <https://doi.org/10.1177/0003489420917418>



Oral Presentation | Free paper (Fat for the breast 1)

R01

The stability of the inframammary fold formed by loop suture during breast augmentation/reconstruction with fat grafting

Viacheslav Vasilyev¹, Sergey Vasilyev^{1,2}, Igor Vasilyev^{1,2}, Yuri Vasilyev^{1,2}, Malika Gurba¹

¹ Institute of Plastic Surgery and Cosmetology

² South Ural State Medical University

Background: Implementation of the loops described by R. Khoury into clinical routine have helped a lot to control the shape and symmetry during aesthetic and reconstructive breast augmentation with fat grafting. However, there are a number of complications that go along with this method. Inframammary fold (IMF) instability is one the most common adverse effects that we observed while using such technique.

Objective: To evaluate factors that influence the stability of the inframammary fold formed by loop suture.

Methods: Since 2016 sixty-seven patients underwent IMF reconstruction with loops during breast augmentation with fat grafting (53 reconstructive and 14 aesthetic cases). The thread (Capron or PDS) was set up from the puncture at subclavian region along the breast contour according to the technique described by R. Khoury. Internal tissue expansion was applied in 19 cases reconstructive cases prior to IMF reconstruction. Results were evaluated with standard anthropometric measurements and photography at 1, 3, 6 and 12 months postoperatively.

Results: Caudal IMF displacement was observed in 12 patients (18%) and was associated with limited soft tissue mobility. In 10 cases such complication was registered in patients without internal preexpansion. Thread rupture was observed in one case while PDS is used.

Conclusion: Limited abdominal skin mobility is the most important factor that affects the stability of IMF formed with loop suture and fat grafting. In such cases internal tissue preexpansion should be performed in order to achieve sufficient skin surface area.

Oral Presentation | Sydney Coleman award session

R02

Management of radiation injury of the rectum with adipose-derived biomaterials injection. 10-year experience.

Zhanna Teriushkova¹, Viacheslav Vasilyev², Igor Vasilyev^{1,2}, Sergey Vasilyev^{1,2}, Malika Gurba²

¹ South Ural State Medical University

² Institute of Plastic Surgery and Cosmetology

Background: The use of fat grafting and adipose-derived stromal vascular fraction injections have changed the paradigm of radiation-induced soft tissue damage management and radiation rectum injury in particular. Although initial clinical experience in this field showed encouraging results, evaluation of long-term outcomes is gaining relevance.

Objective: To analyze long-term outcomes of rectum radiation injury treatment with autologous fat and stromal vascular fraction (SVF) injections.

Methods: Since 2012 fat grafting in combination with SVF injections was used in 111 patients with rectum radiation injury: rectovaginal fistula (n=59; 53,2%), rectum ulcers (38; 34,2%) and proctitis (14; 12,6%). To achieve complete healing from 1 to 6 repeated procedures per patient were performed (362 surgeries in total). To assess outcomes physical examination, photography, ultrasound, MRI and histology were used.

Results: Complete healing was achieved in 109 cases (98,2%). The lack of effect was observed in two patients with rectovaginal fistula (1,8%) who had concomitant autoimmune disease. Fistula relapse was observed in four (6,8%) out of 59 patients and has been solved with additional procedures. Rectal stricture after healing of large fistula has developed in three (5,1%) out of 59 cases. Two (1,8%) fatal complications not directly connected to the researched method have been registered: cancer relapse in one case (0,9%) and insolvency of intestinal anastomosis after reverse colostomy procedure in the other case (0,9%).

Conclusion: Autologous fat and stromal-vascular fraction injection is relatively safe and highly effective method for treatment of radiation injury of the rectum.

R03

Targeting SIRT4/TET2 Signaling Alleviates Human Keratinocyte Senescence by Reducing 5-hmC Loss

Yukun Liu¹, Yi Yi¹, Yuchang Wang², Yiping Wu¹¹ Department of Plastic and Cosmetic Surgery, Tongji Hospital, Tongji Medical College, Huazhong University of Science and Technology, Hubei, China² Trauma Center/Department of Emergency and Traumatic Surgery, Tongji Hospital of Tongji Medical College, Huazhong University of Science and Technology, Wuhan, China

Abstract

Skin aging is characterized by wrinkle formation and increased frailty and laxity, leading to the risk of age-related skin diseases. Keratinocyte is an important component of the epidermis in skin structure, and keratinocyte senescence has been identified as a pivotal factor in skin aging development. Because epigenetic pathways play a vital role in the regulation of skin aging, we evaluated human skin samples for DNA hydroxymethylation (5-hydroxymethylcytosine; 5-hmC) and SIRT4 expressions. Results found that both 5-hmC and SIRT4 showed a significant decrease in aged human skin samples. To test the results in vitro, human keratinocytes were cultured in H₂O₂, which modulates skin aging in vivo. However, H₂O₂-induced keratinocytes showed senescence-associated protein expression and significant downregulation of 5-hmC and SIRT4 expressions. Moreover, 5-hmC-converting enzymes ten-eleven translocation 2 (TET2) showed a decrease and enhanced TET2 acetylation level in H₂O₂-induced keratinocytes. However, the overexpression of SIRT4 in keratinocytes alleviates the senescence phenotype, such as senescence-associated protein expression, decreases the TET2 acetylation, but increases TET2 and 5-hmC expressions. Our results provide a novel relevant mechanism whereby the epigenetic regulation of keratinocytes in skin aging may be correlated with SIRT4 expression and TET2 acetylation in 5-hmC alteration. Our study may provide a potential strategy for anti-skin aging, which targets the SIRT4/TET2 axis involving epigenetic modification in keratinocyte senescence.

Figure 1

Figure 1. Aged human skin keratinocyte show loss of 5-hmC

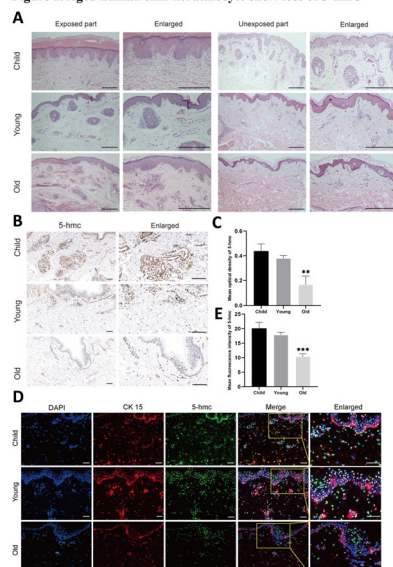


Figure 2

Figure 2. Aged human skin keratinocyte show loss of SIRT4

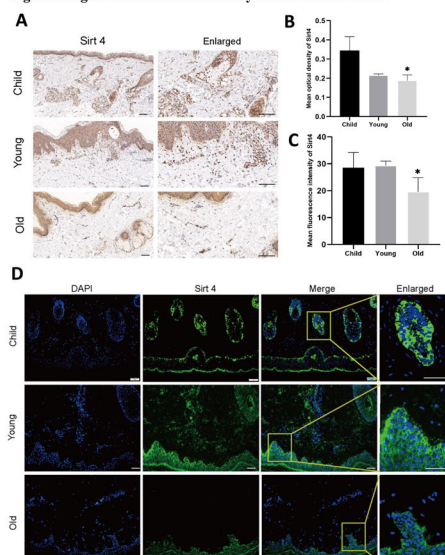


Figure 3

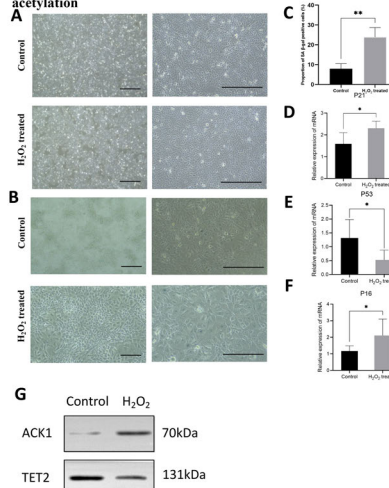
Figure 3. Effect of H₂O₂ on keratinocyte senescence and TET2 acetylation

Figure 4

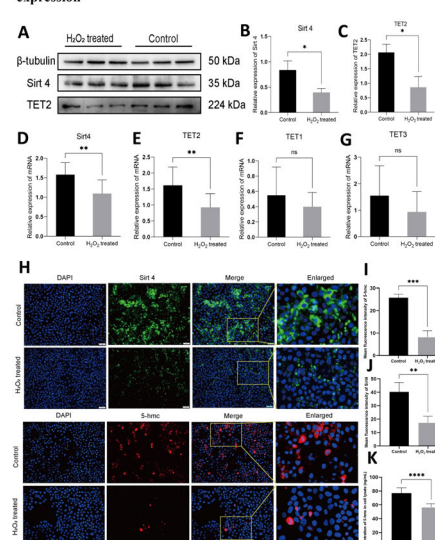
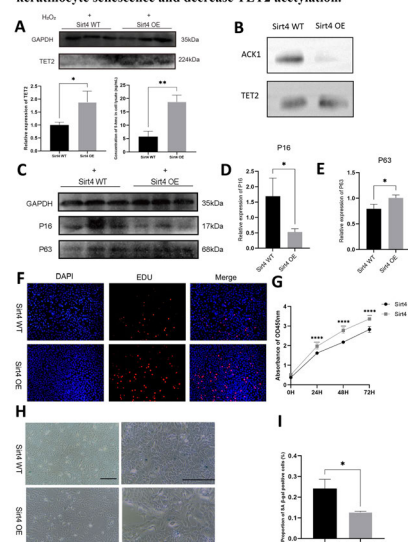
Figure 4. H₂O₂ alter keratinocyte TET2, 5-hmC and SIRT4 expression

Figure 5

Figure 5. Overexpression of SIRT4 alleviate H₂O₂ induced keratinocyte senescence and decrease TET2 acetylation.

G-CAT (Gene, Cell and Tissue) Academy

The acquisition of stromal cells from adipose tissue can be categorized into two approaches: direct and indirect methods targeting the connections between parenchymal and stromal-cells. Among these approaches, ultra-sharp blade systems have demonstrated the most successful outcomes.

[illegible]

R05

Activated Fat Grafting: A Novel Approach for Enhanced Fat Graft Retention and Natural Long-Term Results

Hasim Eray Copcu

G-CAT (Gene, Cell and Tissue) Academy

Background:

Fat grafting is a commonly performed procedure in plastic surgery with a long history of application. Despite numerous studies on the pathophysiology of fat grafting, many aspects remain unclear. The survival of fat grafts is influenced significantly by the presence of stromal-cells.

Objective:

This study introduces a novel technique called “activated fat grafting”, which involves releasing stromal cells using ultra-sharp blades without damaging the fat tissue parenchyma, followed by the application of fat grafting.

Methods:

Different sizes of fat grafts (2400 - 100 microns) were prepared using ultra-sharp blades specific to each anatomical area and depth. The process involved releasing stromal cells within the adipose tissue. A total of 248 patients underwent fat grafting on various body areas, including the face, breast, extremities, genital areas, and others.

Results:

Laboratory studies demonstrated that the use of sharp blades allowed the desired diameter of adipose tissue to be achieved without completely disrupting the parenchyma, while also releasing stromal cells and determining their presence and quantity. Clinicians and patients reported satisfactory long-term results in all cases.

Conclusion:

Adipose tissue contains parenchymal cells, predominantly adipocytes, interconnected with stromal cells through bonds and bridges. By separating these bonds using sharp blades, the stromal cells can be released without compromising the viability of adipocytes. This technique facilitates the attainment of natural, long-term results while minimizing complications such as graft visibility.

Figure 1: Protocol

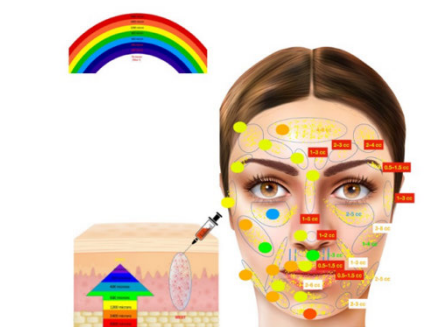
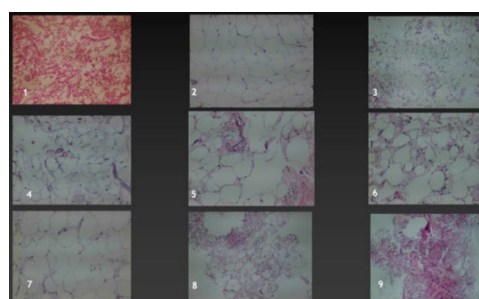


Figure 2: Histopathological analysis



Oral Presentation | Sydney Coleman award session

R06**Autologization of Exosome Therapies using De-Parenchymized Adipose Tissue Extracellular Matrix: A Novel Approach for Controlled Regenerative Medicine**

Hasim Eray Copcu

G-CAT (Gene, Cell and Tissue) Academy

Background:

Exosome products from allogeneic and xenogeneic sources are available on the market. A key challenge is controlling the effects of non-autologous exosomes.

Objective:

We hypothesized that combining exosomes with a patient's own extracellular matrix (ECM) can create "autologization," enabling better control over their effects. This study aimed to provide the rationale and a guide for future research exploring the autologization of exosome applications using de-parenchymized adipose tissue (DPAT).

Methods:

DPAT adipose tissue was achieved using 1200-, 400-, and 35-micron blades in an ultra-sharp blade system (Adinizer), and then "autologization" was achieved by combining the obtained DPAT with allogeneic exosomes. DPAT was evaluated histochemically, and exosomes were counted and analyzed with the Nanosight device.

Results:

The DPAT process using ultra-sharp blades is easily performed. DPAT obtained from adipose tissue was then combined with allogenic exosomes. It has been demonstrated histopathologically that adipocytes are eliminated in de-parenchymized fat tissue, and only ECM and stromal cells remain. It has also been proven that the number of exosomes is not affected by the combination.

Conclusion:

This study introduces two novel concepts previously unknown in the literature, "de-parenchymization" and "autologization," representing an innovative approach in plastic surgery and regenerative medicine. Our novel approach enriches regenerative cells while preserving critical ECM signals, overcoming the limitations of existing isolation methods. Extensive research is still needed, but autologization using DPAT-ECM holds great promise for translating exosome-based treatments into clinical practice.

Figure 1:DPAT analysis

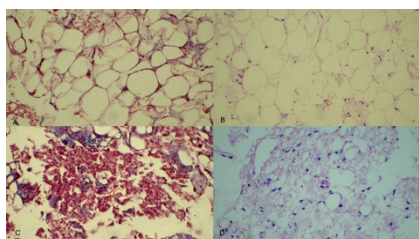
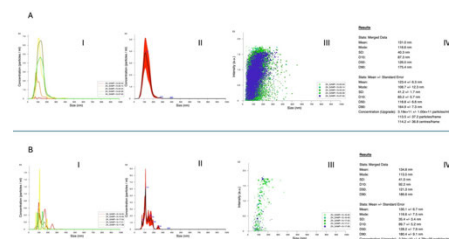


Figure 2: Exosome analysis



Oral Presentation | Free paper (Research)

R07

Mechanical stretch promotes hypertrophic scar formation by stimulating Schwann cells cholesterol biosynthesis

Jiahao He, Shengzhou Shan, Bin Fang

Department of Plastic and Reconstructive Surgery Shanghai Ninth People's Hospital Shanghai Jiao Tong University School of Medicine

Background: Hypertrophic scar (HS) is a fibroproliferative skin disorder which could lead to severe functional impairment. Mechanical stretch has been identified as a critical regulator of HS formation, but the underlying mechanism is not fully understood. Recently, activated Schwann cells (SCs) have been shown to be involved in wound healing and keloid formation. However, it is unknown whether SCs respond to mechanical stretch, leading to activation and ultimately HS formation.

Objective: We aim to investigate the influence of mechanical stretch on SCs activation and subsequent HS formation to explore a potential anti-HS formation therapy.

Methods: Human HS tissues and adjacent normal skin tissues were collected to detect activated SCs by immunofluorescence co-staining of SCs marker (SOX10) and SCs activated markers (p75, c-JUN and p-ERK). Cyclic mechanical stretch (10%, 24 hours, 0.5 Hz) was applied to SCs to mimic mechanical stretch during HS formation. Western blot was performed to assess the expression of p75, c-JUN and p-ERK. RNA sequencing was performed to characterize the molecular mechanism involved in stretch-induced activation of SCs. Selective inhibitors and conditional RNAi transfection were used to confirm the molecular mechanism of mechanical stretch in SCs activation. A stretch-induced rat tail hypertrophic scar model was established and then treated with selective inhibitors and conditional RNAi transfection to investigate the role of SCs in HS formation. Scar hypertrophy was assessed by H&E and trichrome staining. α -SMA expression was confirmed by immunohistochemistry.

Results: First, immunofluorescence confirmed that there is an increasing number of activated SCs distributed in HS samples. Mechanical stretch could promote the activation of SCs *in vitro*, as assessed by upregulation of p75, c-JUN and p-ERK. In mechanism, RNA sequencing analysis revealed a strong enrichment for genes involved in cholesterol biosynthetic processes in stretch-treated SCs. Importantly, the expression of 3-hydroxy-3-methylglutaryl coenzyme A reductase (HMGCR), a key enzyme in cholesterol biosynthesis, was upregulated in stretch-treated SCs. Application of simvastatin (an HMGCR inhibitor; 1 μ M) and HMGCR-RNAi effectively reduces mechanical stretch-induced activation of SCs *in vitro*. Finally, intradermal injection of simvastatin and HMGCR-RNAi could inhibit stretch-induced HS formation *in vivo*, as assessed by reduced scar cross-sectional area, collagen deposition and α -SMA expression.

Conclusion: Our study suggests that mechanical stretch could drive SCs activation by stimulating the key cholesterol biosynthesis enzyme HMGCR, thereby leading to HS formation. Therefore, targeting Schwann cells cholesterol biosynthesis may be a novel treatment option for HS.

Oral Presentation | Free paper (Face)

R08

DEEP PLASMA SKIN RESURFACING: ACCELERATED HEALING WITH HUMAN MSC EXOSOMES

Melinda Lacerna

LA Plastic Surgery

Background: Deep facial skin resurfacing with plasma technology results in better correction of superficial and deep rhytids, photo-damage and more tissue contraction resulting in improved skin and soft tissue tightening, yet safe to perform at the same time as a face and necklift. While the outcome can be quite impressive, the recovery can be daunting. Re-epithelialization can take as long 21 days.

Objective: This study describes how topical application of MSC exosomes immediately after deep plasma resurfacing procedures have decreased the rate to re-epithelialization, decreased pain scores, improved the rate of healing and improved the overall outcomes.

Methods: A retrospective review of one surgeon's experience performing deep plasma skin resurfacing from 2017-current is presented. A total of 100 consecutive patients were treated with full face deep plasma skin resurfacing, 55 of these patients underwent a concurrent facelift and necklift. In 48 patients, MSC exosome application was performed immediately after the procedure. The amount of days to full re-epithelialization were compared between the Exosome treated group (48) and the non-treated group (52).

Results: Range of re-epithelialization for the exosome treated group was 6-14 days, compared to 10-21 days in the non-exosome treated group. Longest follow up is 7 years.

There were four complications, all with the non-exosome treated group. One patient was hospitalized due to severe constipation from post-op opiate use. Three patients developed hypertrophic scarring on the chin that were treated with triamcinolone.

Conclusion: This series over the course of 7 years compares the course of healing of Exosome treated patients versus the non-exosome treated patients following deep plasma skin resurfacing procedures. The use of topical exosomes immediately after the procedure was shown to decrease the days to re-epithelialization from 10-21 days to 6-14 days. In addition, post-operative pain and narcotic use were significantly decreased in the exosome treated group. This is most likely due to down regulation of inflammatory pathways associated with exosome use. The more rapid rate to healing, re-epithelialization and re-establishment of the skin's protective phospholipid bi-layer also decreased other complications such as infections, prolonged erythema, hypo or hyper pigmentation, and hypertrophic scarring.

R09

Research and Clinical Application Prospects of Crt Autologous Collagen Technology

JIN BAI

Crt Autologous Collagen Clinical Research Center

Background:In the field of medical plastic surgery, filling is an indispensable part. At present, most of the popular filling technology is non-self-material, and the safer self-fat filling has some disadvantages. Therefore, the new technology of self-filling is a great power to promote the development of medical plastic surgery.

Objective:Discussion on the Research and Clinical Application Prospect of Crt Autologous Collagen Technology Through Technical Analysis and Technical Demonstration.

Methods:By preparing a self-healing hydrogel carrying a living cell composition of autologous collagen, It has achieved good biocompatibility, biodegradability and antibacterial effect.

Results:In the past 10 years, more than 170,000 cases of chest, buttocks, private and face were treated by Crt autogenous collagen technique. There were no other complications except more than one thousand cases of hard hand feeling, more than one hundred cases of poor shape and more than ten cases of postoperative infection.

Conclusion:Good biocompatibility, biodegradability and antibacterial effect, so as to achieve the technical effect of reducing adverse tissue reactions, At the same time, hydrogel provides a suitable microenvironment to improve the cell survival rate after transplantation, so as to achieve better filling effect and longer maintenance time.

A Clinical Study of Platelet-rich Fibrin Combined with Autologous High-Density Fat Transplantation in Augmentation Rhinoplasty

DAN YAN

Department of Plastic and Cosmetic Surgery, Chenzhou First People's Hospital, Chenzhou, Hunan

Background: Augmentation rhinoplasty is one of the most common plastic surgeries in Asia. Experts have conducted much research on augmentation rhinoplasty by injection. Autologous fat transplantation is the most advantageous method due to the abundant source, no rejection reaction and easy to operation. However, The high absorption rate limits the application of autologous fat transplantation in rhinoplasty. Therefore, improving the survival rate of fat after transplantation is the key to promoting this technology.

Objective: This study was designed to analyze the clinical effect of autologous fat-granule transplantation in augmentation rhinoplasty and explore a method to improve the fat retention rate.

Methods: 70 patients were randomly divided into platelet-rich fibrin (PRF) combined with high-density fat transplantation group (combined group) and conventional fat-granule transplantation group (control group). All patients were followed up for more than one year to observe the clinical effects, complications, safety, and satisfaction.

Results: At six months after the operation, the nasal shape was stable, the contour was higher and more stereoscopic than before. No complications such as fat embolism, infection, or necrosis occurred during the one-year follow-up. The satisfactory rate between the two groups have statistical significance($P < 0.05$).

Conclusion: PRF combined with autologous high-density fat transplantation is simple to operate, has a significantly increased fat-retention rate compared with the control group, and has stable long-term effects without obvious adverse reactions. This method can be widely used in clinical augmentation rhinoplasty.

R11

The Role of Adipose-Derived Stem Cells in Creating a Youthful Lower Eyelid in Facial Rejuvenation

QING HE

Shenzhen AKM Aesthetic Surgery Clinic

Background: In daily work, the lower eyelid has a variety of appearances, such as wrinkles, dark eye circles, bulges and a hollow eye, etc. According to different situations, we will take fat graft, fat removal techniques or septal reset, etc., then is there a method that is suitable for all lower eyelid formation, and can make the lower eyelid youthful?

Objective: This study was conducted to use adipose-derived stem cells to creating a youthful lower eyelid in facial rejuvenation

Methods: From January 2019 to January 2022, 48 patients underwent this procedure.

Classification of lower eyelid: I the lower eyelid was flat, with wrinkles or dark eye circles (11 cases)(A+B); II patients with periorbital aging (17cases:transconjunctival-lower-lepharoplasty7&transcutaneous lower lid blepharoplasty 8) (D+A+B); III, lower eyelid introcession, (9 cases)(A+B+C) ; IV

Surgical repair(12cases,injections4,surgical-procedure8) (D+A+B+C).Compound rejuvenation mode: A ADSC B Nano fat grafts C Micro fat grafts D traditional surgery

Results: The mean follow-up was 18 months and the mean operations was 2.5. The lower eyelid had a natural and flat appearance, the skin condition and the elasticity were enhanced. 4 patients complained of swelling and bruising.

Conclusion: The application of ADSCs can lead to full regeneration of dermal elastic matrix components. make up for the simplicity of the traditional treatment of the lower eyelid , reduce the potential relative risk of using chemical products. It is a natural, safe and effective method.

Oral Presentation | Free paper (Face)

R12

High Double Eyelid Fold Correction Composite Using Fat Strip Transplantation and Pretarsal Orbicularis Oculi Flap

Haihua Chen

Hangzhou First people's Hospital

Background: As the growing amount of unnatural-appearing upper eyelid after blepharoplasty, it's necessary to find suitable methods for secondary revision.

Objective: This study aimed to evaluate aesthetic outcomes of surgical correction of the high fold using a pretarsal orbicularis oculi flap with fat strip transplantation.

Methods: From January 2018 to September 2023, 50 patients with high and deep double eyelid folds underwent our fold-lowering procedure. All of these patients underwent surgical correction of high folds composite using fat strip transplantation and pretarsal orbicularis oculi flap, with postoperative follow-up ranging from 6 months to 2 years. All the Postoperative outcomes were recorded and reviewed.

Results: Using the composite technique, unnatural, high, and deep double eyelid folds were converted to lower and relative natural folds. Although prior high fold incision scars could be seen postoperatively on close examination, they were not easily visible. Complications included fold height asymmetry in 5 cases, persistence of the prior fold in 6 cases, and redundant upper flap skin that needed further excision in 3 cases.

Conclusion: Secondary blepharoplasty revision to correct the high fold is a challenging procedure for plastic surgeons. Using fat strip transplantation and pretarsal orbicularis oculi flap for correction of the high fold is relatively safe and effective. This provides a new treatment option in secondary revision techniques.

Oral Presentation | ISPRES APRAS award session 2

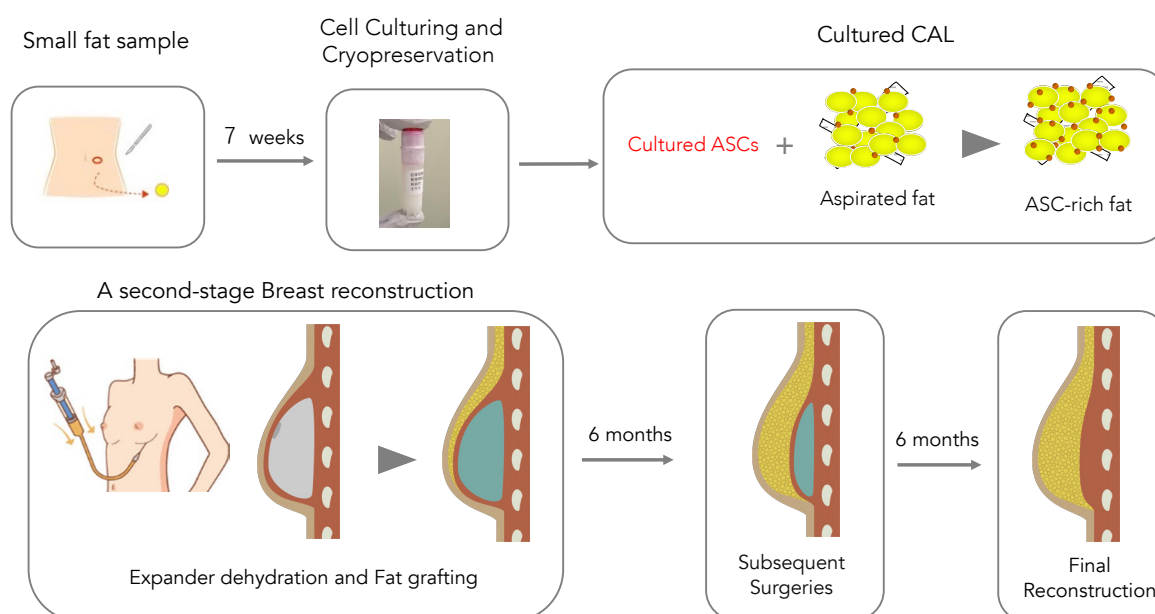
R13**Innovative Cultured Cell-Assisted Lipotransfer for Breast Reconstruction**Yuko Asano¹, Saori Unno², Naoko Tsuji²¹ Kameda Medical Hospital² Cellport Clinic Yokohama

Objective: Since 2008, we have been performing Cell-assisted lipotransfer (CAL) for cosmetic and reconstructive breast surgery at the Cellport Clinic Yokohama. CAL involves the isolation of adipose stem cells from additional fat harvested during surgery. However, CAL techniques prolonged operation time and required excessive fat harvesting. To address these issues, cultured CAL was developed, wherein stem cells are cultured and expanded from a minimal fat volume prior to surgery. This study presents our experiences with cultured CAL for breast reconstruction.

Methods: This retrospective study includes fourteen patients who underwent whole breast reconstruction with cultured CAL. After six months of the tissue expander (TE) dilation, a second-stage breast reconstruction was performed. Seven weeks before surgery, a small fat sample was excised for stem cell culturing and cryopreservation. During reconstructive surgery, following TE dehydration and temporary removal, aspirated fat combined with cultured stem cells was grafted into the subcutaneous layer, and the TE was returned to the pocket. Subsequent surgeries were conducted every six months until TE removal and final reconstruction. Data on operative frequencies, aspiration and injection volumes, and reconstructed breast volume were collected.

Results: The average number of operations was 3.6, with a total fat harvest volume averaging 979.4 cc. The ratio of the final reconstructed breast volume to the healthy breast was 94%. No major complications were observed.

Discussions: Cultured CAL addresses the limitations of conventional CAL. Future discussions will focus on the potential of cultured CAL and the measures required to ensure its safety and efficacy.



Oral Presentation | Free paper (Body contouring)

R14

Safety of Brazilian Butt Lift Surgery (BBL): Insights from the UK Ban and National Guidelines

Omar Tillo

Creo Clinic, London

Background:

The Brazilian Butt Lift (BBL) procedure has gained popularity worldwide for its ability to enhance hips and buttock shape and size. However, concerns regarding its safety, particularly the risk of fat embolism, prompted the British Association of Aesthetic Plastic Surgeon (BAAPS) to impose a moratorium on performing this procedure in 2018.

Objective:

This presentation aims to explore the events leading to the UK ban on BBL surgery, assess its impact on surgeons and patients, and discuss the efforts made to analyse the safety of the procedure. Additionally, it examines the development and publication of new national guidelines and safety recommendations for BBL surgery.

Methods:

The presentation reviews the timeline of events leading to the UK ban on BBL surgery. It analyses the challenges faced by surgeons following the ban and the risks faced by patients seeking this procedure. Furthermore, it discusses the collaborative efforts undertaken to evaluate the safety of BBL surgery, incorporating both old and new evidence.

Results:

The presentation highlights the comprehensive review of scientific evidence on BBL surgery safety, leading to the formulation of updated national guidelines and safety recommendations. It discusses the key findings from this analysis and the implications for both surgeons and patients considering BBL procedures.

Conclusion:

In conclusion, the presentation emphasizes the importance of evidence-based practice in plastic surgery and the necessity of adhering to strict safety guidelines. It underscores the ongoing efforts to ensure the safety of BBL surgery and provides insights into the future direction of this evolving procedure.

755-nm picosecond laser combined with bioactive polymer dots to reverse photo-damage on nude mouse model

Chang Cheng Chang^{1,2}, Tzong Yuan Juang², Jia Chee Siew³, Yi Hsuan Tu³, Hoi Man Iao², Sian Cian Fan²

¹ Division of plastic and reconstructive surgery, China medical university hospital

² Institute of cosmeceutics, China medical university

³ school of medicine, college of medicine, Chinamedical university

Background: Picosecond laser could produce laser-induced optical breakdown. In addition, polymer dots (PDs) can promote vascular proliferation, achieving skin repair and inhibiting inflammation via epithelial mesenchymal transformation.

Objective: Our research explores a novel approach that combines a 755-nm picosecond laser with bioactive PDs to reverse photo- damage in a nude mouse model.

Methods: Twelve 6-week-old BALB/c nude mice with UVB irradiation, divided into (1) UVB group, and various treatment groups including (2) UVB + PEG1000, (3)UVB + PDs + PEG1000, and (4)UVB + Laser + PDs + PEG1000. All mice are subjected to UVB irradiation over the course of 10 weeks Assessments were conducted using immunohistochemistry (IHC), enzyme-linked immunosorbent assay (ELISA), and Masson's trichrome (MT) staining to gauge collagen content, epidermal thickness, and expression levels of proteins related to photo-damage repair.

Results: MT staining revealed a notable 30% increase in collagen retention within the UVB + Laser+ PD group by day 11. The reduction of MMP-9 levels in UVB+PD+PEG1000 group on day 11 achieving 4.2%, compared to 9.3% in UVB group on day 1 ($p=0.03$). Furthermore, IL-6 levels experienced a substantial decrease across all treatment groups versus the UVB group on day 1, signaling a notable reduction in inflammation ($p < 0.001$). The analysis of Smad2/3 signaling in the UVB+PD+PEG1000 group on day 11 achieving 2.8%, compared to 1.3% in the UVB group on day 1, revealed an enhanced activation of skin repair.

Conclusion: The combination of the 755-nm picosecond laser with bioactive polymer dots provides a therapeutic strategy for reversing photo-damage. This technique not only bolsters collagen production but also promotes a novel pathway for skin repair and aging reversal, meriting further exploration for clinical application.

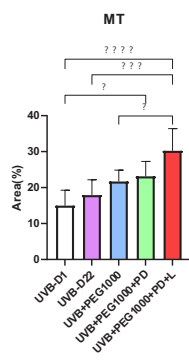


Figure 1.

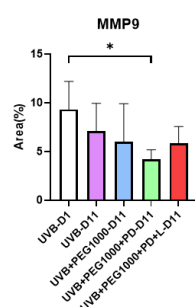


Figure 2.

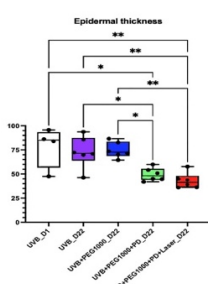


Figure 3.

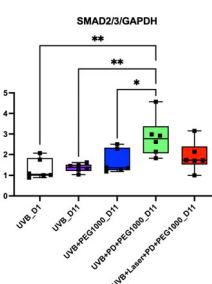


Figure 4.

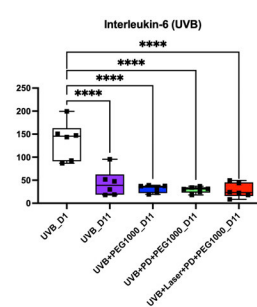


Figure 5.

Oral Presentation | Sydney Coleman award session

R16

Exosomes Combined with Polymer Dots Dressings and 755 nm picosecond laser accelerate wound Healing in Nude Mice

Chang Cheng Chang¹, Yen Jen Wang⁴, Jia Chee Siew³, Yi Hsuan Tu³, Tzong Yuan Juang²

¹ China medical university hospital

² Institute of cosmeceutics, China medical university

³ school of medicine, college of medicine, Chinammedical university

⁴ Divison of dermatology McKay memorial hospital

Background: Exosomes are extracellular nanovesicles mediating intercellular communication. Porcine fallopian tube stem cells (PFTSC)-derived exosomes and polymer dots (PDs) dressings have been proved to promote cells proliferation and migration.

Objective: To investigate whether PFTSC-derived exosomes, exosomes combined with PDs dressings and/or pretreated with a 755 nm picosecond laser with a diffractive lens array accelerate wound healing in nude mice.

Methods: . Fifteen nude mice were randomly divided into five groups: (1) Controls (2) Exosomes (3) Exosomes + PDs (4) Laser + Exosomes (5) Laser + Exosomes + PDs. Full-thickness wounds were created on the back of each mouse. The wound area was evaluated by Image-J. ERK1/2, pro-collagen1/3, collagen1/3, CD31, VEGF, EGF, E-cadherin, Vimentin, Filaggrin, and Aquaporin 3 were examined by the wound tissues with ELISA, immunostaining, and masson trichrome (MT) staining.

Results: Level of VEGF, EGF and CD31 were significantly higher than the control group on day 3 (VEGF, 18% in Laser+Exosomes+PD vs 4% in controls, $p<0.0001$; EGF, 1.6% in Exosomes+PD vs 0.5% in controls, $p<0.01$; CD31, 17% in Laser+Exosomes+PD vs 5% in controls, $p<0.05$). Expression of filaggrin was stronger in Laser+Exosomes+PD group than Exosomes alone (11% vs 6%, $p<0.05$). Wound area was reduced to 13% in Laser+Exosomes+PD group vs 33% in controls($p<0.0001$). MT staining revealed significant increase of collagen (39% in Laser+Exosomes+PD vs 19% in Controls, $p<0.0001$).

Conclusion: The group of exosomes combined with PDs dressings and picosecond laser had demonstrated faster re-epithelization with more collagen deposition and. The combination is potential for further investigation on human chronic wound.

Oral Presentation | Sydney Coleman award session

R17**Using Bilateral Pedicled Transverse Rectus Musculocutaneous Flap and Fat Grafting for Autologous Breast Augmentation**

Tung Dinh Nguyen, Khiem Xuan Pham

Emcas Plastic Surgery Hospital

Background: The silicone gel implant is currently the most popular method of breast augmentation, but its use is associated with a number of risks, including capsular contracture, seroma, implant malposition, visibility of the implant, and anaplastic large cell lymphoma (ALCL). Breast augmentation by fat grafting can avoid the complications of implant breast augmentation, however, the degree of reabsorption of the injected adipose tissue is unpredictable. Fat resorption has been reported by multiple authors, it has been associated with increased fat resorption, which varies between 25-75%, primarily due to fat apoptosis, necrosis, and liquefaction. In the last 20 years, autologous flaps have been used in several studies for breast augmentation to limit complications.

Objectives : To evaluate the effectiveness and safety of using bilateral pedicled TRAM flap combination with fat grafting for autologous breast augmentation.

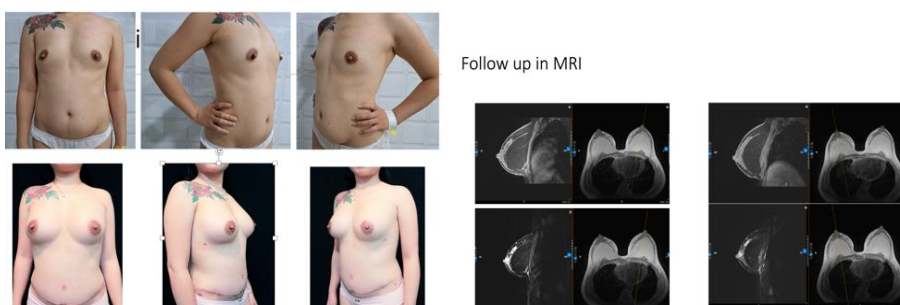Method : Selection criteria of patients: Patients who desire body-contouring surgery with abdominoplasty, no planned pregnancies, do not desire implants, in cases:

- Small breast with or without ptosis, abdominal scar.
- Implant removal due to different reasons: capsular contracture, seroma, implant malposition, visibility of the implant...
- Complication of free liquid silicone injection due to breast augmentation.

Surgical technique : Pocket was made in subglandular position of breast. The transverse rectus abdominis (TRAM) flap with deepithelialized was divided into 2 parts and mobilized off the abdominal wall with its vascular pedicle intact. A tunnel is created in the medial inframammary fold. Flap is positioned in the breast pocket, it is tacked in place and further shaped. The abdominal wall defect is closed. An interposition piece of mesh is necessary inserted to prevent future hernias. Liposuction was performed in the hip waist, fat was grafted at the fat layer around both breasts.

Results : A total of 32 cases met the inclusion criteria. The reason for operation mainly is implant capsular contracture (40.6%), the horizontal scar of the low abdominal area is popular (56.3%), the awaited volume of an autologous lateral TRAM flap is 225.78cc, the average amount of fat grafting is 56.87cc for each breast. Following surgery, no cases of complete or partial flap loss were clinically detected. There were no hernia or bulging issues, and 01 case was an infection. Patients were followed from 6 to 12 months. MRI 3Tesla was used to assess the survival of fat grafting and TRAM flap. Using BREAST -Q to assess the satisfaction of all patients, 68.8% somewhat agree and 31.3% definitely agree with their expectation, 0 % disagree, sum score is 18- 19 (78.2%) equivalent score is 60-64.

Conclusions: The initial success suggested the effectiveness and safety of autologous breast augmentation by using pedicled TRAM flap and fat grafting in the selective patients.



Oral Presentation | Sydney Coleman award session

R18

Innovative approach to total skin substitute with 4th generation biomaterials

Břetislav Lipovský^{1,2}, Veronika Pavlišáková², Eva Horálková¹, Anna Smolnická³, Martin Faldyna⁴, Edita Jeklová⁴, Irena Koutná^{3,5}, Lucy Vojtová²

¹ Department of Burns and Plastic Surgery, Faculty of Medicine, Masaryk University, University Hospital Brno, Czech Republic

² CEITEC – Central European Institute of Technology, Brno University of Technology, Brno, Czech Republic

³ Department of Histology and Embryology, Faculty of Medicine, Masaryk University, Brno, Czech Republic

⁴ Veterinary Research Institute, Brno, Czech Republic

⁵ Cell and Tissue Engineering Facility, International Clinical Research Center, Brno, Czech Republic

Background:

Over the past several decades, there have been dramatic advantages in the quality of care provided to patients with burns. The basic limitation for the 21st century remains the issue of local care. Thanks to the modern possibilities of biomaterial and cell engineering, we can offer these patients effective options for improving the quality of subsequent life.

Objective:

In our current research strategy, we are trying to focus on a dermal regeneration strategy using an innovative stable form of Fibroblast growth factor 2 (FGF2-STAB[®]) and Fibroblast growth factor 7 (FGF7-STAB[®]) targeting to 4th generation biomaterials development for total skin substitute.

Methods:

In the first stage, we developed and successfully evaluated the 2nd generation of biomaterials as part of dermal substitute (unique porous biopolymer collagen chitosan foam enriched with FGF2-STAB[®]). We are now in the second phase of development and evaluation of 4th generation biomaterials containing FGFs and differentiated MSCs.

Results: In the first phase, full biocompatibility of our resorbable dermal substitutes was demonstrated in a swine model within 3 and 6 months of follow-up. Increased neovascularization and fibroproliferation were proved by Chick Chorioallantoic Membrane (CAM) assay and animal model experiment. In the second phase, we successfully seeded cell populations into our biomaterials with growth factors and began to evaluate within *in vitro* and animal models.

Conclusion: Bilayer skin substitute with FGFs demonstrated superior biological activity by neovascularization. Our current ambition is to use tissue engineering methodology for the development of 4th generation biomaterials in total skin substitution.

Acknowledgements: This study was supported by the Ministry of Health of the Czech Republic, grant No. NU22-08-00454 and funds from the Faculty of Medicine number MUNI/A/1598/2023. All rights reserved.

R19

Latissimus Dorsi and Immediate Fat Transfer (LIFT) for Breast Reconstruction after Mastectomy: A Case Series

Sakurako Murata, Kyoko Dogo, Yuzo Komuro

Teikyo University School of Medicine Department of Plastic, Oral and Maxillofacial Surgery

Background: Although the latissimus dorsi (LD) flap is a common option for breast reconstruction, its use is limited by the volume of transferred tissue. The extended LD flap is used to ensure sufficient breast volume, but increases the risk of donor site deformity and seroma formation. Latissimus dorsi and immediate fat transfer (LIFT), first reported in 2014 by Santanelli et al., may help prevent these complications while providing sufficient breast volume.

Objective: The purpose of this study was to report our experience with LIFT in breast reconstruction and evaluate complications and additional operations.

Methods: A retrospective study was performed of 10 patients who underwent unilateral breast reconstruction post-mastectomy using LIFT from November 2019 to May 2024.

Demographic and operative data, complications, and the number of additional operations were analyzed.

Results: The mean patient age was 49.6 years, and the mean body mass index was 22.5 kg/m². The average total fat grafting volume was 228.1 mL. The average duration of dorsal drain placement was 11.3 days. Complications were observed within a mean follow-up period of 25.2 months. Two patients (20.0%) developed a seroma at the donor site. No cases of flap or fat necrosis were noted. Additional fat grafting was performed on one patient to enhance the volume of the reconstructed breast.

Conclusion: LIFT for breast reconstruction is a safe and effective technique to enhance flap volume and prevent seroma formation at the donor site. This approach may expand the indications for the LD flap to more patients desiring autologous reconstruction.

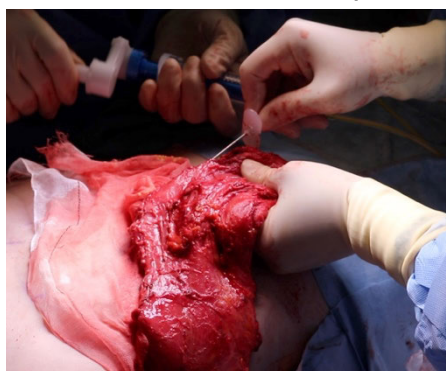


Fig. 1. Intraoperative clinical image demonstrating fat injection into the LD flap.

Oral Presentation | Free paper (Fat for reconstruction/ regeneration 1)

R20

Fat tissue: a decisive treatment for the management of complicated wounds in a high morbidity patient.

CYNTHIA I EUAN VAZQUEZ^{1,2,3,4}, ARNOLDO O TOPETE GONZALEZ¹,
ANTONY JAMES JACKSON⁴, RAUL A VALLARTA RODRIGUEZ^{1,3}

¹ AMCPER

² ISPRES

³ ISAPS

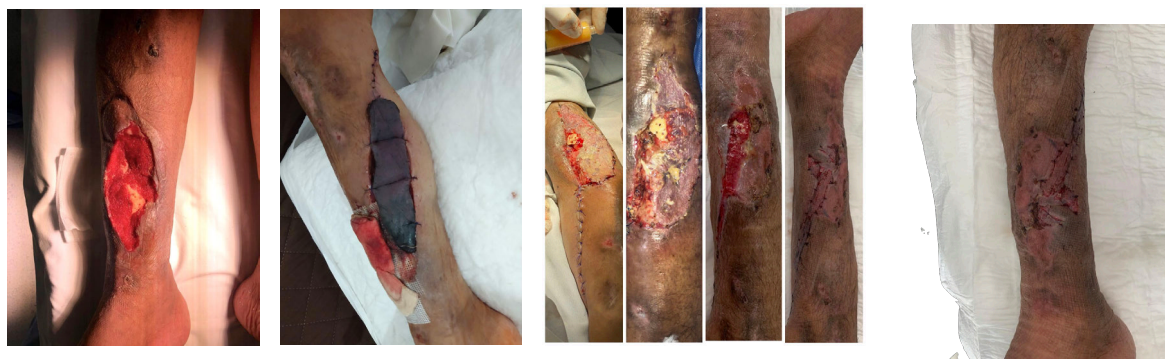⁴ BAPRAS

Background: Fat tissue over the years has been recognised as a treatment in the cosmetic and reconstructive fields for restoration of volumen, also for its endocrine properties of the tissue that allow cell regeneration, stem cells derived from fat tissue are promising and realistic choice in patients where reconstructive treatment alternatives are not an option.

Objective: We wanted to demonstrate with this case that the fat transfer was a decisive option for covering and saving a patient's leg.

Method: In a 76 y/o female patient with chronic renal failure, diabetes mellitus type 2 and systemic arterial hypertension. Two months before she was treated for a reduction of a right tibia fracture, this was performed with complications of bone exposure, tissue loss and a failed soleus flap with necrosis & substantial tissue loss. We performed a fat transfer from the inner thigh to the tibia using the Dr Marco A. Pellon "sandwich" technique three times every 7 days which led to improving tissue coverage and growth, after three weeks we successfully proceeded with a skin graft to the area.

Conclusion: A fat transfer with its exosomes and endocrine functions is a considerable option for patients who require coverage after the loss of tissue in complicated wounds & that also have multiple comorbidities. In this complex case we demonstrated that the fat transfer was an effectiveness option to cover and save the patient's leg.



Oral Presentation | Sydney Coleman award session

R21

Advanced adipose-derived stem cell protein extracts (AAPE) as an alternative regenerative treatment option for bedridden patients.

CYNTHIA I EUAN VAZQUEZ^{1,2,3,4}, ANTONY JAMES JACKSON⁴

¹ AMCPER

² ISPRES

³ ISAPS

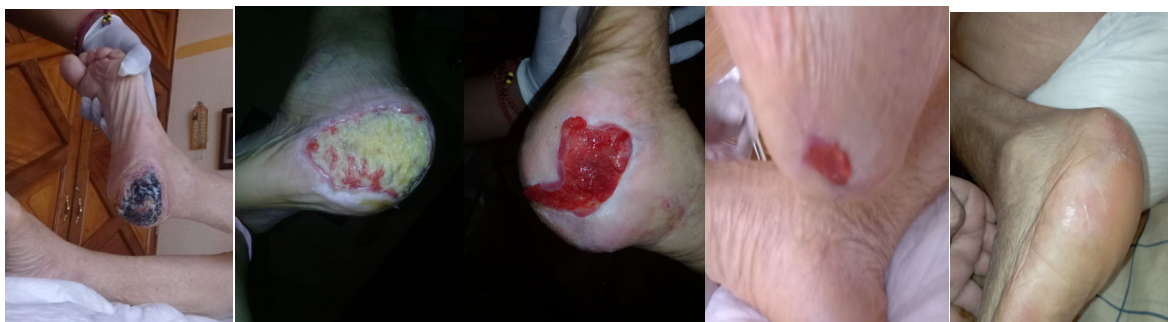⁴ BAPRAS

Background: Advanced adipose-derived stem cell protein extracts (AAPE) have been used instead of live stem cells for their effectiveness in oxidative stress and matrix metalloproteinases (MMPs) related to tissue repair in human dermal fibroblasts (HDFs). In particular, it has been demonstrated that adipocyte-derived agents can be effective in tissue regeneration. Bedridden patients who are susceptible to developing bedsores treatment options are scarce which leads us to look for other non-surgical alternatives to reduce morbidity.

Objective: To demonstrate the effectiveness of the AAPE treatment in a heel pressure ulcer of a bedridden 91 y/o woman with senile dementia.

Methods: We proposed to start the treatment with the AAPE, after one month the patient was treated with wound healing and synthetic dressings without showing any improvement and with increased extension. The AAPE treatment was performed every 30 days, administration was both intradermal and topical with an amount of 2ml of the AAPE all around the wound over a period of six months. AAPE applications were performed simulataneuosly with wound healing techniques such as an antiseptic spray (Microdacyn) and Ketanserin applied gel daily. At the end of the treatment the wound had recovered completely and after 5 years it has not recurrered.

Conclusion: AAPE is an excellent alternative in patients where surgical treaments are unavailable and can be performed at home due to being constitutionally well suited to the promotion of dermal wound healing and secretory factors.



Oral Presentation | ISPRES APRAS award session 2

R22

Use of resected fatty tissues and SMAS tissues auto-grafting in facial rejuvenation

Jinho Lee

AB Plastic Surgery Clinic, Seoul, Korea

Background: Fat grafting is an essential method in facial rejuvenation. When performed with facelift, it could yield a synergistic effect in the aspects of natural appearance and improved skin quality by integrating with facial tissues. Combining with rejuvenation surgery, traditional fat harvest from “far-away” donor site is not mandatory for the facial volumization. During the necklift procedures, supra-plastysmal fat could be delicately resected and reserved. Lateral SMAS tissue after sub-SMAS dissection, as well, could be a useful graft source. These tissues can be finely diced and reutilized as a decent graft source for the facial volume restoration.

Objective: Aim of this study is to investigate the use of obtained fatty and SMAS tissues as autologous graft material during the facelift.

Methods: Retrospective chart review of patients for Sub-SMAS facelift and necklift in conjunction with fat grafting between 2020 and 2023 was performed. Patient assessments were obtained; group 1 (48 patients) with autografting technique and group 2 (31 patients) with conventional fat harvest and grafting.

Results: Group 1 showed similar fat retention and overall result with group 2. (Table 1) Apart from some cases with fat reabsorption, no major complications were observed in both groups.

Conclusion: The use of SMAS tissue as an autograft material has been previously reported. “Neck-to-face” auto-grafted fat was also successfully transited with high predictability and viability. Many primary cases are applicable for this technique with the exception of cachectic patient. Without donor site morbidity, auto-grafting can be another reliable option for simultaneous facial rejuvenation surgery and fat grafting.

Oral Presentation | Free paper (Research)

R25

Optimization of an adeno-associated viral vector for keratinocytes *in vivo*

Qi Shen¹, Yuta Moriwaki¹, Zening Du¹, Shogo Suga², Yusuke Hirabayashi², Masakazu Kurita¹, Mutsumi Okazaki¹

¹ Department of Plastic and Reconstructive Surgery, The University of Tokyo Hospital

² Department of Chemistry and Biotechnology, School of Engineering, The University of Tokyo

Purpose:

The adeno-associated virus vector (AAV) is a powerful gene therapy vector for *in vivo* gene transduction. We have developed a new AAV capsid, named AAVDJK2, which has higher efficiency and specificity to cultured keratinocytes than other AAVs used for keratinocytes in the previous reports. *In vivo* efficacy of AAVDJK2 was tested using mice skin.

Methods:

To test the efficacy of AAVDJK2 to AAVDJ (one of the most efficient AAV in the existing AAVs), we generated GFP-expressing AAVDJK2 and mCherry-expressing AAVDJ. Mixtures of two virus solution were prepared and injected intradermally into mice back skin. The expression of GFP and mCherry in each skin layer (epidermis, dermis, hypodermis, and panniculus carnosus) was quantified by automated and unbiased analysis.

Results:

The number of AAVDJK2-delivered, GFP-positive cells was higher than that of AAVDJ-delivered, mCherry-positive cells in the epidermis, and the opposite trend was observed in deeper layers. Thus, the higher epidermal specificity of AAVDJK2 suggested was confirmed in mouse skin *in vivo*.

Conclusions:

The AAVDJK2 capsid improves gene delivery to the epidermal keratinocytes *in vivo*. The novel AAV system may benefit experimental research and the development of new epidermis-targeted gene therapies.

Oral Presentation | Free paper (Research)

R26

Challenges to Complete Skin Regeneration; Regulation of AMPK and Rac1 Activity Promotes Wound Healing via Induction of Actin Cable Formation

Kento Takaya¹, Yuka Imbe², Qi Wang², Shigeki Sakai¹, Keisuke Okabe¹,
Noriko Aramaki-Hattori¹, Kazuo Kishi¹

¹ Department of Plastic and Reconstructive Surgery, Keio University School of Medicine

² Faculty of Pharmacy, Keio University

Background: Unlike adults, early developing fetuses can completely regenerate tissue. Particularly, mice epidermal structures, including texture patterns, are regenerated until embryonic day (E) 13, leaving visible scars thereafter. Although the changes in actin dynamics are known to be involved in this transition, the detailed mechanism remains unclear.

Objective: We investigated the effects of AMP-activated protein kinase (AMPK) and Rac1, factors involved in regulating cell migration and actin dynamics using mice wound model.

Methods: (1) Regulation of Rac1 activity: PAM212 cell was treated with Rac1 inhibitor NSC23766 and the effect on migration ability was evaluated. We generated epidermis-specific Rac1 knockout mice (K14-CreERT2;Rac1^{flox/flox}) and observed the wound healing process and actin dynamics in fetuses and adults. (2) Regulation of AMPK activity: Fetuses of ICR mice were wounded and AMPK activator salicylate was administered. Wound morphology was analyzed by 3D reconstruction of the wound images, and the presence of actin cable formation and the behavior of related molecules were observed.

Results: Epidermal cell migration was inhibited by NSC23766 and salicylate administration. In epidermis-specific Rac1 knockout fetal wounds and salicylate treated wounds on E14, actin cable formation, which normally disappears, was induced and the wounds regenerated completely.

Conclusion: Actin cables are involved in complete skin regeneration, and we observed that activation of AMPK and induction of actin cable formation through Rac1 regulation induced skin regeneration and accelerated healing. This finding suggests that regulation of AMPK and Rac1 may be a candidate therapeutic approach to improve the wound healing process.

Oral Presentation | Sydney Coleman award session

R27

Gene Therapy Using Adipocytes

Yoshitaka Kubota, Kentarou Kosaka, Yoshihisa Yamaji, Shinsuke Akita, Yoshiro Maezawa, Masayuki Kuroda, Kotaro Yokote, Nobuyuki Mitsukawa

Chiba University

Introduction: Subcutaneous adipose tissue is familiar to plastic surgeons and can be harvested minimally invasively, making it a promising material for regenerative medicine. We report the world's first gene therapy using patient-derived subcutaneous adipose tissue for a patient with lecithin-cholesterol acyltransferase (LCAT) deficiency.

Case & Methods: A male in his 20s was diagnosed with LCAT deficiency after presenting with corneal opacity and low HDL cholesterol levels. Subcutaneous adipose tissue was aspirated from the patient's abdomen, treated with collagenase, and centrifuged. Floating fractions were cultured using the ceiling culture method to isolate ccdPAs. LCAT genes were introduced using a retroviral vector. The cells were cultured and, three weeks post-harvest, 1×10^9 cells were injected subcutaneously into the abdomen with fibrin glue.

Results: After 240 weeks, there were no significant adverse events, and we observed sustained beneficial effects such as increased LCAT activity, normalization of lipid profiles, and reduced proteinuria.

Discussion: The average lifespan of adipocytes is approximately ten years, allowing for long-term survival post-transplantation. For plastic surgeons, subcutaneous adipose tissue is easy to harvest with minimal invasiveness. Adipose tissue is the largest endocrine organ in the human body and inherently has high secretory capabilities, making it suitable as a vehicle for gene therapy. This study represents the first use of adipocytes in human gene therapy, with maintained effects observed over four years. Future applications may include hemophilia and diabetes. It is crucial for plastic surgeons to lead the research on adipocyte-based therapies.

R28

Frozen Assets: A Comprehensive Review of Adipose Tissue Cryopreservation Techniques and Our Personal Experience

Benedetta Agnelli¹, Matteo Malacco²

¹ Division of Plastic and Reconstructive Surgery, Department of Biotechnology and Life Sciences, University of Insubria, Varese, Italy

² FMH Plastic, Reconstructive and Aesthetic Surgery, Lugano, Switzerland

Background: Autologous fat transplantation (AFT) is a common procedure in plastic and reconstructive surgery, with growing applications. Despite its benefits, the literature reveals a highly variable and unpredictable absorption rate of transplanted fat, posing significant limitations. Multiple sessions are often required, increasing patient discomfort and potential complications. Adipose tissue cryopreservation has recently emerged as a promising solution to these challenges, although no ideal protocol exists yet.

Objective: We aim to present our research in the field, review the current clinical applications documented in the literature, and explore exciting future prospects for using preserved lipoaspirates in repeated fat grafting procedures or as cell-based therapies for reconstructive purposes.

Methods: We conducted a systematic literature review in line with the Preferred Reporting Items for Systematic Reviews and Meta-Analyses (PRISMA) guidelines. We utilized specific keywords and predefined MeSH terms across various search engines. Concurrently, we present our method and compare it with the findings of the literature.

Results: A total of 24 studies have been included in the review. Dimethyl sulfoxide (DMSO) is the most commonly used cryopreservative agent. Several parameters including cell viability, cell morphology, toxicity and methods of freezing and thawing have been investigated.

Conclusion: Determining the most effective and straightforward method for adipose tissue cryopreservation is a complex and debated issue with multiple approaches available. However, promising new techniques are emerging in the literature, suggesting a bright future for this field.

Oral Presentation | Free paper (Fat for the breast 1)

R29

Nano fat grafting improves radiation skin changes in breast cancer patients

Paulo Piccolo

National Center for Plastic Surgery

Background:

Regenerative properties of fat grafting have been widely confirmed. More recently nanofat has been shown to carry the same growth factors and mesenchymal cells in a more concentrated way, confirming its valuable regenerative properties in a wide range of cases.

Objective:

This study focuses on the use of nanofat deposit in breast cancer patients to improve radiation changes.

Methods:

This is a retrospective review of the author's experience using nanofat grafting deposited via a microneedling device over radiated skin of breast cancer patients. Three patient cases were reviewed. Surgeries were performed under general anesthesia. The fat was harvested from the flanks using suction assisted lipectomy with the Tulip system and a 50cc syringe. The fat was decanted and the excess fluid/oil was removed. The remainder of the fat was emulsified using the Single-use nanofat transfer kit from Tulip (Tulip Medical Products, San Diego, USA). The nanofat was delivered directly on the affected skin using a microneedling device at 2.5mm depth, until punctate bleeding was noted. The amount of volume deposited was between 30-35cc.

Results:

The procedure was performed once in each patient. The patients were all female. The age range was 37-62 years old. All three had unilateral invasive cancer diagnosis. Two had radiation after lumpectomies (one of which had a skin-sparing mastectomy – SSM - to follow) and one had radiation following a SSM. The timing from radiation before the nano fat procedure ranged from 6 months to 3 years. Two patients had a previous abdominally based free flap 6-8 months prior and one patient had an oncoplasty reconstruction following a lumpectomy prior to the nanofat procedure. They all had one session of nanofat grafting. Follow-up ranged from 2 - 17 months. All patients experienced an improvement in the quality of the skin in the way of improved elasticity, improved hyperchromia, and increased skin softness. There were no complications.

Conclusion:

Nanofat grafting is a good adjunct procedure in improving the overall skin elasticity, softness and color following radiation for breast cancer.

Oral Presentation | Free paper (Stem cells/ Tissue engineering)

R30

THE “EMPANADA” REGENERATIVE IMPLANT FOR DIRECT TO IMPLANT BREAST RECONSTRUCTION

Andrew Salzberg

Cleveland Clinic

Background: A 5 year experience of novel tissue construction for outpatient prepectoral immediate breast reconstruction will be discussed with outcomes and complication data in more than 100 patients in the United States.

Objective: To enhance the immediate direct to implant breast reconstructive long and short term outcomes in implant based breast reconstruction

Methods: Description of the novel technique with patient cohort data and outcomes will be presented

Results: In over 100 patients and 168 breasts in prepectoral postmastectomy reconstruction the short and term evaluated results show lower than expected incidence of hematoma, infection and capsular contracture over 5 years.

Conclusion: This novel regenerative construct is applicable to immediate implant based breast reconstruction worldwide with low complication rates done as an outpatient procedure.

Oral Presentation | Sydney Coleman award session

R31

Exploring Strategies to Enhance Fat Retention Rates-A Case Study on Breast Fat Grafting

JIANBO SANG

Shanghai Beaucare Clinics

Background: Breast fat grafting is a common method of autologous fat transfer in cosmetic and reconstructive surgeries, with outcomes often limited by fat retention rates. Traditional fat processing methods (such as settling, centrifugation, and filtration) have their limitations. Addressing these issues, the adoption of improved fat processing techniques could significantly impact fat retention rates.

Research Objective: This study aims to evaluate the impact of a novel fat processing method—gauze filtration combined with rinsing and cotton pad dehydration—on the retention rate of breast fat grafts and to analyze its effects on postoperative breast size stability.

Methods: The study included 195 patients who underwent breast fat grafting from August 2017 to May 2024. All patients underwent fat preparation using gauze filtration, rinsing, and cotton pad dehydration to produce ultrapure fat, carefully selecting fat without fascia for transplantation. Patient breast circumference, under-breast circumference, and weight were measured regularly to track long-term postoperative outcomes, especially the changes in breast circumference under relatively stable weight conditions.

Results: During the postoperative follow-up period, most patients showed a minimal range of changes in breast circumference, indicating high fat retention rates and good stability of breast morphology. Additionally, among the 15 patients who underwent a second fat grafting, those treated with the repeated use of the improved fat processing method demonstrated better retention outcomes than those from the single surgery.

Conclusion: The fat processing method using gauze filtration and cotton pad dehydration significantly enhanced the retention rate of breast fat grafts and the stability of postoperative breast size. This method provides an effective technical strategy to improve the outcomes of fat grafting and warrants further research and clinical application.

Keywords: Breast fat grafting, fat retention rate, fat processing techniques, long-term follow-up, breast morphology stability

Oral Presentation | ISPRES APRAS award session 2

R32

Strategy for Treating Gummy Smile: A Simple and Powerful Resolution with Fat Grafting

Wen-Hui Chen¹, I-Feng Sun², Tsai-Ming Lin³

¹ Department of Dentistry, Eda hospital, Kaohsiung, Taiwan

² Astrid Clinic, Kaohsiung, Taiwan

³ Charming Institute of Aesthetic and Regenerative Medicine (CIARS), Kaohsiung, Taiwan

Background: A gummy smile, characterized by excessive gingival display, can significantly affect aesthetic appeal and self-confidence. Traditional treatments, including botulinum toxin injections and various surgical interventions, offer inconsistent results and have their limitations. This study investigates the use of Micro-Autologous Fat Transplantation (MAFT) as a novel and effective approach for treating gummy smiles.

Objective: To evaluate the long-term efficacy, patient satisfaction, and safety of the MAFT technique in correcting gummy smiles.

Methods: A retrospective analysis was conducted on 50 patients treated for gummy smiles using the MAFT technique. The procedure involved harvesting fat from donor sites, centrifuging it, and micro-transplanting it into the nasolabial groove, philtrum, and upper lip areas under local anesthesia. Patients were followed up over an average of three years to assess the reduction in gingival display, patient satisfaction, and the occurrence of any complications.

Results: The MAFT technique significantly improved the appearance of gummy smiles in all patients, with an average reduction in gingival display of 3-5 mm. Enhanced volume and thickness of the upper lip and nasolabial areas contributed to the aesthetic improvement. The procedure had a high patient satisfaction rate, with over 95% of patients reporting favorable outcomes. The results were well-maintained over the three-year follow-up period, and minimal complications were observed.

Conclusion: MAFT provides a reliable, minimally invasive, and effective solution for treating gummy smiles, offering long-term results and high patient satisfaction. This technique improves aesthetic outcomes by enhancing lip volume and reducing gingival display, making it a valuable tool in aesthetic and reconstructive surgery. Future advancements in this technique are anticipated to further refine its precision and efficacy, ensuring optimal clinical outcomes.

Oral Presentation | Free paper (Stem cells/ Tissue engineering)

R34

Innovative Solutions in Scalp Wound Reconstruction: Experience with NovoSorb® BTM

Benedetta Agnelli¹, Luigi Valdatta¹, Monica Falaschi², Emiliano Bernuzzi²,
Simone Dusi¹, Federico De Maria²

¹ Division of Plastic and Reconstructive Surgery, Department of Biotechnology and Life Sciences,
University of Insubria, Varese, Italy

² ASST Ovest Milanese, U.O.C. Chirurgia Plastica e della Mano

Background: NovoSorb® Biodegradable Temporising Matrix (BTM) is a fully synthetic dermal matrix used for reconstructing complex wounds. Comprising a 2mm-thick biodegradable polyurethane foam covered by a non-biodegradable membrane, NovoSorb facilitates cellular infiltration and neodermis formation, making it a vital tool in wound management. Many wounds, especially those on the scalp, pose significant reconstruction challenges due to their complexity and location.

Objective: This study aims to present our personal experience with NovoSorb BTM, a recent innovation in wound care technology that is still underutilized in Italy. We focus on its application in scalp lesions, highlighting the potential benefits and effectiveness of this synthetic dermal matrix in complex wound reconstruction.

Methods: We conducted a retrospective observational study involving patients treated with NovoSorb BTM for scalp lesions. Data on patient demographics, wound etiology, treatment timeline, integration period, and complications were collected and analyzed. The primary outcome was the successful integration of BTM, followed by a full-thickness skin graft (FTSG) application. Secondary outcomes included the time to BTM integration and the rate of complications during the treatment process.

Conclusion: Our findings indicate that NovoSorb BTM is a robust and effective option for managing complex scalp wounds, even in patients with comorbid conditions. Successful BTM integration allowed for subsequent FTSG in the majority of cases, demonstrating its potential as a valuable reconstructive tool. Further research is recommended to optimize its use and to better understand the factors influencing integration and overall treatment success.

E-poster

R33

Overcoming the three-dimensional complexity of vulvar defects: a stepwise, multi-flap approach

Chuan Han Ang, Bien Keem Tan, Kok Chai Tan, Chee Liam Foo

Singapore General Hospital

Background:

Complex vulvar defects are challenging owing to their three-dimensional nature and proximity to the vaginal, urethral and anal orifices.

Objective:

The purpose of this paper is to introduce the concept of a multi-flap reconstructive approach to these defects based on anatomical subunits.

Methods:

Four female patients with complex vulvar defects characterized by involvement of the vaginal wall, the anal canal and the perineum, secondary to extra-mammary paget's disease or squamous cell carcinoma resection, were studied. Defect size ranged from 108 to 157cm². The outcomes were analyzed clinically and by a 4-point questionnaire regarding micturition, defecation, coital function, introitus opening and aesthetics.

Results:

The anatomical subunits of the vulva were covered primarily by the gluteal fold flap, with additional flaps including the mons pubis rotation flap, the gracilis muscle flap, and the medial thigh VY advancement flap. The associated perianal skin and anal canal defects were covered by the buttock VY advancement flap and the gluteal fold flap. There were no flap complications. The average follow-up duration was 7 years. Patients' satisfaction with their aesthetic and functional outcomes was favorable.

Conclusion:

Gluteal fold flaps were the workhorse flaps for perineal reconstruction of defects involving the vulva and anus. Additional local flaps were employed strategically in a staged manner, with the aim of preserving native anatomical features and minimizing functional impairments.

Oral Presentation | Sydney Coleman award session

R35

Superior retention of aged fat graft by supplementing young adipose-derived stromal cells in a murine model

Ki Yong Hong¹, Vinh Vuong The Tran², Xian Jin³, Xin Ye Zhou¹, Hak Chang¹

¹ Department of Plastic and Reconstructive Surgery, Seoul National University Hospital, Seoul National University College of Medicine, Seoul, Korea

² Hi-Tech Center, Vinmec Healthcare System, Hanoi, Vietnam

³ Department of Plastic Surgery, the Second Affiliated Hospital, Medical School, Zhejiang University, Hangzhou, China

Background: In general, unpredictable graft retention (26% to 83%) is a critical disadvantage, especially for aged recipients. The supplementation of adipose-derived stromal cells can improve residual volume in young recipients; however, its efficacy on aged recipients remains unclear.

Objective: This study used the aged murine model to examine the effects of supplemented aged and young adipose-derived stromal cells in graft retention.

Methods: Adipose-derived stromal cells from aged and young donors were characterized by detecting the β -galactosidase activity and p16/INK4A marker. Aged, young, and no adipose-derived stromal cell (ASC) groups (n = 6/group) received 150 μ L of green fluorescent protein fat mixed with 3×10^5 aged, young, or none DsRed adipose-derived stromal cells on the scalp, respectively. Graft volumes were evaluated using micro-computed tomography. The vessel density and fates of stromal cells and fat were tracked using immunofluorescent staining.

Results: The young ASC group showed higher cell proliferation ($p = 0.03$) and lower β -galactosidase activity than the aged ($p = 0.002$). The volume retention of grafted fat in the young ASC group was significantly higher than that in the 'no ASC' and 'aged ASC' groups ($p < 0.001$, $p = 0.002$, respectively; median: no ASC group = 41.03%, aged ASC group = 52.15%, young ASC group = 65.21%). Aged and young ASC groups showed significantly higher vascular density than that of the no ASC group ($p = 0.006$ and $p < 0.001$, respectively).

Conclusion: Regardless of the donor age of stromal cells, compared with conventional fat grafts, improved fat graft retention was observed in fat grafts enriched with adipose-derived stromal cells in aged mice. Better graft retention was achieved when supplementation was performed using young adipose-derived stromal cells. However, further validation using larger animal models is required.

R36

Adipose-Derived Stem Cell Injections to Improve Outcomes of Facial Fat Grafting: A Retrospective Study of 100 Patients

Amani Landoulsi Helal^{1,2,3,4,5,6}

¹ International Society of plastic Regenerative Surgery

² American Society of Plastic Surgeon

³ International Society of Aesthetic Plastic Surgery

⁴ Société Française de Chirurgie Plastique Reconstructrice et Esthétique

⁵ Emirates Plastic Surgery Society

⁶ Arab Association of Surgical and Medical Aesthetic

Background: Facial aging is a multifaceted process involving changes to the facial skeleton, soft tissue atrophy, sunken eyes, and long-standing skin alterations. Aging, being dynamic, can be modeled, and fat grafting offers a method to rejuvenate and transform tissues. Initial attempts at facial fat grafting aimed not only to restore fullness but also to enhance tissue quality, including scar improvements. Introducing stem cell injections post-fat grafting presents a potential advancement for optimal results.

Method: Since 2017, a retrospective review of 100 cases (77 females and 23 males) over four years was conducted to evaluate a novel approach combining standard fat grafting with adipose-derived stem cell (ASC) injections. Fifty patients received individualized ASC corrections following the fat grafting procedure. These corrections were administered at 1, 3, 6, and 9 months post-surgery, with the dosage tailored to the recipient site and desired effect.

Results: Follow-up durations ranged from 12 to 48 months. Satisfactory outcomes were noted in 96% of cases. Typical cases were reviewed, showcasing significant improvements in facial volume and skin quality.

Conclusion:

The present study provides the anatomical and clinical basis for the concept of compartmentally based fat grafting. It allows for the restoration of facial fat volume close to the physiologic state. ASC is the best guaranty to get the result that you need. With this procedure, a non-surgical face lift with natural and youthful facial contour could be rebuilt with a high satisfaction rate.

Keywords: Fat grafting, adipose-derived stem cells, face rejuvenation, stem cell injections, facial aging, soft tissue atrophy, facial volume restoration, non-surgical facelift, skin improvement.

Oral Presentation | Free paper (Fat for the breast 1)

R37

Transformative Role of Autologous Fat Grafting in Breast Reconstruction: A Case Report

Amani Landoulsi Helal^{1,2,3,4,5,6}

¹ International Society of plastic Regenerative Surgery

² American Society of Plastic Surgeon

³ International Society of Aesthetic Plastic Surgery

⁴ Soci  t   Francaise de Chirurgie Plastique Reconstructrice et Esthetique

⁵ Emirates Plastic Surgery Society

⁶ Arab Association of Surgical and Medical Aesthetic

Purpose: To illustrate the significant impact of autologous fat grafting in breast reconstruction through a detailed case report, demonstrating how this technique can overcome complications and enhance patient outcomes in complex surgical scenarios.

Case Presentation: This report examines the case of a 53-year-old female with a history of high-grade ductal carcinoma (T3 N0 M0) in the left breast. She underwent a skin-sparing mastectomy with areola preservation and a prophylactic mastectomy of the right breast, followed by bilateral implant-based reconstruction. Post-surgery, the patient received chemotherapy and radiotherapy at Cologne University Hospital. In March 2020, she experienced bilateral implant rupture. Implant replacement in June 2020 led to complications, including infection and exposure of the left implant.

Challenges: By November 2020, the patient presented with chronic infection, fistula formation, radiodermis, nipple deformity, and multiple retracted scars. Given her history of radiotherapy and infection, she was considered a poor candidate for traditional reconstructive techniques. Additionally, she refused to undergo any free flap surgeries.

Intervention and Outcome: Autologous fat grafting was employed to address these complications. This technique improved tissue quality and volume, revitalizing irradiated tissues and enhancing aesthetic outcomes. The intervention successfully resolved chronic infections, reduced scarring, and corrected deformities. The patient's satisfaction with the aesthetic results was significantly improved, demonstrating the efficacy of fat grafting in complex cases.

Conclusion: This case highlights the transformative role of autologous fat grafting in breast reconstruction, particularly for patients with challenging surgical and oncological histories. Fat grafting not only offers a less invasive alternative but also addresses complications effectively, improving tissue health and aesthetic outcomes. This case underscores the importance of considering fat grafting in reconstructive surgery to enhance patient satisfaction and quality of life.

Keywords: Fat grafting, Breast reconstruction, Irradiated breast, Autologous reconstruction, Case report, Chronic infection, Aesthetic outcomes

This abstract demonstrates how a specific case can illustrate the broader importance of autologous fat grafting in breast reconstruction, emphasizing its benefits in resolving complications and enhancing patient outcomes.

Oral Presentation | Sydney Coleman award session

R38

Metabolic Control in Adipose-Derived Stem Cell Modulation of Dendritic Cell Maturation via Notch Activation Pathway

YU CHI WANG, Yur Ren Kuo, Rong Fu Chen

Division of Plastic & Reconstructive Surgery, Department of Surgery, Kaohsiung Medical University Hospital

Background:

Adipose-derived stem cells (ASCs) are considered as potential immunomodulators and could prolong the survival of vascularized composite allotransplantation (VCA). Matured dendritic cells (DCs) present the alloantigen to effector T cells and induce the immune rejection or inflammation. Studies showed that Notch pathway and metabolic control are crucial in modulating DC maturation and function.

Objective:

To investigate the roles of Notch and metabolic control in ASC-modulated and tolerogenic DCs, respectively, to develop strategies for improving VCA survival.

Methods:

ASCs, myeloid DCs, and CD4⁺ T cells were isolated from Lewis rats. DCs were co-cultured with ASCs to assess suppressive effects, and Notch signaling was blocked using DAPT. DC maturation markers, Notch1, Jagged1, IDO expression, PI3K/Akt/mTOR pathway, and cytokine levels were analyzed via flow cytometry, PCR, Western blotting, immunofluorescence, and ELISA. Myeloid DCs were treated with LPS, Vit.D3, dexamethasone, 2-DG, and metformin. Metabolic status was assessed using Mito stress tests on a Seahorse XFe Analyzer.

Results:

ASC-treated DCs showed high Notch1 and Jagged1 expression, reduced maturation markers, increased TGF- β , IL10 levels, and suppressed IFN- γ . Notch inhibition by DAPT reversed these effects. ASC-pretreated DCs induced Treg cell expansion, reversed by DAPT. Tolerogenic DCs and 2-DG-treated DCs had high ATP content and respiration activity. PI3K, p-AKT, and mTOR expressions were upregulated in tolerogenic DCs and 2-DG-treated DCs but suppressed in metformin-treated DCs.

Conclusion:

ASC modulation of DC maturation via Notch1 pathway and metabolic control through PI3K/Akt/mTOR signaling represent potential strategies for immune modulation to enhance VCA survival. These findings could inform future therapeutic approaches in transplantation immunology.

Oral Presentation | Free paper (Research)

R39

Possibility of using AI deep learning to assist in the diagnosis of vascular and pigmentary disorders

KOJI NISHIHORI¹, MAI NISHIHORI¹, DAISUKE OMOTO¹, TORU TANAKA²

¹ NISHIHORI PLASTIC SURGERY CLINIC

² MIRAIZU MEDICAL Co., Ltd.

[Objective] Build a diagnostic AI for bruises, age spots, etc.

[Method] Images taken at our hospital between 2013 and 2023 that were diagnosed as vascular diseases (red bruises) and pigmentary diseases (blue bruises) were extracted. Images were randomly extracted and trained using the names of diagnoses given by doctors in the past as training data.

As a model for distinguishing and recognizing bruises, (1) a cropping model for object recognition and (2) a long-distance image model for object detection were constructed, and a model for distinguishing and detecting bruise types was processed.

(1) Images were manually cropped to create images limited to the affected area, and each image was labeled, and the images and symptom name labels were combined and trained using Microsoft Azure. (2) The long-distance image model was also trained in the same way as .

[Result] We confirmed whether AI can perform image diagnosis and consider the number of treatments for vascular diseases (infantile hemangiomas).

In addition, we found that AI can classify melanin-related diseases (spots such as ectopic Mongolian spots and senile lentigo).

Oral Presentation | Free paper (Face)

R40

Synergy of facial aesthetic surgery with fat transfer maximizing facial beauty

Smilja Tudjarova Gjorgova¹, Igor Peev¹, Tomislav Jovanovski¹,
Nina Karadjinova², Gloria Gjorgova²

¹ Uni_Clinic for Plastic and Reconstructive Surgery, Medical Faculty -Skopje

² Akus Medikus, blvd.11Octomvri 86/3/1-Skopje

Background: Synergy of facial fat transfer with eyelid surgery, cheiloplasty, chin, rhinoplasty, harmoniously aligned facial symmetry and beauty. This innovative method involves own fat to enhance facial volume, long lasting effects and diminish the appearance of wrinkles, natural and enduring approach.

Objectives:

Deflation of the faces associated with aging can be restore with fat cells – lipofilling to the mallar, nasojugal and tear trough deformity reestablished attractiveness of the face.

Methods:

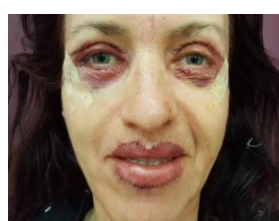
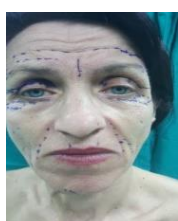Some of classic aesthetic surgical procedure of the face: blepharoplasty, rhinoplasty, cheiloplasty, chin fullness were combined with lipofilling procedure. Key areas for facial fat transfer are: hollows under the eyes, cheeks, jawline, lips, chin, and cleavage.

Results: From May 2022-May 2024, we performed 134 aesthetic face procedure: 51(38,1%) rhinoplasty, 73(54,5%) blepharoplasty, 10(7,5%) cheiloplasty, Face-neck lipofilling: 16(11,9%) chin lipofilling, 114(85,1%) cheeks, nasolabial, under eye hollow and jawline lipofilling, 4(2,9%) cleavage lipofilling.

Overcorrection was performed with awareness that will be some volume loss over a period of time. Post –operatively, patients were followed-up, 2 weeks and 6 month. They were asked to rate their level of satisfaction using “Five-point” score (1-poor, 2-fair, 3-good, 4-very good, and 5-exellent).

Conclusion:

The benefits of combined approach are amplified results, extended longevity, natural appearance, enhanced skin texture. Facial fat transfer is highly regarded procedure in cosmetic surgery, significant benefits that contribute to its popularity and effectiveness.



Oral Presentation | Free paper (Research)

R41**AI-Driven Age Estimation for Evaluating Non-Surgical Facial Rejuvenation Techniques**

Khaled Alameddine, Karim Bakri

Mayo Clinic, Division of Plastic Surgery, Rochester, MN. USA

Background: Our study introduces an innovative AI model designed to estimate perceived age from facial characteristics, aiming to enhance the evaluation of non-invasive procedures.

Objective: To accurately assess the impact of non-surgical facial rejuvenation techniques on perceived age, facilitating the customization of treatments to each patient's unique facial aging profile.

Methods: Employing a deep convolutional neural network (DCNN), we initially trained the model on the extensive ImageNet dataset and further refined with 523,051 pre-annotated facial images. The Xception architecture was selected for its superior feature extraction capabilities. This model was further refined and tested on a set of 10,000 patient faces from the Mayo Clinic's database. Regression analysis and softmax probability were utilized for precise age estimation (Agbo-Ajala et al., 2022).

Results: The AI model demonstrated a high accuracy rate of 91.8% in estimating the perceived age of patients prior to non-surgical treatments, with a standard deviation of 4.3 years. Post-treatment, the AI model identified an average perceived age reduction of 6.8 years across all patients, with significant variation among different non-surgical techniques. Treatments such as dermal fillers and Botox showed the most pronounced age-reduction effects. Heat maps were utilized to identify specific facial regions that contributed most to the AI's age predictions, showing a strong correlation between these regions and the areas targeted by non-surgical treatments.

Conclusion: By leveraging advanced AI technology to refine aesthetic treatment evaluation, this study underscores the potential for personalized non-surgical interventions, contributing to the advancement of patient-specific rejuvenation strategies in the field of aesthetic medicine

References

Agbo-Ajala O, Viriri S, Oloko-Oba M, Ekundayo O, Heymann R. Apparent age prediction from faces: A survey of modern approaches. *Front Big Data*. 2022 Oct 26;5:1025806. doi: 10.3389/fdata.2022.1025806. PMID: 36387012; PMCID: PMC9644213.
<https://pubmed.ncbi.nlm.nih.gov/36387012/>.



Oral Presentation | Free paper (Face)

R44

Facial liposuction and contouring with CT scan

HANJEONG LEE

ATOP Plastic Surgery Clinic

Background: Recently, there is an increasing number of procedures that facial contouring surgery to improve shape of the face. It is difficult to apply a bone surgery for the contour of the face line because return to daily life is delayed by long lasting swelling and hematoma. Therefore, I think that the satisfaction of the result can be improved by considering minimal invasive facial liposuction and fat graft with aspirated fat in same operation field. In addition, checking the thickness of soft tissue using CT scan is helpful in producing good results.

Methods: To create a V-shaped facial line, the front and side effects are important. In front view, to reduce the facial width, the volume of the subcutaneous fat layer and buccal fat must be reduced, and the volume of the masseter muscle in the mandibular angle area must be reduced. In side view, the volume of the submental area called the double chin must be reduced and the subcutaneous fat layer below the mandible borderline must be reduced to sharpen the jaw line and make the face look smaller.

Results: The facial width was reduced by suctioning of fat from the cheek area and reducing the masseter volume through Botulinum toxin, and the neck line was improved by suctioning of fat from the submental area.

Conclusion: Facial liposuction helps with facial contouring. In addition, by performing a CT scan before surgery, the results and satisfaction can be improved by accurately identifying the area to be suctioned.

Oral Presentation | Free paper (Fat for reconstruction/ regeneration 1)

R45

Cryopreservation of Adipose tissue: Changing the paradigm of regenerative medicine

Olivier Amar, Ahsan Khan

Uvence and private practice

Adipose tissue cryopreservation has gained interest since the discovery of mesenchymal stem cells in 2001. In 2013, a new method for processing and injecting adipose tissue was introduced by Alexis Verpaele & co, involving emulsification and filtration to obtain Nanofat, a regenerative cell-rich fluid product compatible with small needles for injection.

Through a fruitful collaboration with the Uvence team, we have developed a process to harvest, purify, and cryopreserve adipose tissue from patients. This has resulted in a remarkably high recovery rate of viable nucleated cells per cc of emulsified fat, containing a majority of regenerative cells and a high viability.

Our team has meticulously validated a cutting-edge cryopreservation and thawing method for adipose tissue. After rigorous testing of various cryoprotective agents, the most suitable one is carefully selected for the cooling process. Different storage temperatures are compared, and the thawing method is thoroughly validated to safely remove any potentially toxic cryoprotective agents.

We have leveraged cryopreservation of adipose tissue to make regenerative medicine accessible to all doctors. Studies on our cryopreservation process indicate that the adipose tissue's volume recovery post-thawing was an impressive 99.8%, and post-emulsification was 91.8%. The recovery of regenerative cells was 91.8%, with cell viability of 85%, and these will be presented at the congress.

Oral Presentation | ISPRES APRAS award session 2

R46

Extensive scar reconstruction with fat grafting and microcoring technology.

Ki tae Kim

TAE plastic surgery clinic

Reconstructing large scars from various causes takes a lot of work. Different methods have been tried, including subcision, rigotomy, and other methods for large depressed scars. To repair depressed scars, sophisticated fat grafting is an essential surgical procedure and can give good results. I want to introduce you to a new technique called microcoring, which can be used with traditional surgical methods to achieve good results with a quick recovery period.

Unlike many lasers and energy-based devices, microcoring devices can mechanically remove scar tissue without thermal energy. Unlike other methods of scar treatment, microcoring technology can mechanically remove hard scar tissue to achieve much faster scar improvement and soften the subcutaneous tissues mechanically held in place by the scar tissue. This process can be used as an alternative or complement to conventional ablative procedures. This vertical removal process, in combination with the usual horizontal subcision process, can result in a much smoother scar. Therefore, it can facilitate simultaneous fat grafting and increase the fat survival rate. It is expected that the scar removal procedure using these microcores and the simultaneous fat grafting procedure will be able to treat large depressed scars effectively.

Oral Presentation | Free paper (Body contouring)

R47

Autologous Fat Transfer with PRP for Penile Augmentation: A Safe and Effective Procedure Performed Under Local Anesthesia

Timothy Neavin

Beverly Hills

Background: Historically, there have not been many safe, effective, and predictable methods to enlarge the penis. Fat transfer to the penis with platelet rich plasma has been performed by this author under local anesthesia in over 40 men since 2016. The technique, after care, and complications are addressed.

Objective: The goal of this presentation is to describe the technique of fat transfer with PRP, identify suitable candidates, how to deal with patient expectations, and how to address potential complications.

Methods: The last 40 patients have been evaluated for subjective, photo documented for penile size increases, and complications related to the surgery, as well as aesthetic changes.

Results: Over 90 percent of men (92.5%) were satisfied with respect to their size increase. The revision rate was 27.5 percent, there were 2 infections, and 4 cases of visible nodularity that required intervention.

Conclusion: Fat transfer to the penis is a safe, effective, and predictable method to enlarge the penis. However, post operative care can be time consuming in patients when complications arise.

Oral Presentation | Free paper (Fat for the breast 1)

R48

Exploration of Injection Levels for Autologous Fat Transplantation Breast Augmentation Surgery

Chengsheng Liu

Beijing JingmeiMedical Beauty Clinic, China

Background: To ensure the effectiveness of over 5000 cases of autologous fat grafting breast augmentation, a very important factor is the detailed control of fat particles at the injection level in the breast.

Objective: To achieve better results and fewer complications in autologous fat grafting breast augmentation surgery.

Method: Precise injection and filling of fat particles in the subcutaneous layer, superficial fascia layer, deep superficial fascia layer, muscle layer, and lower muscle layer of the breast, in order to maximize the survival of injected and , transplanted fat particles, prevent the accumulation of fat particles, avoid fat necrosis, and reduce the occurrence of complications such as fat lumps.

Results: Nearly 4800 cases showed good results, with no visible or palpable nodules or masses, and a small number of cases had nodules with an average diameter of less than 5 mm visible on ultrasound.

Conclusion: Accurate and detailed control of autologous fat injection at the breast injection level is a key factor for the success of fat transplantation breast augmentation.

Oral Presentation | Sydney Coleman award session

R49

AlloClae, A Novel Ready to Use Human Adipose Allograft: Characteristics and Biocompatibility

Christopher Khorsandi, Victor Fanniel, Ihab Atawneh, Acarizia Easley, Jonathan Savoie, Michelle Izaguirre-Ramirez, Joanna Marquez, Shauna Hill

RegenTX Labs, BioCreations LLC, VIP Plastic Surgery

Introduction: This study introduces alloClae, a novel adipose tissue allograft optimized for soft tissue reconstruction to address the challenge of substantial soft tissue losses due to surgical resections or contour deformities. Current methods like autologous fat transplantation have limitations, including donor site morbidity and insufficient tissue availability, necessitating an innovative approach.

Method: alloClae is prepared using a detergent-based protocol that efficiently processes large volumes of adipose tissue, focused on minimizing DNA content to reduce potential immunogenicity while preserving essential extracellular matrix (ECM) components and adipocyte structure. We conducted characterization studies, histological and proteomic analyses, and in vitro and in vivo evaluations. In vitro tests assessed alloClae's biocompatibility and its efficacy in supporting adipose-derived stem cells (ASCs) attachment and differentiation to mature adipocytes. The in vivo analysis involved a 6-month longitudinal study in athymic rats to assess tissue integration and transplant stability.

Results: alloClae maintained the structural integrity of adipocyte honeycomb structures and critical ECM proteins, essential for supporting cellular functions in tissue reconstruction. In vitro results indicated effective ASC proliferation and differentiation to mature adipocytes. In vivo assessments demonstrated alloClae's biocompatibility, with early vascularization and successful graft integration, highlighting its potential for promoting adipogenesis and angiogenesis.

Discussion: The findings underscore alloClae's potential as an effective solution for soft tissue reconstruction. By preserving structural integrity and ensuring compatibility, alloClae overcomes key limitations of existing graft materials. This study highlights alloClae's potential for practical applications in tissue reconstruction, making it a promising option for restoring form after significant tissue loss.

Oral Presentation | Free paper (Aesthetic surgical procedures)

A03

How to treat the ipsilateral sunken chest in augmentation mammoplasty

Jinho Lee

AB Plastic Surgery Clinic, Seoul, Korea

Background: Breast asymmetry is a common concern for many women and augmentation mammoplasty is a useful option. One important thing in fixing uneven breast is the consideration of underlying chest wall contour. Anterior thoracic hypoplasia (ATH) refers to ipsilateral sunken chest with breast hypoplasia and subsequent asymmetry. Since there is no pectoralis muscle involvement, it is speculated as a separate entity from Poland syndrome by Spear. It is also different from pectus excavatum in its chest wall shape. ATH is not a rare condition and various degree of ATH patients undergo augmentation mammoplasty.

Objective: The purpose of this presentation is to share clinical experiences and set-up some guidelines.

Methods: A retrospective chart review of patients between 2020 and 2024 was performed.

Results: Twelve patients underwent augmentation mammoplasty with correction of breast asymmetry, which condition assessed as ATH. In all cases, ATH occurred in the right side of the chest. Dual-plane breast augmentation technique using smooth round implant was performed in all cases. One patient developed postoperative implant malposition and had revisional mammoplasty with implant exchange, capsulotomy and capsulorrhaphy. The remaining 11 patients had favorable outcomes with smooth recovery.

Conclusion: Considering my unfavorable case, the author recommend to practice as follows: 1) to analyze the chest CT preoperatively 2) to consider microtexture implant rather than pure smooth implant 3) Extremely conservative medial dissection of Rt. Breast with at least 2.5cm safety margin from the midline 4) postoperative surgical bra up to 6 months 5) to consider wider diameter implant on Rt. Breast for lateral breast balancing.

Oral Presentation | TAAT APRAS award session 2

A04

**Challenges in primary rhinoplasty with autologous dorsal grafts:
Comparison of homogenous grafts and hybrid autologous grafts**

Jinho Lee

AB Plastic Surgery Clinic, Seoul, Korea

Background: Dorsal augmentation is important in Asian rhinoplasty. Apart from secondary cases, silicone implant is most preferred option in Asian rhinoplasty. It is generally regarded as superior to dorsal autologous grafts in aspects of aesthetic results such as longevity of dorsal height and lateral profile. Convenience in shaping and high predictability are definite advantages.

However, in certain indications, autologous materials are literally enough to make balanced and aesthetically-pleasing nose. Patient perspective has changed that increasing numbers are seeking for autologous costal cartilage in primary cases recently. Via the incision for costal cartilage, soft tissues including fascia, dermis, fat, perichondrium can be harvested and used simultaneously. With more autologous graft sources, hybrid dorsal augmentation is globally tried these days.

Objective: Gains in safety and psychologic well-being after using solely autologous grafts are obvious. This study aimed to access the effect of heterogeneity in autologous dorsal grafts, focusing on minimizing the drawbacks.

Methods: Retrospective chart review of patients underwent primary rhinoplasty with autologous tissues between Jun 2019 and Apr 2024 was performed. Overall outcomes including revision rates were analyzed.

Results: 298 patients presenting to a single surgeon were analyzed. (Table 1) With homogenous autologous grafts, 25 out of 178 patients underwent revision. (14.0%) With hybrid autologous grafts, 11 out of 120 patients underwent revision. (9.2%), showing lower than the former.

Conclusion: Surgical indication is a crucial step and it's necessary to align the expectations of patients with doctor's preoperatively. Recruiting proper graft sources are required for the aesthetic balance between hard and soft tissue and minimizing complications.

Oral Presentation | TAAT Best paper session

A06

Plasma Radiofrequency-assisted Microliposuction for the Treatment of Facial Overfilled Syndrome Induced by Various Causes in Asians

MING NI

Jiangshu SIRRIM Plastic Surgery and Beauty Hospital

Background: In Asia, facial overfilled syndrome (FOS) can arise from iatrogenic causes involving excessive use of filling materials , as well as physiological causes such as fat hypertrophy, cavity type, and aging.

Objective: This study aimed to demonstrate the safety and effectiveness of Plasma Radiofrequency-assisted Microliposuction (PRFAML) in improving the appearance of FOS induced by various causes.

Methods: PRFAML was performed on 84 anatomic regions of 37 female patients (including 12 with physiological causes, 6 with HA causes, and 19 with fat causes) , aged between 20 to 50 years (mean 35.9 years), who had FOS. Demographic and surgical data were collected retrospectively. Preoperative and postoperative photographs were taken, and satisfaction interviews were conducted at least six months after surgery.

Results: All patients underwent the operation successfully under local or intravenous anesthesia. Only four anatomic regions showed noticeable asymmetry post-surgery requiring a secondary operation. Postoperative skin numbness, muscle paralysis, bruising, and minor contouring irregularities significantly improved within two to three weeks of recovery. Additionally, five patients with longer edema periods demonstrated substantial improvement after more than five weeks. No cases of skin necrosis ,thermal injury or other serious complications related to the study device or procedure were reported. Ultimately, all patients expressed satisfaction with their outcomes.

Conclusion: The PRFAML technique is a safe and effective method for treating FOS induced by various causes while minimizing complications and ensuring high patient satisfaction.

Oral Presentation | Free paper (Aesthetic surgical procedures)

A07

Abdominoplasty in the Low BMI Asian Patients

XIN CUI

Xi'an International Medical Center Hospital

Background: Patients with low body mass index (BMI) are always accompanied with thin abdominal subcutaneous fat and flat or protrude umbilical stem.

Objective: The purpose of this study is twofold: Expanding the dissection range of the skin flap to enhance its plasticity and mobility, meanwhile creating a new umbilicoplasty to get a deep esthetically shaped navel.

Methods: 168 patients ($16.66\text{kg/m}^2 \leq \text{BMI} \leq 20\text{kg/m}^2$) were performed abdominoplasty.

Liposuction is performed, especially on bilateral waist and the upper lateral region of the buttocks. The level of flap dissection extends to the external borders of the bilateral rectus abdominis muscles. "8" approach and corium fat junction suture (CFJ) was performed in umbilicoplasty after repairing the diastasis recti. Finally, modified fully buried progressive tension reduction suture was performed on the wound.

Results: The average excised skin size of 168 patients was $30.88 \pm 7.82\text{cm} \times 27.59 \pm 6.39\text{cm}$.

Complications occurred in 19 patients: One case of local skin flap infection, two umbilical skin necrosis, three cases of wound healing problem, six cases of unilateral or bilateral dog ear formation, three hypertrophic scars, four cases of small seroma and one case of subcutaneous hematoma. There were no severe complications, such as deep-vein thrombosis, fat embolism, skin flap necrosis, large hematoma or seroma.

Conclusion: Abdominoplasty based on personal improvements is more suitable for low BMI Asian patients which can retain intense abdomen, smooth waist-hip curveline and deep vertical navel with fewer complications.

Oral Presentation | Free paper (Aesthetic surgical procedures)

A08

Exploration of Visual Sculpture-Abdominal Sculpture of Chinese People

CHAO XIE

Hunan Prevention and Treatment Institute for Occupational Diseases

Background: More and more abdominal liposculpture surgeries are being performed in China, and conventional liposculpture methods under blind vision for shaping the abdominal muscles may lead to unevenness, stiff abdominal muscles lines that do not conform to the contour of the human body's own muscles, excessive bleeding, and serum swelling, resulting in many secondary repairs operation. In order to avoid or exercise the above-mentioned problems, ultrasound guided visual liposculpture technology can be used to shape Chinese abdominal muscles.

Objective: To propose the concept of visualized liposculpture and explore the effect of applying ultrasound guided technology to shape the abdominal muscles.

Methods: Preoperative ultrasound measurement of abdominal fat thickness, marking of muscle boundaries in the abdominal liposuction area, ultrasound guided visualization of injection of swelling fluid, ultrasound assisted emulsification of fat, and dynamic assisted liposuction, clearly demonstrating the anatomical shape of the abdominal muscles.

Results: Ultrasound-guided visualization technique was used to perform abdominal liposculpture on 124 patients, and postoperative exposure of the abdominal muscle was satisfactory. No serious complications such as burns, skin necrosis occurred. And under ultrasound guidance, two postoperative complication of seroma was treated.

Conclusion: The application of ultrasound guided visual liposculpture is safer, more accurate, and has a higher satisfaction rate compared to traditional blind liposculpture applied to the shaping of abdominal muscles in Chinese.

Oral Presentation | Free paper (Aesthetic surgical procedures)

A09

Safe and Effective Injection for Treating Pouches

YANLING WEN

Dr.Cui Boshi Li Medical Aesthetic Clinic, Yinchuan

Background: The current treatment for eye bags is mainly surgical, with bruising, swelling and a recovery period. With the change in modern lifestyles, candidates prefer minimally or non-invasive treatment, and being able to wash their face and put on make-up in 6 hours is what candidates are looking for. In the past, it was widely believed that pouches under the eyes formed due to herniation of orbital fat and surgery was the treatment of choice. After literature tracing and cadaveric dissection, it was found that there is almost no ligamentous laxity in the deeper parts. The superficial dermal ligaments show significant laxity and sagging due to factors such as compression of facial expression and age, and the ligamentous laxity in the deeper parts originates from loss of bony structural volume. The simultaneous modification of tiny anatomical subunits and tightening of the skin through injections can be effective in treating under-eye bags as well as depressions and unevenness in the infraorbital region.

Objective: Exploring the clinical application of injections in the treatment of pouches.

Methods: All patients were treated with injections to address the bags under the eyes.

Results: The combined injection method of hyaluronic acid and nutrient solution was used to treat pouches in 1000 patients, with no complications except for severe local redness and swelling in two cases.

Conclusion: The injection method of treating pouches is a safe and ideal method of rejuvenating the infraorbital region.

A10

Treatment Strategies for Post-Facial Fat Grafting Deformities

LINA LIU

Shanghai Basilica Clinic

Background: Facial fat grafting solves issues like facial depressions and aging, but it can also introduce new complications such as various post-procedure deformities.

Objective: This study explores different treatment strategies for these post-facial fat grafting deformities.

Methods: Post-facial fat grafting deformities can be broadly categorized into four types: 1. Overfilled facial regions; 2. Irregularities and unevenness post-filling; 3. Increased sagging and slackness post-filling; 4. Deformities in specific areas post-filling. Treatment strategies are tailored to each deformity: 1. Overfilling is generally corrected by liposuction; 2. Unevenness is improved through liposuction and localized fat transplantation; 3. Sagging and slackness are addressed with a combination of suction and radiofrequency, or suction coupled with thread lifting; 4. Specific areas like the tear trough or chin overfilled are managed with suction combined with fiber laser lipolysis.

Results: Follow-ups from 3 to 12 months post-surgery showed that patients experiencing deformities post-filling observed varying degrees of improvement in facial contours through the aforementioned treatments, with high satisfaction rates regarding the outcomes.

Conclusion: Different surgical strategies tailored to specific post-facial fat grafting deformities can effectively improve outcomes.

A12

The Application of Light-Shadow Aesthetics in Cosmetic Injections

YINAN ZHOU

The Medical School of Guangzhou

Background: There are some limitations in the traditional methods of facial assessment when it comes to cosmetic injections. Therefore, light-shadow detection is an useful complement for facial aesthetic problems that cannot be found by traditional examination methods. Moreover, light-shadow aesthetics is a tool to simulate the aesthetic expression of patients under various light sources in their daily work and life. Through the evaluation of light and shadow in the process of face consultation, a better communication and consensus can be achieved with doctors and patients. The level of satisfaction was considerably high in either postoperatively or long-term follow-up in patients concern.

Objective: To explore the application of light-shadow aesthetics in cosmetic injections, especially in Asian facial rejuvenation and facial contour remodeling.

Methods: Multiple light sources were used to detect the facial defects of patients, which later were adjusted by cosmetic injections. After adjustment, the results were scored by GAIS scale.

Results: The application of light-shadow aesthetics in the cosmetic injection operation can comprehensively improve the satisfaction of all patients after operation, and no obvious complication was discovered.

Conclusion: The application of light-shadow aesthetics is an efficient method in cosmetic injections.

Keywords: light-shadow, injection, facial rejuvenation.

Oral Presentation | Free paper (Non-surgery)

A13

Application of Collagen Combined with Botulinum Toxin in the Treatment of Periorbital Aging

SHUAIHUA LI

Hunan Liyang Medical Cosmetic Hospital

Background: Periorbital aging in the face is a common problem in older women. Procedures using collagen or botulinum toxin has some benefits in the treatment of periorbital aging.

However, there are few reports on the combination of the two treatments.

Objective: To investigate the efficacy, safety and tolerability of the combination of collagen and botulinum toxin in the treatment of periorbital aging.

Methods: 21 patients with periorbital aging and relaxation were treated with collagen injection and botulinum toxin type A injection in a single-center, self-controlled before and after study method. The efficacy and safety of collagen combined with botulinum toxin in the treatment of periorbital aging were compared based on the Grading assessment of periorbital aging and detection results of VISIA.

Results: All patients were followed up for 1 month, 3 months and 6 months, the effect of filling and slightly lifting was achieved immediately after injection, and the effect of tightening and lifting was obviously achieved after 1 month, the effect maintained after 3 months, the effect weakened after 6 months.

Conclusion: The combination of collagen injection and botulinum toxin A injection is effective in treating the patients with periorbital aging and relaxation, without obvious swelling and bruising, which is worth popularizing.

Oral Presentation | TAAT APRAS award session 2

A14

Efficacy of early intervention using pulsed dye laser (PDL) for traumatic or postoperative scars improvement in Asian patients

Chang Cheng Chang¹, Han Yuan Chng²

¹ China medical university hospital

² Chang Gung memorial hospital

Background: Post-injury or -treatment is usually sought for symptom relief and alleviating cosmetic concerns. A pulsed dye laser (PDL, 585–595 nm) is commonly applied to such treatments alone or combined with ablative fractional CO₂ laser. However, laser initiation has no consensus.

Objective: This study was to evaluate the efficacy of early intervention using PDL for traumatic or postoperative scars improvement.

Methods: This retrospective study enrolled 70 patients in Asia with traumatic or post-operative scars who had received PDL treatment only or combination with an ablative fractional laser. The Vancouver scar scale (VSS) and the Manchester scar scale (MSS) were used before and after laser treatment with photo evaluation by two independent dermatologists. The patient and observer scar assessment scale and customer satisfaction index were collected.

Results: Among the 70 patients, 43 were successfully treated for at least 3 sessions with good outcomes. The correlation coefficients between week-to-treatment initiation and post-treatment MSS and VSS were 0.50 ($p < 0.001$) and 0.46 ($p = 0.002$), respectively. Using ≤ 10 weeks as the definition of early treatment, 22 and 21 patients were included in the early and late treatment groups, respectively. The early treatment group showed borderline significantly lower post-treatment MSS and VSS scores than the late treatment group (MSS: 7.5 ± 2.1 vs. 9.3 ± 2.5 , $p=0.011$; VSS: 2.8 ± 2.0 vs. 4.5 ± 2.3 , $p=0.011$). Furthermore, the early treatment group showed significantly greater improvement in both MSS and VSS post treatment (4.4 ± 1.6 vs. 3.2 ± 1.9 ; $p = 0.03$, and 3.8 ± 1.8 vs. 2.8 ± 1.4 ; $p=0.04$).

Conclusion: Early intervention using a PDL within 10 weeks of the injury achieved better outcomes in treating traumatic and postoperative scars based on both clinical and patient opinions.

A15

Factors Influencing Early Postoperative Swelling After Ptosis Surgery

Hiroko Ochiai¹, Aiko Oka¹, Shiho Watanabe¹, Mayuka Uchida¹, Rieko Shimizu²

¹ NHO Tokyo Medical Center, Department of Plastic and Reconstructive Surgery

² Keio University, Department of Plastic and Reconstructive Surgery

Background: Postoperative eyelid swelling is a primary concern for patients after ptosis surgery, significantly affecting their quality of life.

Objective: To identify the main factors influencing early postoperative swelling in patients undergoing bilateral ptosis surgery.

Methods: The study included 105 patients who underwent bilateral ptosis surgery between April 2020 and December 2022. Eyelid photos before surgery and on day 7 post-operation were analyzed by two non-operating plastic surgeons to evaluate swelling. Factors such as age, gender, underlying diseases, surgery duration, amount of skin removed, anterior displacement, intraoperative blood pressure, and antithrombotic medication intake were examined.

Results: The sample comprised 30 males and 75 females, with an average age of 72.9 years. Significant swelling was mainly influenced by extensive skin removal, followed by factors like diabetes and aging. Although antithrombotic medication was identified as a risk factor, its impact was not substantial. Factors like the amount of anterior displacement of the tendon and changes in marginal reflex distance (MRD) were not found to affect swelling.

Conclusion: Postoperative swelling is primarily exacerbated by increased vascular permeability due to inflammation, enhanced local blood flow, and microvascular damage, particularly in patients with extensive skin removal or underlying conditions like diabetes and arteriosclerosis. Cooling and compression were not effective in preventing swelling. Guidelines suggest continuing antithrombotic medication during superficial surgeries without needing to stop due to swelling risk. The relationship between the control of underlying diseases, postoperative management, and the extent of swelling requires further investigation.

Oral Presentation | TAAT Best paper session

A17

High Double Eyelid Fold Correction Composite Using Fat Strip Transplantation and Pretarsal Orbicularis Oculi Flap

Haihua Chen

Hangzhou First people's Hospital

Background: As the growing amount of unnatural-appearing upper eyelid after blepharoplasty, it's necessary to find suitable methods for secondary revision.

Objective: This study aimed to evaluate aesthetic outcomes of surgical correction of the high fold using a pretarsal orbicularis oculi flap with fat strip transplantation.

Methods: From January 2018 to September 2023, 50 patients with high and deep double eyelid folds underwent our fold-lowering procedure. All of these patients underwent surgical correction of high folds composite using fat strip transplantation and pretarsal orbicularis oculi flap, with postoperative follow-up ranging from 6 months to 2 years. All the Postoperative outcomes were recorded and reviewed.

Results: Using the composite technique, unnatural, high, and deep double eyelid folds were converted to lower and relative natural folds. Although prior high fold incision scars could be seen postoperatively on close examination, they were not easily visible. Complications included fold height asymmetry in 5 cases, persistence of the prior fold in 6 cases, and redundant upper flap skin that needed further excision in 3 cases.

Conclusion: Secondary blepharoplasty revision to correct the high fold is a challenging procedure for plastic surgeons. Using fat strip transplantation and pretarsal orbicularis oculi flap for correction of the high fold is relatively safe and effective. This provides a new treatment option in secondary revision techniques.

E-poster

A18

Global Interest in Glucagon-like Peptide-1 Agonists for Weight Loss and its Impact on Aesthetic Surgery

Austin Chen, Jorys Jorge-Martinez

Mayo Clinic, Rochester

Background: Glucagon-like peptide-1 (GLP-1) agonists Ozempic (Novo Nordisk, Bagsværd, Denmark), Wegovy (Novo Nordisk), and Mounjaro (Eli Lilly and Company, Indianapolis IN) have become popularized for weight loss in recent years.

Objective: The aim of this study is to assess with Google Trends (Alphabet Inc., Mountain View, CA) the popularity of these weight loss medications worldwide and its impact on public interest in related cosmetic weight loss procedures.

Methods: “Ozempic”, “Wegovy” and “Mounjaro”, along with terms for related aesthetic interventions such as “ozempic face”, “body lift” and “skin tightening” were analyzed with Google Trends across North America, South America, Europe, Asia and Africa, as represented by the most populated countries of each. Changes in relative search volume (RSV) over a 5-year period between the different medications and interventions were analyzed, across the different regions.

Results: There was a statistically significant RSV over time for GLP-1 searches worldwide, with R^2 0.902 and regression coefficient 0.938 ($p < 0.001$). This held true across all geographical locations. Ozempic was significantly more searched than Wegovy and Mounjaro ($p < 0.001$). In regards to weight loss related aesthetic or cosmetic procedures, there was not a statistically significant trend noticed in any across any of the geographic locations, apart from “ozempic face” with R^2 0.897 and regression coefficient 0.922 ($p < 0.001$).

Conclusion: The impact of ozempic is a global phenomenon, and plastic surgeons worldwide need to be prepared to address the subsequent effects. Although searches in weight loss related aesthetic interventions have not yet translated, there may be a time delay effect.

Oral Presentation | Free paper (Aesthetic surgical procedures)

A19

The Experience of Nasal Injection Therapy in 1981 Patients with Combination Materials about HA,PCL,CaHA and Thread

HSINKAI CHEN

Shanghai Gangli Beauty Medical Clinic

Background: Nasal aesthetics always is the commonest facial changes, and nasal plastic surgery is a way to solve the any problems.

Objective: However, due to the progress of biotechnology materials, many materials can be applied, such as HA, PCL, CaHA, collagen, thread, etc.

Methods: Among the combined formulas are HA, PCL, HA + PCL, HA + CaHA, HA + CaHA + thread, HA + PCL + thread. The results and complications are reported about the stratified injection of the combined application materials and the improved injection methods were shared.

Results: Summary of the injection experience of 1981 patients in 2022 to 2023. The common secondary injection problems will be reported and recommended injection methods.

Conclusion: Studies have proved that the combined therapy has less trauma and fewer complications, which is worthy of further clinical promotion and application.

Oral Presentation | TAAT Best paper session

A21

Improvement of visual acuity impairment in Poly-D,L-lactic acid injections by hyperbaric oxygen therapy

Tien-Chun Tsai, Chien-Liang Ho, Shin-Chen Pan

National Cheng Kung University Hospital

Background:

Poly-D,L-lactic acid (PDLLA) is a highly regarded dermal filler known for its biocompatibility, biodegradability, and enduring effects. Severe complications after PDLLA injections are rare.

Objective:

A healthy 38-year-old woman received PDLLA injection in the forehead experienced sudden right eye blurred vision and ptosis. Fluorescein angiography (FAG)/ indocyanine green angiography (ICGA), Optical Coherence Tomography (OCT) confirmed choroid ischemia and disc edema. Contrast brain MRI indicated ocular artery occlusion. MR angiography confirmed the diagnosis of posterior ciliary artery occlusion.

Methods:

Intraocular pressure lowering agents, aspirin, and a 14-session regimen of hyperbaric oxygen therapy (HBOT) was initiated within 24 hours.

A review of cases within 10 years involving visual impairment after facial filler injections treated with HBOT was done. Initial symptoms, injection site, initial visual acuity, treatments, best corrected visual acuity were compared.

Results:

At the two-month follow-up, the patient's ptosis and visual acuity improved from Snellen VA 0.03 to 0.9.

Among reviewed cases, treatments included intraocular pressure-lowering agents, globe massage, antithrombotic alongside HBOT. Only three cases showed improvement, with the best one achieving baseline vision after nine 90-minute daily HBOT sessions.

Conclusion:

Our case emphasized the possible severe adverse effect of PDLLA injection, highlights variable effectiveness of HBOT, and underscores its potential in restoring visual acuity post-PDLLA injection, offering important insights into managing such complications.

Oral Presentation | Free paper (Non-surgery)

A22

Efficacy of 730nm Picosecond Laser on Acquired Dermal Melanocytosis in Asian Women

Kento Takaya^{1,2}

¹ Department of Plastic and Reconstructive Surgery, Keio University School of Medicine

² Etoile Regina Clinic

Background: Acquired dermal melanocytosis (ADM) is a pigmented lesion that occurs frequently in young to middle-aged women. It has been treated with Q-switch ruby laser and 1064 nm picosecond laser, but it is refractory and there is no certain consensus on treatment. We have introduced treatment with the more melanin-selective 730 nm wavelength.

Objective: To compare the efficacy of 730 nm and 1064 nm picosecond lasers.

Methods: Patients treated with picosecond laser (PicoWay, Cineron Candela) for ADM from April 2021 to May 2024 were studied: 730 nm (3 mm spot, 1.7-1.8 J/cm² or 2 mm spot, 2.5-3.25 J/cm²) and 1064 nm (3 mm spot, 3.1-4.0 J/cm²) picosecond laser spot irradiation. Two months after each treatment, patients were evaluated on a 4-point scale using a medical interview, gross findings, and skin analysis software (VISIA, Canfield Scientific). The results of the univariate and multivariate analysis of the factors involved in ADM treatment outcome were analyzed.

Results: 83 patients in the 730 nm group and 78 in the 1064 nm group were treated; after treatments, subjective symptoms, gross findings, and improvement on software analysis were all significantly higher in the 730 nm group, with no difference in the occurrence of pigmentation. The presence or absence of melasma was a factor related to treatment outcome.

Conclusion: The use of the 730 nm picosecond laser, which is highly melanin-selective and reaches relatively deep into the skin, suggests the possibility of effective treatment without increased complications compared to the conventional treatment.

Oral Presentation | Free paper (Non-surgery)

A23

A Cutting-Edge Strategy for Prevention the Severe Complications in Filler Injection and Fat Grafting

Ching-En Chen^{1,2}, TSAI-MING LIN^{1,2}

¹ Kaohsiung Medical University Hospital

² Charming Institute of Aesthetic and Regenerative Surgery

Background: The use of fillers and fat grafting has become increasingly popular in aesthetic and reconstructive surgery. However, these procedures carry risks of severe complications, including intra-vascular injection-induced skin necrosis, blindness, and cerebral vascular accidents. Advanced techniques, such as Micro-Autologous Fat Transplantation (MAFT), have been developed to enhance safety and outcomes.

Objective: To evaluate the effectiveness of MAFT and other advanced strategies in preventing severe complications associated with filler injection and fat grafting.

Methods: A comprehensive review of over 6000 cases using the MAFT technique for fat grafting was conducted. The techniques involved precise control of fat injection, systematic patient evaluation, and meticulous surgical planning. Follow-up evaluations were performed over an average period of three years to assess outcomes and identify any complications.

Results: The implementation of MAFT significantly reduced the incidence of severe complications, such as intra-vascular injection-induced skin necrosis, blindness, and cerebral vascular accidents. The precise control over fat parcel size and injection depth minimized the risk of unintended vascular injections, thereby preventing these catastrophic events. In the extensive series of over 6000 cases, there were no reports of these severe complications, underscoring the safety and efficacy of the technique. Patient satisfaction was high, with maintained results observed over the three-year follow-up period.

Conclusion: The MAFT technique, along with rigorous preoperative and intraoperative strategies, provides a robust approach to minimizing severe complications in filler injection and fat grafting. These advanced methods enhance patient safety, improve aesthetic outcomes, and offer a reliable solution for both aesthetic and reconstructive purposes. The absence of severe complications in over 6000 cases further highlights the safety of this technique. Future advancements in these techniques are anticipated to further refine safety protocols and clinical results.

Oral Presentation | TAAT Best paper session

A24

The Rejuvenating Effect of Fat Grafting: Fiction or Fact

I-Feng Sun¹, Wen-Hui Chen², Tsai-Ming Lin³

¹ Astrid Clinic, Kaohsiung, Taiwan

² Department of Dentistry, Eda hospital, Kaohsiung, Taiwan

³ Charming Institute of Aesthetic and Regenerative Medicine (CIARS), Kaohsiung, Taiwan

Background: Fat grafting has become a prominent technique in aesthetic and reconstructive surgery, particularly for its purported rejuvenating effects. This study aims to evaluate whether these claims hold up under scientific scrutiny by examining the biological mechanisms and clinical outcomes associated with fat grafting.

Objective: To investigate the efficacy of fat grafting in achieving rejuvenation, focusing on the biological basis and clinical evidence supporting its use in aesthetic medicine.

Methods: A review of clinical cases and scientific literature was conducted to assess the outcomes of fat grafting procedures. Emphasis was placed on the role of adipose-derived stem cells (ADSCs) and the stromal vascular fractions (SVFs) in tissue regeneration and rejuvenation. Data from over 6000+ cases of fat grafting procedures were analyzed, with follow-up periods extending up to ten more years.

Results: Fat grafting demonstrated significant rejuvenating effects, including improved skin texture, increased volume with sustainability, and enhanced tissue quality. The regenerative properties of adipose-derived stem cells (ADSCs) and the stromal vascular fractions (SVFs) were confirmed through histological analyses, showing increased collagen production and neovascularization. Patients reported high satisfaction rates, and long-term follow-ups indicated sustained improvements without major complications.

Conclusion: The rejuvenating effect of fat grafting is supported by both clinical outcomes and biological evidence. The integration of ADSCs and SVFs plays a crucial role in the observed benefits, making fat grafting a reliable method for aesthetic rejuvenation. Future research should focus on optimizing techniques to further enhance these effects and explore new applications in regenerative medicine.

Oral Presentation | TAAT APRAS award session 2

A27

Hair Regeneration Using Stem Cell-Conditioned Medium

JUN KARIIBE

Kojimachi Dermatology & Plastic Surgery Clinic

Background: Various treatments for hair thinning, such as papule methods, dermarollers, mesotherapy, and mesoguns, have been developed. However, these methods often cause pain and have inconsistent results. This study investigates a new hair treatment method using a needle-free injector to administer stem cell-conditioned medium.

Methods: We measured the hair diameter, hair density, and patient satisfaction of those treated at our clinic. Additionally, we analyzed changes in hair volume and growth patterns according to gender and age.

****Results:**** The needle-free injector treatment caused minimal pain and resulted in high patient satisfaction. It was found to be highly effective for androgenetic alopecia and also beneficial for female pattern hair loss. Typically, treatment for female pattern hair loss requires several months due to the hair follicle cycle and hair growth rate. However, the stem cell-conditioned medium significantly accelerated the growth phase of hair, resulting in early treatment effects.

Conclusion: The hair treatment using a needle-free injector is minimally invasive, can be easily standardized for nurse administration, and is convenient, making it suitable even for patients with needle phobia. Stem cell-derived growth factors are known to possess equal or superior tissue regenerative abilities compared to stem cell transplantation. This study suggests that the induced growth of hair in the anagen phase, increased proliferation of dermal papilla cells and keratinocytes, and enhanced hair follicle growth contributed to the positive outcomes. Hair treatment using stem cell-conditioned medium is considered to lead to increased hair growth, providing significant improvement for patients with frontal hair thinning and moderate to severe vertex alopecia.

A28

Optimizing scarless double chin treatment: Systematic plan through combining surgical, energy based, and manual techniques

Dina M Badawi

Cairo university

Background: The importance of a tightened sculptured neck and submental region is highlighted nowadays in the trending selfie photos. Surgical liposuction of submental fat may address one component of the double chin problem, other components like loose skin and sluggish lymphatic circulation need attention.

Objective: Evaluating the impact of applying manual lymphatic massage and radiofrequency energy to the submental area following surgical liposuction on aesthetic outcome, patient's satisfaction, and safety.

Methods: A prospective study included patients seeking scarless treatment for double chin deformity. Our plan involved three subsequent steps: PAL of submental fat, manual lymphatic massage, and radiofrequency energy. Follow up continued for 6 months. At each visit, photos were taken, complications were recorded, and visual analogue scales were used to evaluate the pain and patient satisfaction.

Results: 42 patients were included, mean age 38.1. Complications reported were edema, pain and transient marginal mandibular nerve paralysis. The pain scores were highest on the first visit. The mean satisfaction score on the final visit was 8.76 (Fig.1). None of the patients asked for further surgical neck lift.

Conclusion: Adding manual lymphatic massage and radiofrequency energy to the submental area in the early post-liposuction period may be considered a satisfactory, simple, reproducible, rapid, and safe plan for scarless neck rejuvenation.

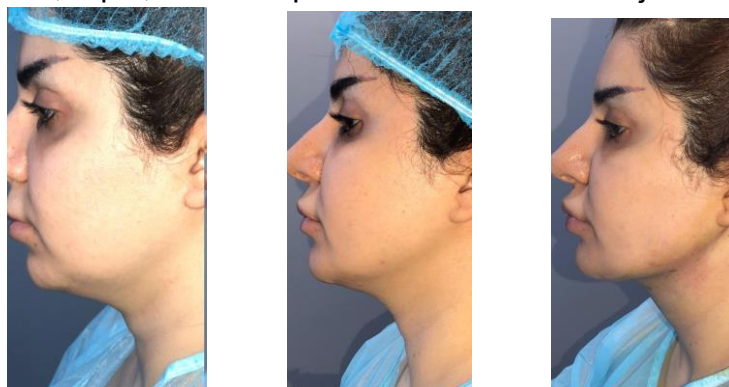


Fig. (1): A: Before liposuction of double chin. B: after performing PAL of submental fat. C: After completion of manual massage and radiofrequency

Oral Presentation | Free paper (Non-surgery)

A29

Peeling Back the Layers: A TikTok Analysis of Chemical Peel Content

Luis Antezana MD, Alexandre Meira Pazelli MD, Cole Holan MD, MBA, Basel Sharaf MD

Division of Plastic and Reconstructive Surgery, Mayo Clinic, Rochester, MN, 55902

Background

Chemical peels have seen a resurgence in popularity, with a fourfold increase in worldwide interest since 2010 based on Google Trends data.

Objective

This study analyzed chemical peel content on TikTok to investigate potential disparities in Fitzpatrick skin types represented, user engagement levels, and information dissemination.

Methods

The top 15 videos were reviewed for 13 popular chemical peel hashtags on TikTok, excluding non-English, unrelated, and duplicate videos. Data extracted included engagement metrics, chemical agents used, content types, and patient experiences. Appropriate statistical tests were conducted.

Results

195 videos were included, totaling nearly 199 million views and over 8 million likes. Full face (91.1%) was the most common treatment area. Phenol (17.4%), salicylic acid (11.3%), and TCA peels (11.3%) were most prevalent. Top treatment indications were pigmentation (24.7%) and acne scars (14.9%).

Patient experiences (35.6%), education (23.7%), and live peeling (23.2%) were the main content types. Less than one-third (31.6%) were by healthcare providers. Among providers, most were MDs (49), followed by DOs (5).

Patient experiences were largely positive (57.8%). The MD+DO subgroup had significantly higher engagement metrics than patients. Fitzpatrick scores >3 vs. <3 differed significantly for phenol peel content, with the <3 group more represented.

Conclusion

This overview of TikTok's chemical peel content reveals potential patient exposure and racial disparities within cosmetic treatment marketing.

Oral Presentation | Free paper (Non-surgery)

A31

An injection method that uses “HA” to improve perioral aging.

Zhao Hui Hui

Shenzhen Yixing Cosmetic Hospital

Background: Traditional anti-aging focuses only on aging around the eyes and sagging of the face, while problems around the mouth are gradually discovered after the eye area.

Objective: To improve the smoothness of the perioral flatness, intramucosal combined subcutaneous injection can be used to minimize pain.

Methods: Through the adjustment of the lip, mandibular angle, jaw line, “ogeen” line, piriform fossa “DMCF” and other structures. “MOV” injection partitions are proposed to track the effect of injections.

Results: According to the specific situation (“MOV” partition adjustment) analysis to adjust different schemes, the results showed that most patients had smooth perioral flatness and better coordination and natural coordination of skin and flesh during orotic orbuli muscle movement after one month after surgery, and had a high level of satisfaction.

Conclusion: Effectively improve the flatness of the perioral mouth, improve the perioral aging, and achieve effective dynamic anti-aging effect.

Keywords: Peroral aging, MOV, HA, Intramucosal injection

Oral Presentation | Free paper (Non-surgery)

A32

An improved injection method for non-painful abobotulinumtoxin A to lift the entire face

Xiang Wang

Hangzhou-Mylike Cosmetic Hospital

Background: In the past, traditional AbobotulinumtoxinA(AboBoNT-A) injection methods for facial lifting, which were used to inject the platysma, failed to achieve the desired lifting effect. Patients experienced significant pain, and the treatment outcomes were unsatisfactory, resulting in low satisfaction rates.

Objective: To achieve rapid and long-lasting facial lifting and clear jawline effects by improving the injection points, concentrations, and injection levels of AboBoNT-A, while reducing patient's pain during the injection process.

Methods: Through dynamic and static assessments, AboBoNT-A was injected into the platysma and other descending muscles, while preserving the lifting muscles. By enhancing the lifting force of the galea aponeurotica and relaxing the tension of the platysma, the facial soft tissues were lifted. The AboBoNT-A (produced by Galderma, 300su, diluted with 3ml of normal saline, with 5su injected at each point) was used, and the treatment outcomes were evaluated one month later.

Results: Most patients achieved good lifting effects, manifesting as a clear jawline, smoother facial contours, lifting of the soft tissues in the mid-to-lower face, reduced fatigue, and changes in face shape. Additionally, 80% of patients experienced a more comfortable injection process and had a high level of satisfaction.

Conclusion: The application of modified painless AboBoNT-A injection techniques for comprehensive facial lifting can achieve better facial lifting effects and reduced pain, significantly improving patient satisfaction.

Keywords: face lifting,Botulinum Toxin,AbobotulinumtoxinA,Non-Painful injection

Oral Presentation | TAAT APRAS award session 2

A33

Preliminary Outcome of Enhancing Transdermal Delivery of Autofluorescence Nanoparticles Assisted of Picosecond Laser and Fractional CO₂ Laser

Chang-Cheng Chang^{1,2,3}, Tzong-Yuan Juang², YU-CHUAN YANG³

¹ Division of plastic and reconstructive surgery, China Medical University Hospital, Taiwan

² Department of Cosmeceutics, China Medical University, Taiwan

³ Department of Medicine, China Medical University, Taiwan

Background: Picosecond laser could produce laser-induced optical breakdown, which might enhance transdermal drug delivery. Fractional CO₂ laser could induce vertically ablated channels that could also help transdermal drug delivery. In addition, we use a kind of self-assembled fucoidan nanoparticle that have autofluorescence to observe the effect of transdermal drug delivery.

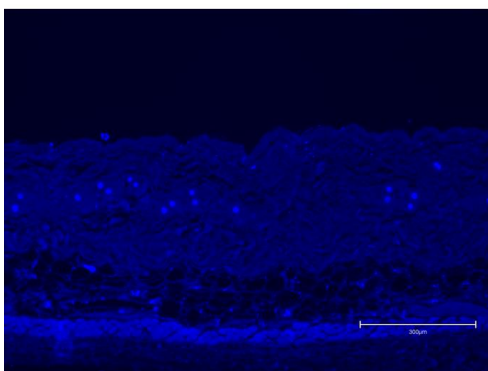
Objective: We want to investigate whether picosecond laser-induced cavitation can serve as a drug reservoir to help nanoparticles remain in the dermis for a longer period. At the same time, we want to know if the nanoparticles can diffuse from the channels induced by CO₂ fractional laser into the surrounding tissues rather than remaining within the channels.

Methods: C57BL/6 were divided into three groups: a picosecond laser group, a CO₂ laser group, and a control group. Each group was treated with nanoparticles self-assembled by dendrimer (PD-ET-12) and fucoidan.

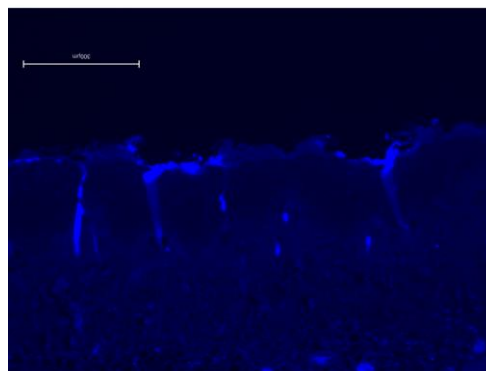
Results: At 0.5 hours, large fluorescent spots can be observed, which could reduce the number of nanoparticles remaining outside the dermis, minimizes drug wastage, and enhance drug delivery efficiency. At 2.0 hours, the fluorescent spots appear smaller but more numerous. At 2.0 hours, a clear contrast can be observed, with the coagulation zones appearing darker and the deeper layers exhibiting more fluorescence.

Conclusion: LIOB could serve as a drug reservoir to help nanoparticles remain in the dermis. Analysis of the fluorescence in tissue sections indicates that nanoparticles can penetrate deeper into the skin when assisted by CO₂ laser treatment.

picosecond laser group at 2.0 hours



CO₂ laser group at 2.0 hours



Oral Presentation | Free paper (Aesthetic surgical procedures)

A34

A treatment plan for orbital aging

Yu Hua

Guangzhou YuhuaMedical Beauty Clinic

Background: Exploration of treatment plans for Asian individuals with congenital flat brow arches, acceptable tightness of the forehead, and sagging upper eyelid skin.

Objective: A treatment method of double eyelid incision eyelid shaping and eyebrow arch filling for orbital aging.

Methods : From January 2022 to January 2024, 105 female patients underwent double eyelid incision eyelid shaping and eyebrow arch filling surgery, including improvement of ptosis of the eyelid tail, eyebrow, eyelid, and zygomatic curves.

Results : 105 patients recovered to normal 4-6 months after surgery, with concealed incisions and significant improvement in orbital aging.

Conclusion : Through double eyelid incision eyelid shaping and eyebrow arch filling surgery, ① reducing surgical incisions, concealing scars, and effectively reducing muscle integrity damage. ② Effectively improve skin laxity around the orbit and increase bone volume around the orbit. It is a safe and effective method of annual orbital rejuvenation treatment.

Oral Presentation | Free paper (Non-surgery)

A35

Bioactive glass in clinical applications

Qian Li, Mei shang

No. 111, Hengda Huafu, Wuling District, Changde City, Hunan Province, China 418000

Objective: Explore the clinical application of regenerative materials
(bioactive glass)

Methods: All patients were treated with bioactive glass and hyaluronic acid
mixture

Results: Using a bioactive glass mixture for treatment in 1500 cases, no
other complications occurred except in 8 cases due to insufficient dose

Conclusion: Bioactive glass is a safe and ideal bony filler

Oral Presentation | Free paper (Fat for the breast 1)

R01

The stability of the inframammary fold formed by loop suture during breast augmentation/reconstruction with fat grafting

Viacheslav Vasilyev¹, Sergey Vasilyev^{1,2}, Igor Vasilyev^{1,2}, Yuri Vasilyev^{1,2}, Malika Gurba¹

¹ Institute of Plastic Surgery and Cosmetology

² South Ural State Medical University

Background: Implementation of the loops described by R. Khoury into clinical routine have helped a lot to control the shape and symmetry during aesthetic and reconstructive breast augmentation with fat grafting. However, there are a number of complications that go along with this method. Inframammary fold (IMF) instability is one the most common adverse effects that we observed while using such technique.

Objective: To evaluate factors that influence the stability of the inframammary fold formed by loop suture.

Methods: Since 2016 sixty-seven patients underwent IMF reconstruction with loops during breast augmentation with fat grafting (53 reconstructive and 14 aesthetic cases). The thread (Capron or PDS) was set up from the puncture at subclavian region along the breast contour according to the technique described by R. Khoury. Internal tissue expansion was applied in 19 cases reconstructive cases prior to IMF reconstruction. Results were evaluated with standard anthropometric measurements and photography at 1, 3, 6 and 12 months postoperatively.

Results: Caudal IMF displacement was observed in 12 patients (18%) and was associated with limited soft tissue mobility. In 10 cases such complication was registered in patients without internal preexpansion. Thread rupture was observed in one case while PDS is used.

Conclusion: Limited abdominal skin mobility is the most important factor that affects the stability of IMF formed with loop suture and fat grafting. In such cases internal tissue preexpansion should be performed in order to achieve sufficient skin surface area.

Oral Presentation | Sydney Coleman award session

R02

Management of radiation injury of the rectum with adipose-derived biomaterials injection. 10-year experience.

Zhanna Teriushkova¹, Viacheslav Vasilyev², Igor Vasilyev^{1,2}, Sergey Vasilyev^{1,2}, Malika Gurba²

¹ South Ural State Medical University

² Institute of Plastic Surgery and Cosmetology

Background: The use of fat grafting and adipose-derived stromal vascular fraction injections have changed the paradigm of radiation-induced soft tissue damage management and radiation rectum injury in particular. Although initial clinical experience in this field showed encouraging results, evaluation of long-term outcomes is gaining relevance.

Objective: To analyze long-term outcomes of rectum radiation injury treatment with autologous fat and stromal vascular fraction (SVF) injections.

Methods: Since 2012 fat grafting in combination with SVF injections was used in 111 patients with rectum radiation injury: rectovaginal fistula (n=59; 53,2%), rectum ulcers (38; 34,2%) and proctitis (14; 12,6%). To achieve complete healing from 1 to 6 repeated procedures per patient were performed (362 surgeries in total). To assess outcomes physical examination, photography, ultrasound, MRI and histology were used.

Results: Complete healing was achieved in 109 cases (98,2%). The lack of effect was observed in two patients with rectovaginal fistula (1,8%) who had concomitant autoimmune disease. Fistula relapse was observed in four (6,8%) out of 59 patients and has been solved with additional procedures. Rectal stricture after healing of large fistula has developed in three (5,1%) out of 59 cases. Two (1,8%) fatal complications not directly connected to the researched method have been registered: cancer relapse in one case (0,9%) and insolvency of intestinal anastomosis after reverse colostomy procedure in the other case (0,9%).

Conclusion: Autologous fat and stromal-vascular fraction injection is relatively safe and highly effective method for treatment of radiation injury of the rectum.

R03

Targeting SIRT4/TET2 Signaling Alleviates Human Keratinocyte Senescence by Reducing 5-hmC Loss

Yukun Liu¹, Yi Yi¹, Yuchang Wang², Yiping Wu¹¹ Department of Plastic and Cosmetic Surgery, Tongji Hospital, Tongji Medical College, Huazhong University of Science and Technology, Hubei, China² Trauma Center/Department of Emergency and Traumatic Surgery, Tongji Hospital of Tongji Medical College, Huazhong University of Science and Technology, Wuhan, China

Abstract

Skin aging is characterized by wrinkle formation and increased frailty and laxity, leading to the risk of age-related skin diseases. Keratinocyte is an important component of the epidermis in skin structure, and keratinocyte senescence has been identified as a pivotal factor in skin aging development. Because epigenetic pathways play a vital role in the regulation of skin aging, we evaluated human skin samples for DNA hydroxymethylation (5-hydroxymethylcytosine; 5-hmC) and SIRT4 expressions. Results found that both 5-hmC and SIRT4 showed a significant decrease in aged human skin samples. To test the results in vitro, human keratinocytes were cultured in H₂O₂, which modulates skin aging in vivo. However, H₂O₂-induced keratinocytes showed senescence-associated protein expression and significant downregulation of 5-hmC and SIRT4 expressions. Moreover, 5-hmC-converting enzymes ten-eleven translocation 2 (TET2) showed a decrease and enhanced TET2 acetylation level in H₂O₂-induced keratinocytes. However, the overexpression of SIRT4 in keratinocytes alleviates the senescence phenotype, such as senescence-associated protein expression, decreases the TET2 acetylation, but increases TET2 and 5-hmC expressions. Our results provide a novel relevant mechanism whereby the epigenetic regulation of keratinocytes in skin aging may be correlated with SIRT4 expression and TET2 acetylation in 5-hmC alteration. Our study may provide a potential strategy for anti-skin aging, which targets the SIRT4/TET2 axis involving epigenetic modification in keratinocyte senescence.

Figure 1

Figure 1. Aged human skin keratinocyte show loss of 5-hmC

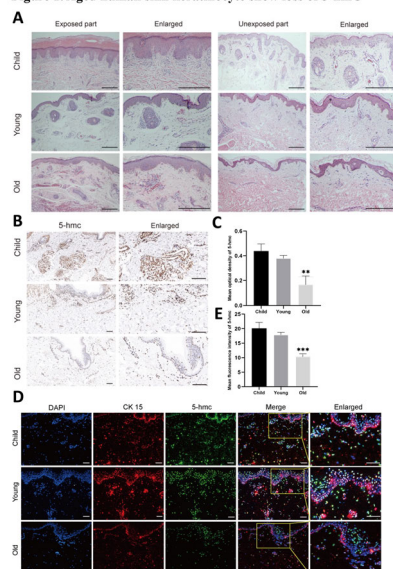


Figure 2

Figure 2. Aged human skin keratinocyte show loss of SIRT4

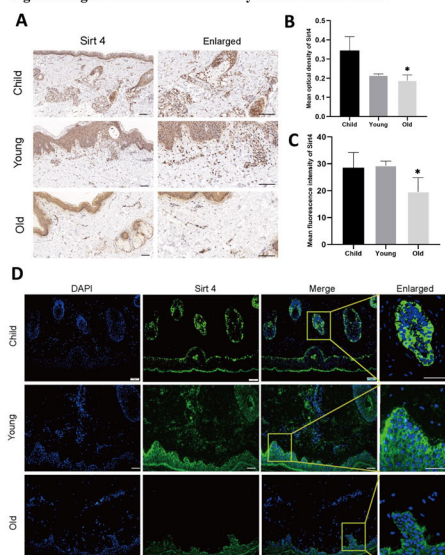


Figure 3

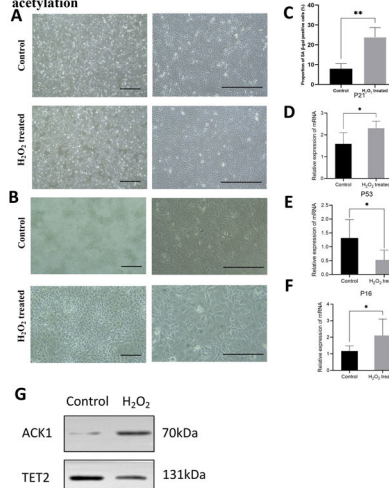
Figure 3. Effect of H₂O₂ on keratinocyte senescence and TET2 acetylation

Figure 4

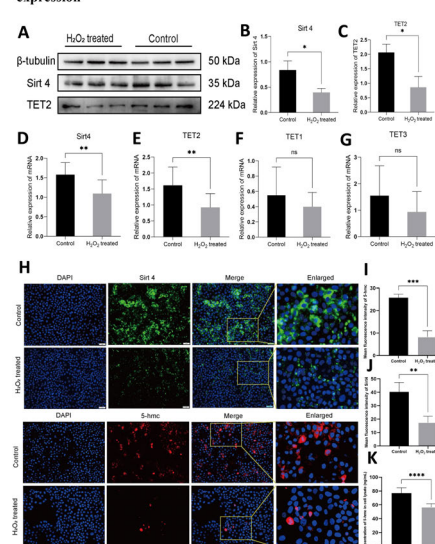
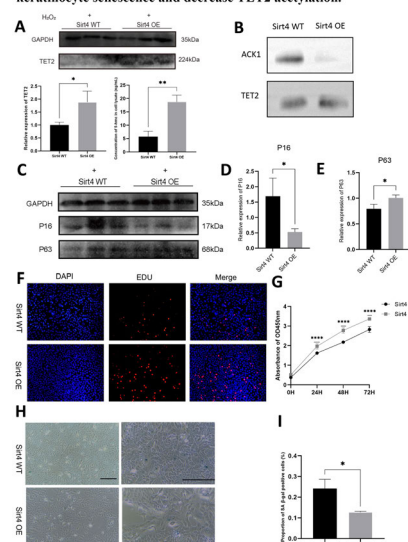
Figure 4. H₂O₂ alter keratinocyte TET2, 5-hmC and SIRT4 expression

Figure 5

Figure 5. Overexpression of SIRT4 alleviate H₂O₂ induced keratinocyte senescence and decrease TET2 acetylation.

Oral Presentation | Free paper (Stem cells/ Tissue engineering)

R04**Examining Long-Term Responses of Diverse Human Body Systems and Disorders to Mechanically Obtained Fat-Derived Stromal Cells**

Hasim Eray Copcu

G-CAT (Gene, Cell and Tissue) Academy

Background:

Adipose tissue is an excellent source of stromal cells, which play a crucial role in regenerative therapies.

Objective:

Mechanical methods, particularly those involving ultra-sharp blade systems, have shown exceptional success in efficiently obtaining stromal cells from adipose tissue. However, the response of different body systems and organs to regenerative applications can vary significantly.

Methods:

Regenerative treatments were administered in 668 cases across various indications, and their long-term outcomes were assessed over a minimum of 2 years and a maximum of 8 years. After centrifugation and removal of blood and tumescent fluid, the resulting condensed fat was sectioned using ultra-sharp blades with diameters of from 2400 to 120 microns to separate stromal cells. The isolated stromal cells were then applied according to specific protocols for each indication.

Results:

Regenerative treatments utilizing stromal cells were successfully employed for both aesthetic and therapeutic purposes in various anatomical regions, including skin and subcutaneous tissues (aging, burns, cancer, radiation injury, diabetic foot), urogenital region (erectile dysfunction, Peyronie's disease, ovarian insufficiency, endometrial and testicular rejuvenation, bladder reconstruction, urinary incontinence), scalp, vocal cord, bone tissue (aseptic necrosis), joints (osteoarthritis), adipose tissue (lipodystrophy, necrosis), plantar fascia, and lung (regenerative rehabilitation).

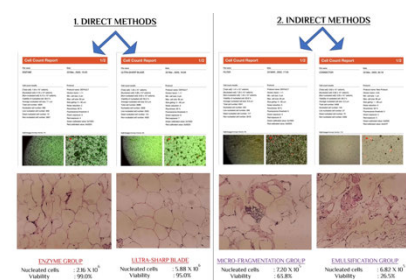
Conclusion:

The acquisition of stromal cells from adipose tissue can be categorized into two approaches: direct and indirect methods targeting the connections between parenchymal and stromal-cells. Among these approaches, ultra-sharp blade systems have demonstrated the most successful outcomes.

Figure 1: Ultra-sharp blades



Figure 2: Comparison of techniques



R05

Activated Fat Grafting: A Novel Approach for Enhanced Fat Graft Retention and Natural Long-Term Results

Hasim Eray Copcu

G-CAT (Gene, Cell and Tissue) Academy

Background:

Fat grafting is a commonly performed procedure in plastic surgery with a long history of application. Despite numerous studies on the pathophysiology of fat grafting, many aspects remain unclear. The survival of fat grafts is influenced significantly by the presence of stromal-cells.

Objective:

This study introduces a novel technique called “activated fat grafting”, which involves releasing stromal cells using ultra-sharp blades without damaging the fat tissue parenchyma, followed by the application of fat grafting.

Methods:

Different sizes of fat grafts (2400 - 100 microns) were prepared using ultra-sharp blades specific to each anatomical area and depth. The process involved releasing stromal cells within the adipose tissue. A total of 248 patients underwent fat grafting on various body areas, including the face, breast, extremities, genital areas, and others.

Results:

Laboratory studies demonstrated that the use of sharp blades allowed the desired diameter of adipose tissue to be achieved without completely disrupting the parenchyma, while also releasing stromal cells and determining their presence and quantity. Clinicians and patients reported satisfactory long-term results in all cases.

Conclusion:

Adipose tissue contains parenchymal cells, predominantly adipocytes, interconnected with stromal cells through bonds and bridges. By separating these bonds using sharp blades, the stromal cells can be released without compromising the viability of adipocytes. This technique facilitates the attainment of natural, long-term results while minimizing complications such as graft visibility.

Figure 1: Protocol

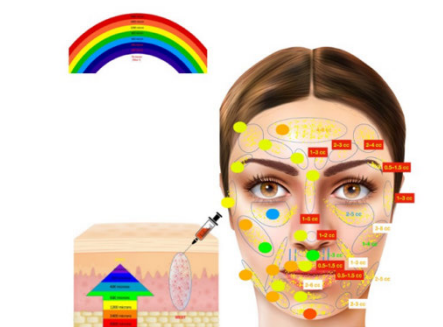
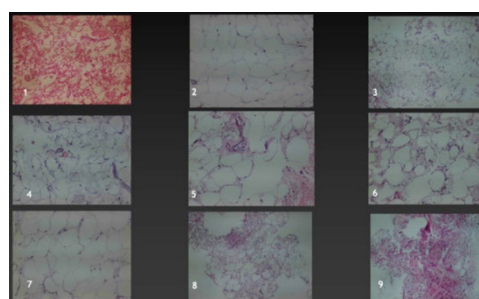


Figure 2: Histopathological analysis



Oral Presentation | Sydney Coleman award session

R06**Autologization of Exosome Therapies using De-Parenchymized Adipose Tissue Extracellular Matrix: A Novel Approach for Controlled Regenerative Medicine**

Hasim Eray Copcu

G-CAT (Gene, Cell and Tissue) Academy

Background:

Exosome products from allogeneic and xenogeneic sources are available on the market. A key challenge is controlling the effects of non-autologous exosomes.

Objective:

We hypothesized that combining exosomes with a patient's own extracellular matrix (ECM) can create "autologization," enabling better control over their effects. This study aimed to provide the rationale and a guide for future research exploring the autologization of exosome applications using de-parenchymized adipose tissue (DPAT).

Methods:

DPAT adipose tissue was achieved using 1200-, 400-, and 35-micron blades in an ultra-sharp blade system (Adinizer), and then "autologization" was achieved by combining the obtained DPAT with allogeneic exosomes. DPAT was evaluated histochemically, and exosomes were counted and analyzed with the Nanosight device.

Results:

The DPAT process using ultra-sharp blades is easily performed. DPAT obtained from adipose tissue was then combined with allogenic exosomes. It has been demonstrated histopathologically that adipocytes are eliminated in de-parenchymized fat tissue, and only ECM and stromal cells remain. It has also been proven that the number of exosomes is not affected by the combination.

Conclusion:

This study introduces two novel concepts previously unknown in the literature, "de-parenchymization" and "autologization," representing an innovative approach in plastic surgery and regenerative medicine. Our novel approach enriches regenerative cells while preserving critical ECM signals, overcoming the limitations of existing isolation methods. Extensive research is still needed, but autologization using DPAT-ECM holds great promise for translating exosome-based treatments into clinical practice.

Figure 1:DPAT analysis

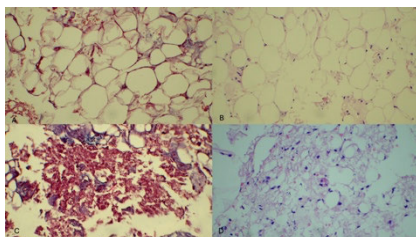



Figure 2: Exosome analysis



Oral Presentation | Free paper (Research)

R07

Mechanical stretch promotes hypertrophic scar formation by stimulating Schwann cells cholesterol biosynthesis

Jiahao He, Shengzhou Shan, Bin Fang

Department of Plastic and Reconstructive Surgery Shanghai Ninth People's Hospital Shanghai Jiao Tong University School of Medicine

Background: Hypertrophic scar (HS) is a fibroproliferative skin disorder which could lead to severe functional impairment. Mechanical stretch has been identified as a critical regulator of HS formation, but the underlying mechanism is not fully understood. Recently, activated Schwann cells (SCs) have been shown to be involved in wound healing and keloid formation. However, it is unknown whether SCs respond to mechanical stretch, leading to activation and ultimately HS formation.

Objective: We aim to investigate the influence of mechanical stretch on SCs activation and subsequent HS formation to explore a potential anti-HS formation therapy.

Methods: Human HS tissues and adjacent normal skin tissues were collected to detect activated SCs by immunofluorescence co-staining of SCs marker (SOX10) and SCs activated markers (p75, c-JUN and p-ERK). Cyclic mechanical stretch (10%, 24 hours, 0.5 Hz) was applied to SCs to mimic mechanical stretch during HS formation. Western blot was performed to assess the expression of p75, c-JUN and p-ERK. RNA sequencing was performed to characterize the molecular mechanism involved in stretch-induced activation of SCs. Selective inhibitors and conditional RNAi transfection were used to confirm the molecular mechanism of mechanical stretch in SCs activation. A stretch-induced rat tail hypertrophic scar model was established and then treated with selective inhibitors and conditional RNAi transfection to investigate the role of SCs in HS formation. Scar hypertrophy was assessed by H&E and trichrome staining. α -SMA expression was confirmed by immunohistochemistry.

Results: First, immunofluorescence confirmed that there is an increasing number of activated SCs distributed in HS samples. Mechanical stretch could promote the activation of SCs *in vitro*, as assessed by upregulation of p75, c-JUN and p-ERK. In mechanism, RNA sequencing analysis revealed a strong enrichment for genes involved in cholesterol biosynthetic processes in stretch-treated SCs. Importantly, the expression of 3-hydroxy-3-methylglutaryl coenzyme A reductase (HMGCR), a key enzyme in cholesterol biosynthesis, was upregulated in stretch-treated SCs. Application of simvastatin (an HMGCR inhibitor; 1 μ M) and HMGCR-RNAi effectively reduces mechanical stretch-induced activation of SCs *in vitro*. Finally, intradermal injection of simvastatin and HMGCR-RNAi could inhibit stretch-induced HS formation *in vivo*, as assessed by reduced scar cross-sectional area, collagen deposition and α -SMA expression.

Conclusion: Our study suggests that mechanical stretch could drive SCs activation by stimulating the key cholesterol biosynthesis enzyme HMGCR, thereby leading to HS formation. Therefore, targeting Schwann cells cholesterol biosynthesis may be a novel treatment option for HS.

Oral Presentation | Free paper (Face)

R08

DEEP PLASMA SKIN RESURFACING: ACCELERATED HEALING WITH HUMAN MSC EXOSOMES

Melinda Lacerna

LA Plastic Surgery

Background: Deep facial skin resurfacing with plasma technology results in better correction of superficial and deep rhytids, photo-damage and more tissue contraction resulting in improved skin and soft tissue tightening, yet safe to perform at the same time as a face and necklift. While the outcome can be quite impressive, the recovery can be daunting. Re-epithelialization can take as long 21 days.

Objective: This study describes how topical application of MSC exosomes immediately after deep plasma resurfacing procedures have decreased the rate to re-epithelialization, decreased pain scores, improved the rate of healing and improved the overall outcomes.

Methods: A retrospective review of one surgeon's experience performing deep plasma skin resurfacing from 2017-current is presented. A total of 100 consecutive patients were treated with full face deep plasma skin resurfacing, 55 of these patients underwent a concurrent facelift and necklift. In 48 patients, MSC exosome application was performed immediately after the procedure. The amount of days to full re-epithelialization were compared between the Exosome treated group (48) and the non-treated group (52).

Results: Range of re-epithelialization for the exosome treated group was 6-14 days, compared to 10-21 days in the non-exosome treated group. Longest follow up is 7 years.

There were four complications, all with the non-exosome treated group. One patient was hospitalized due to severe constipation from post-op opiate use. Three patients developed hypertrophic scarring on the chin that were treated with triamcinolone.

Conclusion: This series over the course of 7 years compares the course of healing of Exosome treated patients versus the non-exosome treated patients following deep plasma skin resurfacing procedures. The use of topical exosomes immediately after the procedure was shown to decrease the days to re-epithelialization from 10-21 days to 6-14 days. In addition, post-operative pain and narcotic use were significantly decreased in the exosome treated group. This is most likely due to down regulation of inflammatory pathways associated with exosome use. The more rapid rate to healing, re-epithelialization and re-establishment of the skin's protective phospholipid bi-layer also decreased other complications such as infections, prolonged erythema, hypo or hyper pigmentation, and hypertrophic scarring.

R09

Research and Clinical Application Prospects of Crt Autologous Collagen Technology

JIN BAI

Crt Autologous Collagen Clinical Research Center

Background:In the field of medical plastic surgery, filling is an indispensable part. At present, most of the popular filling technology is non-self-material, and the safer self-fat filling has some disadvantages. Therefore, the new technology of self-filling is a great power to promote the development of medical plastic surgery.

Objective:Discussion on the Research and Clinical Application Prospect of Crt Autologous Collagen Technology Through Technical Analysis and Technical Demonstration.

Methods:By preparing a self-healing hydrogel carrying a living cell composition of autologous collagen, It has achieved good biocompatibility, biodegradability and antibacterial effect.

Results:In the past 10 years, more than 170,000 cases of chest, buttocks, private and face were treated by Crt autogenous collagen technique. There were no other complications except more than one thousand cases of hard hand feeling, more than one hundred cases of poor shape and more than ten cases of postoperative infection.

Conclusion:Good biocompatibility, biodegradability and antibacterial effect, so as to achieve the technical effect of reducing adverse tissue reactions, At the same time, hydrogel provides a suitable microenvironment to improve the cell survival rate after transplantation, so as to achieve better filling effect and longer maintenance time.

Oral Presentation | Free paper (Face)

R10

A Clinical Study of Platelet-rich Fibrin Combined with Autologous High-Density Fat Transplantation in Augmentation Rhinoplasty

DAN YAN

Department of Plastic and Cosmetic Surgery, Chenzhou First People's Hospital, Chenzhou, Hunan

Background: Augmentation rhinoplasty is one of the most common plastic surgeries in Asia. Experts have conducted much research on augmentation rhinoplasty by injection. Autologous fat transplantation is the most advantageous method due to the abundant source, no rejection reaction and easy to operation. However, The high absorption rate limits the application of autologous fat transplantation in rhinoplasty. Therefore, improving the survival rate of fat after transplantation is the key to promoting this technology.

Objective: This study was designed to analyze the clinical effect of autologous fat-granule transplantation in augmentation rhinoplasty and explore a method to improve the fat retention rate.

Methods: 70 patients were randomly divided into platelet-rich fibrin (PRF) combined with high-density fat transplantation group (combined group) and conventional fat-granule transplantation group (control group). All patients were followed up for more than one year to observe the clinical effects, complications, safety, and satisfaction.

Results: At six months after the operation, the nasal shape was stable, the contour was higher and more stereoscopic than before. No complications such as fat embolism, infection, or necrosis occurred during the one-year follow-up. The satisfactory rate between the two groups have statistical significance($P < 0.05$).

Conclusion: PRF combined with autologous high-density fat transplantation is simple to operate, has a significantly increased fat-retention rate compared with the control group, and has stable long-term effects without obvious adverse reactions. This method can be widely used in clinical augmentation rhinoplasty.

R11

The Role of Adipose-Derived Stem Cells in Creating a Youthful Lower Eyelid in Facial Rejuvenation

QING HE

Shenzhen AKM Aesthetic Surgery Clinic

Background: In daily work, the lower eyelid has a variety of appearances, such as wrinkles, dark eye circles, bulges and a hollow eye, etc. According to different situations, we will take fat graft, fat removal techniques or septal reset, etc., then is there a method that is suitable for all lower eyelid formation, and can make the lower eyelid youthful?

Objective: This study was conducted to use adipose-derived stem cells to creating a youthful lower eyelid in facial rejuvenation

Methods: From January 2019 to January 2022, 48 patients underwent this procedure.

Classification of lower eyelid: I the lower eyelid was flat, with wrinkles or dark eye circles (11 cases)(A+B); II patients with periorbital aging (17cases:transconjunctival-lower-lepharoplasty7&transcutaneous lower lid blepharoplasty 8) (D+A+B); III, lower eyelid introcession, (9 cases)(A+B+C) ; IV Surgical repair(12cases,injections4,surgical-procedure8) (D+A+B+C).Compound rejuvenation mode: A ADSC B Nano fat grafts C Micro fat grafts D traditional surgery

Results: The mean follow-up was 18 months and the mean operations was 2.5. The lower eyelid had a natural and flat appearance, the skin condition and the elasticity were enhanced. 4 patients complained of swelling and bruising.

Conclusion: The application of ADSCs can lead to full regeneration of dermal elastic matrix components. make up for the simplicity of the traditional treatment of the lower eyelid , reduce the potential relative risk of using chemical products. It is a natural, safe and effective method.

Oral Presentation | Free paper (Face)

R12

High Double Eyelid Fold Correction Composite Using Fat Strip Transplantation and Pretarsal Orbicularis Oculi Flap

Haihua Chen

Hangzhou First people's Hospital

Background: As the growing amount of unnatural-appearing upper eyelid after blepharoplasty, it's necessary to find suitable methods for secondary revision.

Objective: This study aimed to evaluate aesthetic outcomes of surgical correction of the high fold using a pretarsal orbicularis oculi flap with fat strip transplantation.

Methods: From January 2018 to September 2023, 50 patients with high and deep double eyelid folds underwent our fold-lowering procedure. All of these patients underwent surgical correction of high folds composite using fat strip transplantation and pretarsal orbicularis oculi flap, with postoperative follow-up ranging from 6 months to 2 years. All the Postoperative outcomes were recorded and reviewed.

Results: Using the composite technique, unnatural, high, and deep double eyelid folds were converted to lower and relative natural folds. Although prior high fold incision scars could be seen postoperatively on close examination, they were not easily visible. Complications included fold height asymmetry in 5 cases, persistence of the prior fold in 6 cases, and redundant upper flap skin that needed further excision in 3 cases.

Conclusion: Secondary blepharoplasty revision to correct the high fold is a challenging procedure for plastic surgeons. Using fat strip transplantation and pretarsal orbicularis oculi flap for correction of the high fold is relatively safe and effective. This provides a new treatment option in secondary revision techniques.

Oral Presentation | ISPRES APRAS award session 2

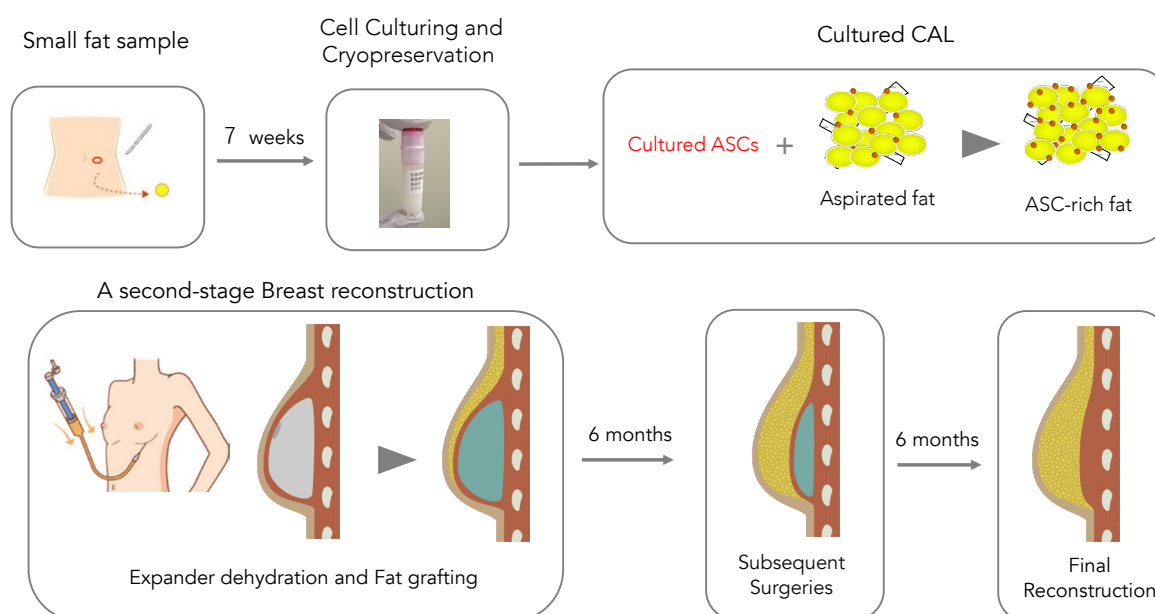
R13**Innovative Cultured Cell-Assisted Lipotransfer for Breast Reconstruction**Yuko Asano¹, Saori Unno², Naoko Tsuji²¹ Kameda Medical Hospital² Cellport Clinic Yokohama

Objective: Since 2008, we have been performing Cell-assisted lipotransfer (CAL) for cosmetic and reconstructive breast surgery at the Cellport Clinic Yokohama. CAL involves the isolation of adipose stem cells from additional fat harvested during surgery. However, CAL techniques prolonged operation time and required excessive fat harvesting. To address these issues, cultured CAL was developed, wherein stem cells are cultured and expanded from a minimal fat volume prior to surgery. This study presents our experiences with cultured CAL for breast reconstruction.

Methods: This retrospective study includes fourteen patients who underwent whole breast reconstruction with cultured CAL. After six months of the tissue expander (TE) dilation, a second-stage breast reconstruction was performed. Seven weeks before surgery, a small fat sample was excised for stem cell culturing and cryopreservation. During reconstructive surgery, following TE dehydration and temporary removal, aspirated fat combined with cultured stem cells was grafted into the subcutaneous layer, and the TE was returned to the pocket. Subsequent surgeries were conducted every six months until TE removal and final reconstruction. Data on operative frequencies, aspiration and injection volumes, and reconstructed breast volume were collected.

Results: The average number of operations was 3.6, with a total fat harvest volume averaging 979.4 cc. The ratio of the final reconstructed breast volume to the healthy breast was 94%. No major complications were observed.

Discussions: Cultured CAL addresses the limitations of conventional CAL. Future discussions will focus on the potential of cultured CAL and the measures required to ensure its safety and efficacy.



Oral Presentation | Free paper (Body contouring)

R14

Safety of Brazilian Butt Lift Surgery (BBL): Insights from the UK Ban and National Guidelines

Omar Tillo

Creo Clinic, London

Background:

The Brazilian Butt Lift (BBL) procedure has gained popularity worldwide for its ability to enhance hips and buttock shape and size. However, concerns regarding its safety, particularly the risk of fat embolism, prompted the British Association of Aesthetic Plastic Surgeon (BAAPS) to impose a moratorium on performing this procedure in 2018.

Objective:

This presentation aims to explore the events leading to the UK ban on BBL surgery, assess its impact on surgeons and patients, and discuss the efforts made to analyse the safety of the procedure. Additionally, it examines the development and publication of new national guidelines and safety recommendations for BBL surgery.

Methods:

The presentation reviews the timeline of events leading to the UK ban on BBL surgery. It analyses the challenges faced by surgeons following the ban and the risks faced by patients seeking this procedure. Furthermore, it discusses the collaborative efforts undertaken to evaluate the safety of BBL surgery, incorporating both old and new evidence.

Results:

The presentation highlights the comprehensive review of scientific evidence on BBL surgery safety, leading to the formulation of updated national guidelines and safety recommendations. It discusses the key findings from this analysis and the implications for both surgeons and patients considering BBL procedures.

Conclusion:

In conclusion, the presentation emphasizes the importance of evidence-based practice in plastic surgery and the necessity of adhering to strict safety guidelines. It underscores the ongoing efforts to ensure the safety of BBL surgery and provides insights into the future direction of this evolving procedure.

755-nm picosecond laser combined with bioactive polymer dots to reverse photo-damage on nude mouse model

Chang Cheng Chang^{1,2}, Tzong Yuan Juang², Jia Chee Siew³, Yi Hsuan Tu³, Hoi Man Iao², Sian Cian Fan²

¹ Division of plastic and reconstructive surgery, China medical university hospital

² Institute of cosmeceutics, China medical university

³ school of medicine, college of medicine, Chinamedical university

Background: Picosecond laser could produce laser-induced optical breakdown. In addition, polymer dots (PDs) can promote vascular proliferation, achieving skin repair and inhibiting inflammation via epithelial mesenchymal transformation.

Objective: Our research explores a novel approach that combines a 755-nm picosecond laser with bioactive PDs to reverse photo- damage in a nude mouse model.

Methods: Twelve 6-week-old BALB/c nude mice with UVB irradiation, divided into (1) UVB group, and various treatment groups including (2) UVB + PEG1000, (3)UVB + PDs + PEG1000, and (4)UVB + Laser + PDs + PEG1000. All mice are subjected to UVB irradiation over the course of 10 weeks Assessments were conducted using immunohistochemistry (IHC), enzyme-linked immunosorbent assay (ELISA), and Masson's trichrome (MT) staining to gauge collagen content, epidermal thickness, and expression levels of proteins related to photo-damage repair.

Results: MT staining revealed a notable 30% increase in collagen retention within the UVB + Laser+ PD group by day 11. The reduction of MMP-9 levels in UVB+PD+PEG1000 group on day 11 achieving 4.2%, compared to 9.3% in UVB group on day 1 ($p=0.03$). Furthermore, IL-6 levels experienced a substantial decrease across all treatment groups versus the UVB group on day 1, signaling a notable reduction in inflammation ($p < 0.001$). The analysis of Smad2/3 signaling in the UVB+PD+PEG1000 group on day 11 achieving 2.8%, compared to 1.3% in the UVB group on day 1, revealed an enhanced activation of skin repair.

Conclusion: The combination of the 755-nm picosecond laser with bioactive polymer dots provides a therapeutic strategy for reversing photo-damage. This technique not only bolsters collagen production but also promotes a novel pathway for skin repair and aging reversal, meriting further exploration for clinical application.

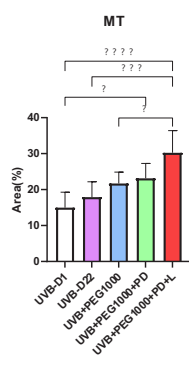


Figure 1.

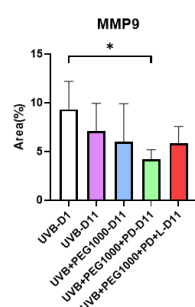


Figure 2.

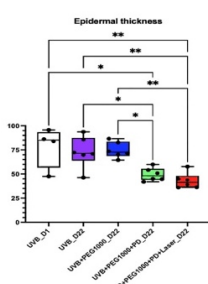


Figure 3.

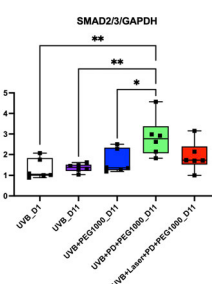


Figure 4.

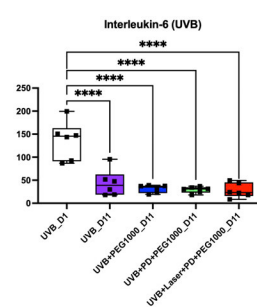


Figure 5.

Oral Presentation | Sydney Coleman award session

R16

Exosomes Combined with Polymer Dots Dressings and 755 nm picosecond laser accelerate wound Healing in Nude Mice

Chang Cheng Chang¹, Yen Jen Wang⁴, Jia Chee Siew³, Yi Hsuan Tu³, Tzong Yuan Juang²

¹ China medical university hospital

² Institute of cosmeceutics, China medical university

³ school of medicine, college of medicine, Chinammedical university

⁴ Divison of dermatology McKay memorial hospital

Background: Exosomes are extracellular nanovesicles mediating intercellular communication. Porcine fallopian tube stem cells (PFTSC)-derived exosomes and polymer dots (PDs) dressings have been proved to promote cells proliferation and migration.

Objective: To investigate whether PFTSC-derived exosomes, exosomes combined with PDs dressings and/or pretreated with a 755 nm picosecond laser with a diffractive lens array accelerate wound healing in nude mice.

Methods: . Fifteen nude mice were randomly divided into five groups: (1) Controls (2) Exosomes (3) Exosomes + PDs (4) Laser + Exosomes (5) Laser + Exosomes + PDs. Full-thickness wounds were created on the back of each mouse. The wound area was evaluated by Image-J. ERK1/2, pro-collagen1/3, collagen1/3, CD31, VEGF, EGF, E-cadherin, Vimentin, Filaggrin, and Aquaporin 3 were examined by the wound tissues with ELISA, immunostaining, and masson trichrome (MT) staining.

Results: Level of VEGF, EGF and CD31 were significantly higher than the control group on day 3 (VEGF, 18% in Laser+Exosomes+PD vs 4% in controls, $p<0.0001$; EGF, 1.6% in Exosomes+PD vs 0.5% in controls, $p<0.01$; CD31, 17% in Laser+Exosomes+PD vs 5% in controls, $p<0.05$). Expression of filaggrin was stronger in Laser+Exosomes+PD group than Exosomes alone (11% vs 6%, $p<0.05$). Wound area was reduced to 13% in Laser+Exosomes+PD group vs 33% in controls($p<0.0001$). MT staining revealed significant increase of collagen (39% in Laser+Exosomes+PD vs 19% in Controls, $p<0.0001$).

Conclusion: The group of exosomes combined with PDs dressings and picosecond laser had demonstrated faster re-epithelization with more collagen deposition and. The combination is potential for further investigation on human chronic wound.

Oral Presentation | Sydney Coleman award session

R17**Using Bilateral Pedicled Transverse Rectus Musculocutaneous Flap and Fat Grafting for Autologous Breast Augmentation**

Tung Dinh Nguyen, Khiem Xuan Pham

Emcas Plastic Surgery Hospital

Background: The silicone gel implant is currently the most popular method of breast augmentation, but its use is associated with a number of risks, including capsular contracture, seroma, implant malposition, visibility of the implant, and anaplastic large cell lymphoma (ALCL). Breast augmentation by fat grafting can avoid the complications of implant breast augmentation, however, the degree of reabsorption of the injected adipose tissue is unpredictable. Fat resorption has been reported by multiple authors, it has been associated with increased fat resorption, which varies between 25-75%, primarily due to fat apoptosis, necrosis, and liquefaction. In the last 20 years, autologous flaps have been used in several studies for breast augmentation to limit complications.

Objectives : To evaluate the effectiveness and safety of using bilateral pedicled TRAM flap combination with fat grafting for autologous breast augmentation.

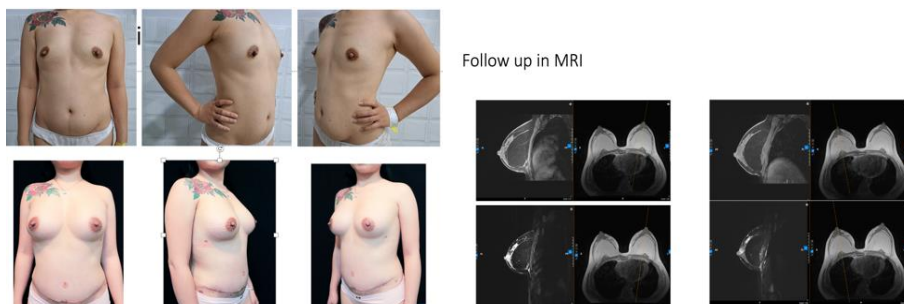Method : Selection criteria of patients: Patients who desire body-contouring surgery with abdominoplasty, no planned pregnancies, do not desire implants, in cases:

- Small breast with or without ptosis, abdominal scar.
- Implant removal due to different reasons: capsular contracture, seroma, implant malposition, visibility of the implant...
- Complication of free liquid silicone injection due to breast augmentation.

Surgical technique : Pocket was made in subglandular position of breast. The transverse rectus abdominis (TRAM) flap with deepithelialized was divided into 2 parts and mobilized off the abdominal wall with its vascular pedicle intact. A tunnel is created in the medial inframammary fold. Flap is positioned in the breast pocket, it is tacked in place and further shaped. The abdominal wall defect is closed. An interposition piece of mesh is necessary inserted to prevent future hernias. Liposuction was performed in the hip waist, fat was grafted at the fat layer around both breasts.

Results : A total of 32 cases met the inclusion criteria. The reason for operation mainly is implant capsular contracture (40.6%), the horizontal scar of the low abdominal area is popular (56.3%), the awaited volume of an autologous lateral TRAM flap is 225.78cc, the average amount of fat grafting is 56.87cc for each breast. Following surgery, no cases of complete or partial flap loss were clinically detected. There were no hernia or bulging issues, and 01 case was an infection. Patients were followed from 6 to 12 months. MRI 3Tesla was used to assess the survival of fat grafting and TRAM flap. Using BREAST -Q to assess the satisfaction of all patients, 68.8% somewhat agree and 31.3% definitely agree with their expectation, 0 % disagree, sum score is 18- 19 (78.2%) equivalent score is 60-64.

Conclusions: The initial success suggested the effectiveness and safety of autologous breast augmentation by using pedicled TRAM flap and fat grafting in the selective patients.



Oral Presentation | Sydney Coleman award session

R18

Innovative approach to total skin substitute with 4th generation biomaterials

Břetislav Lipovský^{1,2}, Veronika Pavlišáková², Eva Horálková¹, Anna Smolnická³, Martin Faldyna⁴, Edita Jeklová⁴, Irena Koutná^{3,5}, Lucy Vojtová²

¹ Department of Burns and Plastic Surgery, Faculty of Medicine, Masaryk University, University Hospital Brno, Czech Republic

² CEITEC – Central European Institute of Technology, Brno University of Technology, Brno, Czech Republic

³ Department of Histology and Embryology, Faculty of Medicine, Masaryk University, Brno, Czech Republic

⁴ Veterinary Research Institute, Brno, Czech Republic

⁵ Cell and Tissue Engineering Facility, International Clinical Research Center, Brno, Czech Republic

Background:

Over the past several decades, there have been dramatic advantages in the quality of care provided to patients with burns. The basic limitation for the 21st century remains the issue of local care. Thanks to the modern possibilities of biomaterial and cell engineering, we can offer these patients effective options for improving the quality of subsequent life.

Objective:

In our current research strategy, we are trying to focus on a dermal regeneration strategy using an innovative stable form of Fibroblast growth factor 2 (FGF2-STAB[®]) and Fibroblast growth factor 7 (FGF7-STAB[®]) targeting to 4th generation biomaterials development for total skin substitute.

Methods:

In the first stage, we developed and successfully evaluated the 2nd generation of biomaterials as part of dermal substitute (unique porous biopolymer collagen chitosan foam enriched with FGF2-STAB[®]). We are now in the second phase of development and evaluation of 4th generation biomaterials containing FGFs and differentiated MSCs.

Results: In the first phase, full biocompatibility of our resorbable dermal substitutes was demonstrated in a swine model within 3 and 6 months of follow-up. Increased neovascularization and fibroproliferation were proved by Chick Chorioallantoic Membrane (CAM) assay and animal model experiment. In the second phase, we successfully seeded cell populations into our biomaterials with growth factors and began to evaluate within *in vitro* and animal models.

Conclusion: Bilayer skin substitute with FGFs demonstrated superior biological activity by neovascularization. Our current ambition is to use tissue engineering methodology for the development of 4th generation biomaterials in total skin substitution.

Acknowledgements: This study was supported by the Ministry of Health of the Czech Republic, grant No. NU22-08-00454 and funds from the Faculty of Medicine number MUNI/A/1598/2023. All rights reserved.

R19

Latissimus Dorsi and Immediate Fat Transfer (LIFT) for Breast Reconstruction after Mastectomy: A Case Series

Sakurako Murata, Kyoko Dogo, Yuzo Komuro

Teikyo University School of Medicine Department of Plastic, Oral and Maxillofacial Surgery

Background: Although the latissimus dorsi (LD) flap is a common option for breast reconstruction, its use is limited by the volume of transferred tissue. The extended LD flap is used to ensure sufficient breast volume, but increases the risk of donor site deformity and seroma formation. Latissimus dorsi and immediate fat transfer (LIFT), first reported in 2014 by Santanelli et al., may help prevent these complications while providing sufficient breast volume.

Objective: The purpose of this study was to report our experience with LIFT in breast reconstruction and evaluate complications and additional operations.

Methods: A retrospective study was performed of 10 patients who underwent unilateral breast reconstruction post-mastectomy using LIFT from November 2019 to May 2024.

Demographic and operative data, complications, and the number of additional operations were analyzed.

Results: The mean patient age was 49.6 years, and the mean body mass index was 22.5 kg/m². The average total fat grafting volume was 228.1 mL. The average duration of dorsal drain placement was 11.3 days. Complications were observed within a mean follow-up period of 25.2 months. Two patients (20.0%) developed a seroma at the donor site. No cases of flap or fat necrosis were noted. Additional fat grafting was performed on one patient to enhance the volume of the reconstructed breast.

Conclusion: LIFT for breast reconstruction is a safe and effective technique to enhance flap volume and prevent seroma formation at the donor site. This approach may expand the indications for the LD flap to more patients desiring autologous reconstruction.

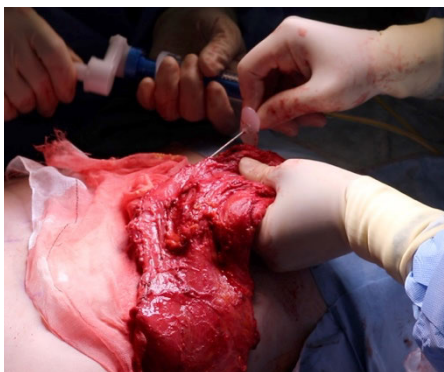


Fig. 1. Intraoperative clinical image demonstrating fat injection into the LD flap.

Oral Presentation | Free paper (Fat for reconstruction/ regeneration 1)

R20

Fat tissue: a decisive treatment for the management of complicated wounds in a high morbidity patient.

CYNTHIA I EUAN VAZQUEZ^{1,2,3,4}, ARNOLDO O TOPETE GONZALEZ¹,
ANTONY JAMES JACKSON⁴, RAUL A VALLARTA RODRIGUEZ^{1,3}

¹ AMCPER

² ISPRES

³ ISAPS

⁴ BAPRAS

Background: Fat tissue over the years has been recognised as a treatment in the cosmetic and reconstructive fields for restoration of volumen, also for its endocrine properties of the tissue that allow cell regeneration, stem cells derived from fat tissue are promising and realistic choice in patients where reconstructive treatment alternatives are not an option.

Objective: We wanted to demonstrate with this case that the fat transfer was a decisive option for covering and saving a patient's leg.

Method: In a 76 y/o female patient with chronic renal failure, diabetes mellitus type 2 and systemic arterial hypertension. Two months before she was treated for a reduction of a right tibia fracture, this was performed with complications of bone exposure, tissue loss and a failed soleus flap with necrosis & substantial tissue loss. We performed a fat transfer from the inner thigh to the tibia using the Dr Marco A. Pellon "sandwich" technique three times every 7 days which led to improving tissue coverage and growth, after three weeks we successfully proceeded with a skin graft to the area.

Conclusion: A fat transfer with its exosomes and endocrine functions is a considerable option for patients who require coverage after the loss of tissue in complicated wounds & that also have multiple comorbidities. In this complex case we demonstrated that the fat transfer was an effectiveness option to cover and save the patient's leg.



Oral Presentation | Sydney Coleman award session

R21

Advanced adipose-derived stem cell protein extracts (AAPE) as an alternative regenerative treatment option for bedridden patients.

CYNTHIA I EUAN VAZQUEZ^{1,2,3,4}, ANTONY JAMES JACKSON⁴

¹ AMCPER

² ISPRES

³ ISAPS

⁴ BAPRAS

Background: Advanced adipose-derived stem cell protein extracts (AAPE) have been used instead of live stem cells for their effectiveness in oxidative stress and matrix metalloproteinases (MMPs) related to tissue repair in human dermal fibroblasts (HDFs). In particular, it has been demonstrated that adipocyte-derived agents can be effective in tissue regeneration. Bedridden patients who are susceptible to developing bedsores treatment options are scarce which leads us to look for other non-surgical alternatives to reduce morbidity.

Objective: To demonstrate the effectiveness of the AAPE treatment in a heel pressure ulcer of a bedridden 91 y/o woman with senile dementia.

Methods: We proposed to start the treatment with the AAPE, after one month the patient was treated with wound healing and synthetic dressings without showing any improvement and with increased extension. The AAPE treatment was performed every 30 days, administration was both intradermal and topical with an amount of 2ml of the AAPE all around the wound over a period of six months. AAPE applications were performed simulataneuosly with wound healing techniques such as an antiseptic spray (Microdacyn) and Ketanserin applied gel daily. At the end of the treatment the wound had recovered completely and after 5 years it has not recurrered.

Conclusion: AAPE is an excellent alternative in patients where surgical treaments are unavailable and can be performed at home due to being constitutionally well suited to the promotion of dermal wound healing and secretory factors.



Oral Presentation | ISPRES APRAS award session 2

R22

Use of resected fatty tissues and SMAS tissues auto-grafting in facial rejuvenation

Jinho Lee

AB Plastic Surgery Clinic, Seoul, Korea

Background: Fat grafting is an essential method in facial rejuvenation. When performed with facelift, it could yield a synergistic effect in the aspects of natural appearance and improved skin quality by integrating with facial tissues. Combining with rejuvenation surgery, traditional fat harvest from “far-away” donor site is not mandatory for the facial volumization. During the necklift procedures, supra-plastysmal fat could be delicately resected and reserved. Lateral SMAS tissue after sub-SMAS dissection, as well, could be a useful graft source. These tissues can be finely diced and reutilized as a decent graft source for the facial volume restoration.

Objective: Aim of this study is to investigate the use of obtained fatty and SMAS tissues as autologous graft material during the facelift.

Methods: Retrospective chart review of patients for Sub-SMAS facelift and necklift in conjunction with fat grafting between 2020 and 2023 was performed. Patient assessments were obtained; group 1 (48 patients) with autografting technique and group 2 (31 patients) with conventional fat harvest and grafting.

Results: Group 1 showed similar fat retention and overall result with group 2. (Table 1) Apart from some cases with fat reabsorption, no major complications were observed in both groups.

Conclusion: The use of SMAS tissue as an autograft material has been previously reported. “Neck-to-face” auto-grafted fat was also successfully transited with high predictability and viability. Many primary cases are applicable for this technique with the exception of cachectic patient. Without donor site morbidity, auto-grafting can be another reliable option for simultaneous facial rejuvenation surgery and fat grafting.

Oral Presentation | Free paper (Research)

R25

Optimization of an adeno-associated viral vector for keratinocytes *in vivo*

Qi Shen¹, Yuta Moriwaki¹, Zening Du¹, Shogo Suga², Yusuke Hirabayashi², Masakazu Kurita¹, Mutsumi Okazaki¹

¹ Department of Plastic and Reconstructive Surgery, The University of Tokyo Hospital

² Department of Chemistry and Biotechnology, School of Engineering, The University of Tokyo

Purpose:

The adeno-associated virus vector (AAV) is a powerful gene therapy vector for *in vivo* gene transduction. We have developed a new AAV capsid, named AAVDJK2, which has higher efficiency and specificity to cultured keratinocytes than other AAVs used for keratinocytes in the previous reports. *In vivo* efficacy of AAVDJK2 was tested using mice skin.

Methods:

To test the efficacy of AAVDJK2 to AAVDJ (one of the most efficient AAV in the existing AAVs), we generated GFP-expressing AAVDJK2 and mCherry-expressing AAVDJ. Mixtures of two virus solution were prepared and injected intradermally into mice back skin. The expression of GFP and mCherry in each skin layer (epidermis, dermis, hypodermis, and panniculus carnosus) was quantified by automated and unbiased analysis.

Results:

The number of AAVDJK2-delivered, GFP-positive cells was higher than that of AAVDJ-delivered, mCherry-positive cells in the epidermis, and the opposite trend was observed in deeper layers. Thus, the higher epidermal specificity of AAVDJK2 suggested was confirmed in mouse skin *in vivo*.

Conclusions:

The AAVDJK2 capsid improves gene delivery to the epidermal keratinocytes *in vivo*. The novel AAV system may benefit experimental research and the development of new epidermis-targeted gene therapies.

Oral Presentation | Free paper (Research)

R26

Challenges to Complete Skin Regeneration; Regulation of AMPK and Rac1 Activity Promotes Wound Healing via Induction of Actin Cable Formation

Kento Takaya¹, Yuka Imbe², Qi Wang², Shigeki Sakai¹, Keisuke Okabe¹, Noriko Aramaki-Hattori¹, Kazuo Kishi¹

¹ Department of Plastic and Reconstructive Surgery, Keio University School of Medicine

² Faculty of Pharmacy, Keio University

Background: Unlike adults, early developing fetuses can completely regenerate tissue. Particularly, mice epidermal structures, including texture patterns, are regenerated until embryonic day (E) 13, leaving visible scars thereafter. Although the changes in actin dynamics are known to be involved in this transition, the detailed mechanism remains unclear.

Objective: We investigated the effects of AMP-activated protein kinase (AMPK) and Rac1, factors involved in regulating cell migration and actin dynamics using mice wound model.

Methods: (1) Regulation of Rac1 activity: PAM212 cell was treated with Rac1 inhibitor NSC23766 and the effect on migration ability was evaluated. We generated epidermis-specific Rac1 knockout mice (K14-CreERT2;Rac1^{flox/flox}) and observed the wound healing process and actin dynamics in fetuses and adults. (2) Regulation of AMPK activity: Fetuses of ICR mice were wounded and AMPK activator salicylate was administered. Wound morphology was analyzed by 3D reconstruction of the wound images, and the presence of actin cable formation and the behavior of related molecules were observed.

Results: Epidermal cell migration was inhibited by NSC23766 and salicylate administration. In epidermis-specific Rac1 knockout fetal wounds and salicylate treated wounds on E14, actin cable formation, which normally disappears, was induced and the wounds regenerated completely.

Conclusion: Actin cables are involved in complete skin regeneration, and we observed that activation of AMPK and induction of actin cable formation through Rac1 regulation induced skin regeneration and accelerated healing. This finding suggests that regulation of AMPK and Rac1 may be a candidate therapeutic approach to improve the wound healing process.

Oral Presentation | Sydney Coleman award session

R27

Gene Therapy Using Adipocytes

Yoshitaka Kubota, Kentarou Kosaka, Yoshihisa Yamaji, Shinsuke Akita, Yoshiro Maezawa, Masayuki Kuroda, Kotaro Yokote, Nobuyuki Mitsukawa

Chiba University

Introduction: Subcutaneous adipose tissue is familiar to plastic surgeons and can be harvested minimally invasively, making it a promising material for regenerative medicine. We report the world's first gene therapy using patient-derived subcutaneous adipose tissue for a patient with lecithin-cholesterol acyltransferase (LCAT) deficiency.

Case & Methods: A male in his 20s was diagnosed with LCAT deficiency after presenting with corneal opacity and low HDL cholesterol levels. Subcutaneous adipose tissue was aspirated from the patient's abdomen, treated with collagenase, and centrifuged. Floating fractions were cultured using the ceiling culture method to isolate ccdPAs. LCAT genes were introduced using a retroviral vector. The cells were cultured and, three weeks post-harvest, 1×10^9 cells were injected subcutaneously into the abdomen with fibrin glue.

Results: After 240 weeks, there were no significant adverse events, and we observed sustained beneficial effects such as increased LCAT activity, normalization of lipid profiles, and reduced proteinuria.

Discussion: The average lifespan of adipocytes is approximately ten years, allowing for long-term survival post-transplantation. For plastic surgeons, subcutaneous adipose tissue is easy to harvest with minimal invasiveness. Adipose tissue is the largest endocrine organ in the human body and inherently has high secretory capabilities, making it suitable as a vehicle for gene therapy. This study represents the first use of adipocytes in human gene therapy, with maintained effects observed over four years. Future applications may include hemophilia and diabetes. It is crucial for plastic surgeons to lead the research on adipocyte-based therapies.

R28

Frozen Assets: A Comprehensive Review of Adipose Tissue Cryopreservation Techniques and Our Personal Experience

Benedetta Agnelli¹, Matteo Malacco²

¹ Division of Plastic and Reconstructive Surgery, Department of Biotechnology and Life Sciences, University of Insubria, Varese, Italy

² FMH Plastic, Reconstructive and Aesthetic Surgery, Lugano, Switzerland

Background: Autologous fat transplantation (AFT) is a common procedure in plastic and reconstructive surgery, with growing applications. Despite its benefits, the literature reveals a highly variable and unpredictable absorption rate of transplanted fat, posing significant limitations. Multiple sessions are often required, increasing patient discomfort and potential complications. Adipose tissue cryopreservation has recently emerged as a promising solution to these challenges, although no ideal protocol exists yet.

Objective: We aim to present our research in the field, review the current clinical applications documented in the literature, and explore exciting future prospects for using preserved lipoaspirates in repeated fat grafting procedures or as cell-based therapies for reconstructive purposes.

Methods: We conducted a systematic literature review in line with the Preferred Reporting Items for Systematic Reviews and Meta-Analyses (PRISMA) guidelines. We utilized specific keywords and predefined MeSH terms across various search engines. Concurrently, we present our method and compare it with the findings of the literature.

Results: A total of 24 studies have been included in the review. Dimethyl sulfoxide (DMSO) is the most commonly used cryopreservative agent. Several parameters including cell viability, cell morphology, toxicity and methods of freezing and thawing have been investigated.

Conclusion: Determining the most effective and straightforward method for adipose tissue cryopreservation is a complex and debated issue with multiple approaches available. However, promising new techniques are emerging in the literature, suggesting a bright future for this field.

Oral Presentation | Free paper (Fat for the breast 1)

R29

Nano fat grafting improves radiation skin changes in breast cancer patients

Paulo Piccolo

National Center for Plastic Surgery

Background:

Regenerative properties of fat grafting have been widely confirmed. More recently nanofat has been shown to carry the same growth factors and mesenchymal cells in a more concentrated way, confirming its valuable regenerative properties in a wide range of cases.

Objective:

This study focuses on the use of nanofat deposit in breast cancer patients to improve radiation changes.

Methods:

This is a retrospective review of the author's experience using nanofat grafting deposited via a microneedling device over radiated skin of breast cancer patients. Three patient cases were reviewed. Surgeries were performed under general anesthesia. The fat was harvested from the flanks using suction assisted lipectomy with the Tulip system and a 50cc syringe. The fat was decanted and the excess fluid/oil was removed. The remainder of the fat was emulsified using the Single-use nanofat transfer kit from Tulip (Tulip Medical Products, San Diego, USA). The nanofat was delivered directly on the affected skin using a microneedling device at 2.5mm depth, until punctate bleeding was noted. The amount of volume deposited was between 30-35cc.

Results:

The procedure was performed once in each patient. The patients were all female. The age range was 37-62 years old. All three had unilateral invasive cancer diagnosis. Two had radiation after lumpectomies (one of which had a skin-sparing mastectomy – SSM - to follow) and one had radiation following a SSM. The timing from radiation before the nano fat procedure ranged from 6 months to 3 years. Two patients had a previous abdominally based free flap 6-8 months prior and one patient had an oncoplasty reconstruction following a lumpectomy prior to the nanofat procedure. They all had one session of nanofat grafting. Follow-up ranged from 2 - 17 months. All patients experienced an improvement in the quality of the skin in the way of improved elasticity, improved hyperchromia, and increased skin softness. There were no complications.

Conclusion:

Nanofat grafting is a good adjunct procedure in improving the overall skin elasticity, softness and color following radiation for breast cancer.

Oral Presentation | Free paper (Stem cells/ Tissue engineering)

R30

THE “EMPANADA” REGENERATIVE IMPLANT FOR DIRECT TO IMPLANT BREAST RECONSTRUCTION

Andrew Salzberg

Cleveland Clinic

Background: A 5 year experience of novel tissue construction for outpatient prepectoral immediate breast reconstruction will discussed with outcomes and complication data in more than 100 patients in the United States.

Objective: To enhance the immediate direct to implant breast reconstructive long and short term outcomes in implant based breast reconstruction

Methods: Description of the novel technique with patient cohort data and outcomes will be presented

Results: In over 100 patients and 168 breasts in prepectoral postmastectomy reconstruction the short and term evaluated results show lower than expected incidence of hematoma ,infection and capsular contracture over 5 years.

Conclusion: This novel regenerative construct is applicable to immediate implant based breast reconstruction worldwide with low complication rates done as an outpatient procedure.

Oral Presentation | Sydney Coleman award session

R31

Exploring Strategies to Enhance Fat Retention Rates-A Case Study on Breast Fat Grafting

JIANBO SANG

Shanghai Beaucare Clinics

Background: Breast fat grafting is a common method of autologous fat transfer in cosmetic and reconstructive surgeries, with outcomes often limited by fat retention rates. Traditional fat processing methods (such as settling, centrifugation, and filtration) have their limitations. Addressing these issues, the adoption of improved fat processing techniques could significantly impact fat retention rates.

Research Objective: This study aims to evaluate the impact of a novel fat processing method—gauze filtration combined with rinsing and cotton pad dehydration—on the retention rate of breast fat grafts and to analyze its effects on postoperative breast size stability.

Methods: The study included 195 patients who underwent breast fat grafting from August 2017 to May 2024. All patients underwent fat preparation using gauze filtration, rinsing, and cotton pad dehydration to produce ultrapure fat, carefully selecting fat without fascia for transplantation. Patient breast circumference, under-breast circumference, and weight were measured regularly to track long-term postoperative outcomes, especially the changes in breast circumference under relatively stable weight conditions.

Results: During the postoperative follow-up period, most patients showed a minimal range of changes in breast circumference, indicating high fat retention rates and good stability of breast morphology. Additionally, among the 15 patients who underwent a second fat grafting, those treated with the repeated use of the improved fat processing method demonstrated better retention outcomes than those from the single surgery.

Conclusion: The fat processing method using gauze filtration and cotton pad dehydration significantly enhanced the retention rate of breast fat grafts and the stability of postoperative breast size. This method provides an effective technical strategy to improve the outcomes of fat grafting and warrants further research and clinical application.

Keywords: Breast fat grafting, fat retention rate, fat processing techniques, long-term follow-up, breast morphology stability

Oral Presentation | ISPRES APRAS award session 2

R32

Strategy for Treating Gummy Smile: A Simple and Powerful Resolution with Fat Grafting

Wen-Hui Chen¹, I-Feng Sun², Tsai-Ming Lin³

¹ Department of Dentistry, Eda hospital, Kaohsiung, Taiwan

² Astrid Clinic, Kaohsiung, Taiwan

³ Charming Institute of Aesthetic and Regenerative Medicine (CIARS), Kaohsiung, Taiwan

Background: A gummy smile, characterized by excessive gingival display, can significantly affect aesthetic appeal and self-confidence. Traditional treatments, including botulinum toxin injections and various surgical interventions, offer inconsistent results and have their limitations. This study investigates the use of Micro-Autologous Fat Transplantation (MAFT) as a novel and effective approach for treating gummy smiles.

Objective: To evaluate the long-term efficacy, patient satisfaction, and safety of the MAFT technique in correcting gummy smiles.

Methods: A retrospective analysis was conducted on 50 patients treated for gummy smiles using the MAFT technique. The procedure involved harvesting fat from donor sites, centrifuging it, and micro-transplanting it into the nasolabial groove, philtrum, and upper lip areas under local anesthesia. Patients were followed up over an average of three years to assess the reduction in gingival display, patient satisfaction, and the occurrence of any complications.

Results: The MAFT technique significantly improved the appearance of gummy smiles in all patients, with an average reduction in gingival display of 3-5 mm. Enhanced volume and thickness of the upper lip and nasolabial areas contributed to the aesthetic improvement. The procedure had a high patient satisfaction rate, with over 95% of patients reporting favorable outcomes. The results were well-maintained over the three-year follow-up period, and minimal complications were observed.

Conclusion: MAFT provides a reliable, minimally invasive, and effective solution for treating gummy smiles, offering long-term results and high patient satisfaction. This technique improves aesthetic outcomes by enhancing lip volume and reducing gingival display, making it a valuable tool in aesthetic and reconstructive surgery. Future advancements in this technique are anticipated to further refine its precision and efficacy, ensuring optimal clinical outcomes.

Oral Presentation | Free paper (Stem cells/ Tissue engineering)

R34

Innovative Solutions in Scalp Wound Reconstruction: Experience with NovoSorb® BTM

Benedetta Agnelli¹, Luigi Valdatta¹, Monica Falaschi², Emiliano Bernuzzi²,
Simone Dusi¹, Federico De Maria²

¹ Division of Plastic and Reconstructive Surgery, Department of Biotechnology and Life Sciences,
University of Insubria, Varese, Italy

² ASST Ovest Milanese, U.O.C. Chirurgia Plastica e della Mano

Background: NovoSorb® Biodegradable Temporising Matrix (BTM) is a fully synthetic dermal matrix used for reconstructing complex wounds. Comprising a 2mm-thick biodegradable polyurethane foam covered by a non-biodegradable membrane, NovoSorb facilitates cellular infiltration and neodermis formation, making it a vital tool in wound management. Many wounds, especially those on the scalp, pose significant reconstruction challenges due to their complexity and location.

Objective: This study aims to present our personal experience with NovoSorb BTM, a recent innovation in wound care technology that is still underutilized in Italy. We focus on its application in scalp lesions, highlighting the potential benefits and effectiveness of this synthetic dermal matrix in complex wound reconstruction.

Methods: We conducted a retrospective observational study involving patients treated with NovoSorb BTM for scalp lesions. Data on patient demographics, wound etiology, treatment timeline, integration period, and complications were collected and analyzed. The primary outcome was the successful integration of BTM, followed by a full-thickness skin graft (FTSG) application. Secondary outcomes included the time to BTM integration and the rate of complications during the treatment process.

Conclusion: Our findings indicate that NovoSorb BTM is a robust and effective option for managing complex scalp wounds, even in patients with comorbid conditions. Successful BTM integration allowed for subsequent FTSG in the majority of cases, demonstrating its potential as a valuable reconstructive tool. Further research is recommended to optimize its use and to better understand the factors influencing integration and overall treatment success.

E-poster

R33

Overcoming the three-dimensional complexity of vulvar defects: a stepwise, multi-flap approach

Chuan Han Ang, Bien Keem Tan, Kok Chai Tan, Chee Liam Foo

Singapore General Hospital

Background:

Complex vulvar defects are challenging owing to their three-dimensional nature and proximity to the vaginal, urethral and anal orifices.

Objective:

The purpose of this paper is to introduce the concept of a multi-flap reconstructive approach to these defects based on anatomical subunits.

Methods:

Four female patients with complex vulvar defects characterized by involvement of the vaginal wall, the anal canal and the perineum, secondary to extra-mammary paget's disease or squamous cell carcinoma resection, were studied. Defect size ranged from 108 to 157cm². The outcomes were analyzed clinically and by a 4-point questionnaire regarding micturition, defecation, coital function, introitus opening and aesthetics.

Results:

The anatomical subunits of the vulva were covered primarily by the gluteal fold flap, with additional flaps including the mons pubis rotation flap, the gracilis muscle flap, and the medial thigh VY advancement flap. The associated perianal skin and anal canal defects were covered by the buttock VY advancement flap and the gluteal fold flap. There were no flap complications. The average follow-up duration was 7 years. Patients' satisfaction with their aesthetic and functional outcomes was favorable.

Conclusion:

Gluteal fold flaps were the workhorse flaps for perineal reconstruction of defects involving the vulva and anus. Additional local flaps were employed strategically in a staged manner, with the aim of preserving native anatomical features and minimizing functional impairments.

Oral Presentation | Sydney Coleman award session

R35

Superior retention of aged fat graft by supplementing young adipose-derived stromal cells in a murine model

Ki Yong Hong¹, Vinh Vuong The Tran², Xian Jin³, Xin Ye Zhou¹, Hak Chang¹

¹ Department of Plastic and Reconstructive Surgery, Seoul National University Hospital, Seoul National University College of Medicine, Seoul, Korea

² Hi-Tech Center, Vinmec Healthcare System, Hanoi, Vietnam

³ Department of Plastic Surgery, the Second Affiliated Hospital, Medical School, Zhejiang University, Hangzhou, China

Background: In general, unpredictable graft retention (26% to 83%) is a critical disadvantage, especially for aged recipients. The supplementation of adipose-derived stromal cells can improve residual volume in young recipients; however, its efficacy on aged recipients remains unclear.

Objective: This study used the aged murine model to examine the effects of supplemented aged and young adipose-derived stromal cells in graft retention.

Methods: Adipose-derived stromal cells from aged and young donors were characterized by detecting the β -galactosidase activity and p16/INK4A marker. Aged, young, and no adipose-derived stromal cell (ASC) groups (n = 6/group) received 150 μ L of green fluorescent protein fat mixed with 3×10^5 aged, young, or none DsRed adipose-derived stromal cells on the scalp, respectively. Graft volumes were evaluated using micro-computed tomography. The vessel density and fates of stromal cells and fat were tracked using immunofluorescent staining.

Results: The young ASC group showed higher cell proliferation ($p = 0.03$) and lower β -galactosidase activity than the aged ($p = 0.002$). The volume retention of grafted fat in the young ASC group was significantly higher than that in the 'no ASC' and 'aged ASC' groups ($p < 0.001$, $p = 0.002$, respectively; median: no ASC group = 41.03%, aged ASC group = 52.15%, young ASC group = 65.21%). Aged and young ASC groups showed significantly higher vascular density than that of the no ASC group ($p = 0.006$ and $p < 0.001$, respectively).

Conclusion: Regardless of the donor age of stromal cells, compared with conventional fat grafts, improved fat graft retention was observed in fat grafts enriched with adipose-derived stromal cells in aged mice. Better graft retention was achieved when supplementation was performed using young adipose-derived stromal cells. However, further validation using larger animal models is required.

R36

Adipose-Derived Stem Cell Injections to Improve Outcomes of Facial Fat Grafting: A Retrospective Study of 100 Patients

Amani Landoulsi Helal^{1,2,3,4,5,6}

¹ International Society of plastic Regenerative Surgery

² American Society of Plastic Surgeon

³ International Society of Aesthetic Plastic Surgery

⁴ Société Française de Chirurgie Plastique Reconstructrice et Esthétique

⁵ Emirates Plastic Surgery Society

⁶ Arab Association of Surgical and Medical Aesthetic

Background: Facial aging is a multifaceted process involving changes to the facial skeleton, soft tissue atrophy, sunken eyes, and long-standing skin alterations. Aging, being dynamic, can be modeled, and fat grafting offers a method to rejuvenate and transform tissues. Initial attempts at facial fat grafting aimed not only to restore fullness but also to enhance tissue quality, including scar improvements. Introducing stem cell injections post-fat grafting presents a potential advancement for optimal results.

Method: Since 2017, a retrospective review of 100 cases (77 females and 23 males) over four years was conducted to evaluate a novel approach combining standard fat grafting with adipose-derived stem cell (ASC) injections. Fifty patients received individualized ASC corrections following the fat grafting procedure. These corrections were administered at 1, 3, 6, and 9 months post-surgery, with the dosage tailored to the recipient site and desired effect.

Results: Follow-up durations ranged from 12 to 48 months. Satisfactory outcomes were noted in 96% of cases. Typical cases were reviewed, showcasing significant improvements in facial volume and skin quality.

Conclusion:

The present study provides the anatomical and clinical basis for the concept of compartmentally based fat grafting. It allows for the restoration of facial fat volume close to the physiologic state. ASC is the best guaranty to get the result that you need. With this procedure, a non-surgical face lift with natural and youthful facial contour could be rebuilt with a high satisfaction rate.

Keywords: Fat grafting, adipose-derived stem cells, face rejuvenation, stem cell injections, facial aging, soft tissue atrophy, facial volume restoration, non-surgical facelift, skin improvement.

Oral Presentation | Free paper (Fat for the breast 1)

R37

Transformative Role of Autologous Fat Grafting in Breast Reconstruction: A Case Report

Amani Landoulsi Helal^{1,2,3,4,5,6}

¹ International Society of plastic Regenerative Surgery

² American Society of Plastic Surgeon

³ International Society of Aesthetic Plastic Surgery

⁴ Soci  t   Francaise de Chirurgie Plastique Reconstructrice et Esthetique

⁵ Emirates Plastic Surgery Society

⁶ Arab Association of Surgical and Medical Aesthetic

Purpose: To illustrate the significant impact of autologous fat grafting in breast reconstruction through a detailed case report, demonstrating how this technique can overcome complications and enhance patient outcomes in complex surgical scenarios.

Case Presentation: This report examines the case of a 53-year-old female with a history of high-grade ductal carcinoma (T3 N0 M0) in the left breast. She underwent a skin-sparing mastectomy with areola preservation and a prophylactic mastectomy of the right breast, followed by bilateral implant-based reconstruction. Post-surgery, the patient received chemotherapy and radiotherapy at Cologne University Hospital. In March 2020, she experienced bilateral implant rupture. Implant replacement in June 2020 led to complications, including infection and exposure of the left implant.

Challenges: By November 2020, the patient presented with chronic infection, fistula formation, radiodermis, nipple deformity, and multiple retracted scars. Given her history of radiotherapy and infection, she was considered a poor candidate for traditional reconstructive techniques. Additionally, she refused to undergo any free flap surgeries.

Intervention and Outcome: Autologous fat grafting was employed to address these complications. This technique improved tissue quality and volume, revitalizing irradiated tissues and enhancing aesthetic outcomes. The intervention successfully resolved chronic infections, reduced scarring, and corrected deformities. The patient's satisfaction with the aesthetic results was significantly improved, demonstrating the efficacy of fat grafting in complex cases.

Conclusion: This case highlights the transformative role of autologous fat grafting in breast reconstruction, particularly for patients with challenging surgical and oncological histories. Fat grafting not only offers a less invasive alternative but also addresses complications effectively, improving tissue health and aesthetic outcomes. This case underscores the importance of considering fat grafting in reconstructive surgery to enhance patient satisfaction and quality of life.

Keywords: Fat grafting, Breast reconstruction, Irradiated breast, Autologous reconstruction, Case report, Chronic infection, Aesthetic outcomes

This abstract demonstrates how a specific case can illustrate the broader importance of autologous fat grafting in breast reconstruction, emphasizing its benefits in resolving complications and enhancing patient outcomes.

Oral Presentation | Sydney Coleman award session

R38

Metabolic Control in Adipose-Derived Stem Cell Modulation of Dendritic Cell Maturation via Notch Activation Pathway

YU CHI WANG, Yur Ren Kuo, Rong Fu Chen

Division of Plastic & Reconstructive Surgery, Department of Surgery, Kaohsiung Medical University Hospital

Background:

Adipose-derived stem cells (ASCs) are considered as potential immunomodulators and could prolong the survival of vascularized composite allotransplantation (VCA). Matured dendritic cells (DCs) present the alloantigen to effector T cells and induce the immune rejection or inflammation. Studies showed that Notch pathway and metabolic control are crucial in modulating DC maturation and function.

Objective:

To investigate the roles of Notch and metabolic control in ASC-modulated and tolerogenic DCs, respectively, to develop strategies for improving VCA survival.

Methods:

ASCs, myeloid DCs, and CD4⁺ T cells were isolated from Lewis rats. DCs were co-cultured with ASCs to assess suppressive effects, and Notch signaling was blocked using DAPT. DC maturation markers, Notch1, Jagged1, IDO expression, PI3K/Akt/mTOR pathway, and cytokine levels were analyzed via flow cytometry, PCR, Western blotting, immunofluorescence, and ELISA. Myeloid DCs were treated with LPS, Vit.D3, dexamethasone, 2-DG, and metformin. Metabolic status was assessed using Mito stress tests on a Seahorse XFe Analyzer.

Results:

ASC-treated DCs showed high Notch1 and Jagged1 expression, reduced maturation markers, increased TGF- β , IL10 levels, and suppressed IFN- γ . Notch inhibition by DAPT reversed these effects. ASC-pretreated DCs induced Treg cell expansion, reversed by DAPT. Tolerogenic DCs and 2-DG-treated DCs had high ATP content and respiration activity. PI3K, p-AKT, and mTOR expressions were upregulated in tolerogenic DCs and 2-DG-treated DCs but suppressed in metformin-treated DCs.

Conclusion:

ASC modulation of DC maturation via Notch1 pathway and metabolic control through PI3K/Akt/mTOR signaling represent potential strategies for immune modulation to enhance VCA survival. These findings could inform future therapeutic approaches in transplantation immunology.

Oral Presentation | Free paper (Research)

R39

Possibility of using AI deep learning to assist in the diagnosis of vascular and pigmentary disorders

KOJI NISHIHORI¹, MAI NISHIHORI¹, DAISUKE OMOTO¹, TORU TANAKA²

¹ NISHIHORI PLASTIC SURGERY CLINIC

² MIRAIZU MEDICAL Co., Ltd.

[Objective] Build a diagnostic AI for bruises, age spots, etc.

[Method] Images taken at our hospital between 2013 and 2023 that were diagnosed as vascular diseases (red bruises) and pigmentary diseases (blue bruises) were extracted. Images were randomly extracted and trained using the names of diagnoses given by doctors in the past as training data.

As a model for distinguishing and recognizing bruises, (1) a cropping model for object recognition and (2) a long-distance image model for object detection were constructed, and a model for distinguishing and detecting bruise types was processed.

(1) Images were manually cropped to create images limited to the affected area, and each image was labeled, and the images and symptom name labels were combined and trained using Microsoft Azure. (2) The long-distance image model was also trained in the same way as .

[Result] We confirmed whether AI can perform image diagnosis and consider the number of treatments for vascular diseases (infantile hemangiomas).

In addition, we found that AI can classify melanin-related diseases (spots such as ectopic Mongolian spots and senile lentigo).

Oral Presentation | Free paper (Face)

R40

Synergy of facial aesthetic surgery with fat transfer maximizing facial beauty

Smilja Tudjarova Gjorgova¹, Igor Peev¹, Tomislav Jovanovski¹,
Nina Karadjinova², Gloria Gjorgova²

¹ Uni_Clinic for Plastic and Reconstructive Surgery, Medical Faculty -Skopje

² Akus Medikus, blvd.11 Oktomvri 86/3/1-Skopje

Background: Synergy of facial fat transfer with eyelid surgery, cheiloplasty, chin, rhinoplasty, harmoniously aligned facial symmetry and beauty. This innovative method involves own fat to enhance facial volume, long lasting effects and diminish the appearance of wrinkles, natural and enduring approach.

Objectives:

Deflation of the faces associated with aging can be restore with fat cells – lipofilling to the malar, nasojugal and tear trough deformity reestablished attractiveness of the face.

Methods:

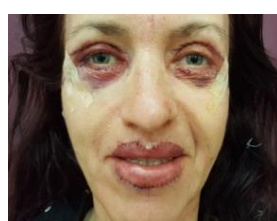
Some of classic aesthetic surgical procedure of the face: blepharoplasty, rhinoplasty, cheiloplasty, chin fullness were combined with lipofilling procedure. Key areas for facial fat transfer are: hollows under the eyes, cheeks, jawline, lips, chin, and cleavage.

Results: From May 2022-May 2024, we performed 134 aesthetic face procedure: 51(38,1%) rhinoplasty, 73(54,5%) blepharoplasty, 10(7,5%) cheiloplasty, Face-neck lipofilling: 16(11,9%) chin lipofilling, 114(85,1%) cheeks, nasolabial, under eye hollow and jawline lipofilling, 4(2,9%) cleavage lipofilling.

Overcorrection was performed with awareness that will be some volume loss over a period of time. Post –operatively, patients were followed-up, 2 weeks and 6 month. They were asked to rate their level of satisfaction using “Five-point” score (1-poor, 2-fair, 3-good, 4-very good, and 5-excellent).

Conclusion:

The benefits of combined approach are amplified results, extended longevity, natural appearance, enhanced skin texture. Facial fat transfer is highly regarded procedure in cosmetic surgery, significant benefits that contribute to its popularity and effectiveness.



Oral Presentation | Free paper (Research)

R41**AI-Driven Age Estimation for Evaluating Non-Surgical Facial Rejuvenation Techniques**

Khaled Alameddine, Karim Bakri

Mayo Clinic, Division of Plastic Surgery, Rochester, MN. USA

Background: Our study introduces an innovative AI model designed to estimate perceived age from facial characteristics, aiming to enhance the evaluation of non-invasive procedures.

Objective: To accurately assess the impact of non-surgical facial rejuvenation techniques on perceived age, facilitating the customization of treatments to each patient's unique facial aging profile.


Methods: Employing a deep convolutional neural network (DCNN), we initially trained the model on the extensive ImageNet dataset and further refined with 523,051 pre-annotated facial images. The Xception architecture was selected for its superior feature extraction capabilities. This model was further refined and tested on a set of 10,000 patient faces from the Mayo Clinic's database. Regression analysis and softmax probability were utilized for precise age estimation (Agbo-Ajala et al., 2022).

Results: The AI model demonstrated a high accuracy rate of 91.8% in estimating the perceived age of patients prior to non-surgical treatments, with a standard deviation of 4.3 years. Post-treatment, the AI model identified an average perceived age reduction of 6.8 years across all patients, with significant variation among different non-surgical techniques. Treatments such as dermal fillers and Botox showed the most pronounced age-reduction effects. Heat maps were utilized to identify specific facial regions that contributed most to the AI's age predictions, showing a strong correlation between these regions and the areas targeted by non-surgical treatments.

Conclusion: By leveraging advanced AI technology to refine aesthetic treatment evaluation, this study underscores the potential for personalized non-surgical interventions, contributing to the advancement of patient-specific rejuvenation strategies in the field of aesthetic medicine

References

Agbo-Ajala O, Viriri S, Oloko-Oba M, Ekundayo O, Heymann R. Apparent age prediction from faces: A survey of modern approaches. *Front Big Data*. 2022 Oct 26;5:1025806. doi: 10.3389/fdata.2022.1025806. PMID: 36387012; PMCID: PMC9644213.
<https://pubmed.ncbi.nlm.nih.gov/36387012/>.



Oral Presentation | Free paper (Face)

R44

Facial liposuction and contouring with CT scan

HANJEONG LEE

ATOP Plastic Surgery Clinic

Background: Recently, there is an increasing number of procedures that facial contouring surgery to improve shape of the face. It is difficult to apply a bone surgery for the contour of the face line because return to daily life is delayed by long lasting swelling and hematoma. Therefore, I think that the satisfaction of the result can be improved by considering minimal invasive facial liposuction and fat graft with aspirated fat in same operation field. In addition, checking the thickness of soft tissue using CT scan is helpful in producing good results.

Methods: To create a V-shaped facial line, the front and side effects are important. In front view, to reduce the facial width, the volume of the subcutaneous fat layer and buccal fat must be reduced, and the volume of the masseter muscle in the mandibular angle area must be reduced. In side view, the volume of the submental area called the double chin must be reduced and the subcutaneous fat layer below the mandible borderline must be reduced to sharpen the jaw line and make the face look smaller.

Results: The facial width was reduced by suctioning of fat from the cheek area and reducing the masseter volume through Botulinum toxin, and the neck line was improved by suctioning of fat from the submental area.

Conclusion: Facial liposuction helps with facial contouring. In addition, by performing a CT scan before surgery, the results and satisfaction can be improved by accurately identifying the area to be suctioned.

Oral Presentation | Free paper (Fat for reconstruction/ regeneration 1)

R45

Cryopreservation of Adipose tissue: Changing the paradigm of regenerative medicine

Olivier Amar, Ahsan Khan

Uvence and private practice

Adipose tissue cryopreservation has gained interest since the discovery of mesenchymal stem cells in 2001. In 2013, a new method for processing and injecting adipose tissue was introduced by Alexis Verpaele & co, involving emulsification and filtration to obtain Nanofat, a regenerative cell-rich fluid product compatible with small needles for injection.

Through a fruitful collaboration with the Uvence team, we have developed a process to harvest, purify, and cryopreserve adipose tissue from patients. This has resulted in a remarkably high recovery rate of viable nucleated cells per cc of emulsified fat, containing a majority of regenerative cells and a high viability.

Our team has meticulously validated a cutting-edge cryopreservation and thawing method for adipose tissue. After rigorous testing of various cryoprotective agents, the most suitable one is carefully selected for the cooling process. Different storage temperatures are compared, and the thawing method is thoroughly validated to safely remove any potentially toxic cryoprotective agents.

We have leveraged cryopreservation of adipose tissue to make regenerative medicine accessible to all doctors. Studies on our cryopreservation process indicate that the adipose tissue's volume recovery post-thawing was an impressive 99.8%, and post-emulsification was 91.8%. The recovery of regenerative cells was 91.8%, with cell viability of 85%, and these will be presented at the congress.

Oral Presentation | ISPRES APRAS award session 2

R46

Extensive scar reconstruction with fat grafting and microcoring technology.

Ki tae Kim

TAE plastic surgery clinic

Reconstructing large scars from various causes takes a lot of work. Different methods have been tried, including subcision, rigotomy, and other methods for large depressed scars. To repair depressed scars, sophisticated fat grafting is an essential surgical procedure and can give good results. I want to introduce you to a new technique called microcoring, which can be used with traditional surgical methods to achieve good results with a quick recovery period.

Unlike many lasers and energy-based devices, microcoring devices can mechanically remove scar tissue without thermal energy. Unlike other methods of scar treatment, microcoring technology can mechanically remove hard scar tissue to achieve much faster scar improvement and soften the subcutaneous tissues mechanically held in place by the scar tissue. This process can be used as an alternative or complement to conventional ablative procedures. This vertical removal process, in combination with the usual horizontal subcision process, can result in a much smoother scar. Therefore, it can facilitate simultaneous fat grafting and increase the fat survival rate. It is expected that the scar removal procedure using these microcores and the simultaneous fat grafting procedure will be able to treat large depressed scars effectively.

Oral Presentation | Free paper (Body contouring)

R47

Autologous Fat Transfer with PRP for Penile Augmentation: A Safe and Effective Procedure Performed Under Local Anesthesia

Timothy Neavin

Beverly Hills

Background: Historically, there have not been many safe, effective, and predictable methods to enlarge the penis. Fat transfer to the penis with platelet rich plasma has been performed by this author under local anesthesia in over 40 men since 2016. The technique, after care, and complications are addressed.

Objective: The goal of this presentation is to describe the technique of fat transfer with PRP, identify suitable candidates, how to deal with patient expectations, and how to address potential complications.

Methods: The last 40 patients have been evaluated for subjective, photo documented for penile size increases, and complications related to the surgery, as well as aesthetic changes.

Results: Over 90 percent of men (92.5%) were satisfied with respect to their size increase. The revision rate was 27.5 percent, there were 2 infections, and 4 cases of visible nodularity that required intervention.

Conclusion: Fat transfer to the penis is a safe, effective, and predictable method to enlarge the penis. However, post operative care can be time consuming in patients when complications arise.

Oral Presentation | Free paper (Fat for the breast 1)

R48

Exploration of Injection Levels for Autologous Fat Transplantation Breast Augmentation Surgery

Chengsheng Liu

Beijing JingmeiMedical Beauty Clinic, China

Background: To ensure the effectiveness of over 5000 cases of autologous fat grafting breast augmentation, a very important factor is the detailed control of fat particles at the injection level in the breast.

Objective: To achieve better results and fewer complications in autologous fat grafting breast augmentation surgery.

Method: Precise injection and filling of fat particles in the subcutaneous layer, superficial fascia layer, deep superficial fascia layer, muscle layer, and lower muscle layer of the breast, in order to maximize the survival of injected and , transplanted fat particles, prevent the accumulation of fat particles, avoid fat necrosis, and reduce the occurrence of complications such as fat lumps.

Results: Nearly 4800 cases showed good results, with no visible or palpable nodules or masses, and a small number of cases had nodules with an average diameter of less than 5 mm visible on ultrasound.

Conclusion: Accurate and detailed control of autologous fat injection at the breast injection level is a key factor for the success of fat transplantation breast augmentation.

Oral Presentation | Free paper (Aesthetic surgical procedures)

A03

How to treat the ipsilateral sunken chest in augmentation mammoplasty

Jinho Lee

AB Plastic Surgery Clinic, Seoul, Korea

Background: Breast asymmetry is a common concern for many women and augmentation mammoplasty is a useful option. One important thing in fixing uneven breast is the consideration of underlying chest wall contour. Anterior thoracic hypoplasia (ATH) refers to ipsilateral sunken chest with breast hypoplasia and subsequent asymmetry. Since there is no pectoralis muscle involvement, it is speculated as a separate entity from Poland syndrome by Spear. It is also different from pectus excavatum in its chest wall shape. ATH is not a rare condition and various degree of ATH patients undergo augmentation mammoplasty.

Objective: The purpose of this presentation is to share clinical experiences and set-up some guidelines.

Methods: A retrospective chart review of patients between 2020 and 2024 was performed.

Results: Twelve patients underwent augmentation mammoplasty with correction of breast asymmetry, which condition assessed as ATH. In all cases, ATH occurred in the right side of the chest. Dual-plane breast augmentation technique using smooth round implant was performed in all cases. One patient developed postoperative implant malposition and had revisional mammoplasty with implant exchange, capsulotomy and capsulorrhaphy. The remaining 11 patients had favorable outcomes with smooth recovery.

Conclusion: Considering my unfavorable case, the author recommend to practice as follows: 1) to analyze the chest CT preoperatively 2) to consider microtexture implant rather than pure smooth implant 3) Extremely conservative medial dissection of Rt. Breast with at least 2.5cm safety margin from the midline 4) postoperative surgical bra up to 6 months 5) to consider wider diameter implant on Rt. Breast for lateral breast balancing.

Oral Presentation | TAAT APRAS award session 2

A04

Challenges in primary rhinoplasty with autologous dorsal grafts: Comparison of homogenous grafts and hybrid autologous grafts

Jinho Lee

AB Plastic Surgery Clinic, Seoul, Korea

Background: Dorsal augmentation is important in Asian rhinoplasty. Apart from secondary cases, silicone implant is most preferred option in Asian rhinoplasty. It is generally regarded as superior to dorsal autologous grafts in aspects of aesthetic results such as longevity of dorsal height and lateral profile. Convenience in shaping and high predictability are definite advantages.

However, in certain indications, autologous materials are literally enough to make balanced and aesthetically-pleasing nose. Patient perspective has changed that increasing numbers are seeking for autologous costal cartilage in primary cases recently. Via the incision for costal cartilage, soft tissues including fascia, dermis, fat, perichondrium can be harvested and used simultaneously. With more autologous graft sources, hybrid dorsal augmentation is globally tried these days.

Objective: Gains in safety and psychologic well-being after using solely autologous grafts are obvious. This study aimed to access the effect of heterogeneity in autologous dorsal grafts, focusing on minimizing the drawbacks.

Methods: Retrospective chart review of patients underwent primary rhinoplasty with autologous tissues between Jun 2019 and Apr 2024 was performed. Overall outcomes including revision rates were analyzed.

Results: 298 patients presenting to a single surgeon were analyzed. (Table 1) With homogenous autologous grafts, 25 out of 178 patients underwent revision. (14.0%) With hybrid autologous grafts, 11 out of 120 patients underwent revision. (9.2%), showing lower than the former.

Conclusion: Surgical indication is a crucial step and it's necessary to align the expectations of patients with doctor's preoperatively. Recruiting proper graft sources are required for the aesthetic balance between hard and soft tissue and minimizing complications.

Oral Presentation | TAAT Best paper session

A06

Plasma Radiofrequency-assisted Microliposuction for the Treatment of Facial Overfilled Syndrome Induced by Various Causes in Asians

MING NI

Jiangshu SIRRIM Plastic Surgery and Beauty Hospital

Background: In Asia, facial overfilled syndrome (FOS) can arise from iatrogenic causes involving excessive use of filling materials , as well as physiological causes such as fat hypertrophy, cavity type, and aging.

Objective: This study aimed to demonstrate the safety and effectiveness of Plasma Radiofrequency-assisted Microliposuction (PRFAML) in improving the appearance of FOS induced by various causes.

Methods: PRFAML was performed on 84 anatomic regions of 37 female patients (including 12 with physiological causes, 6 with HA causes, and 19 with fat causes) , aged between 20 to 50 years (mean 35.9 years), who had FOS. Demographic and surgical data were collected retrospectively. Preoperative and postoperative photographs were taken, and satisfaction interviews were conducted at least six months after surgery.

Results: All patients underwent the operation successfully under local or intravenous anesthesia. Only four anatomic regions showed noticeable asymmetry post-surgery requiring a secondary operation. Postoperative skin numbness, muscle paralysis, bruising, and minor contouring irregularities significantly improved within two to three weeks of recovery. Additionally, five patients with longer edema periods demonstrated substantial improvement after more than five weeks. No cases of skin necrosis ,thermal injury or other serious complications related to the study device or procedure were reported. Ultimately, all patients expressed satisfaction with their outcomes.

Conclusion: The PRFAML technique is a safe and effective method for treating FOS induced by various causes while minimizing complications and ensuring high patient satisfaction.

Oral Presentation | Free paper (Aesthetic surgical procedures)

A07

Abdominoplasty in the Low BMI Asian Patients

XIN CUI

Xi'an International Medical Center Hospital

Background: Patients with low body mass index (BMI) are always accompanied with thin abdominal subcutaneous fat and flat or protrude umbilical stem.

Objective: The purpose of this study is twofold: Expanding the dissection range of the skin flap to enhance its plasticity and mobility, meanwhile creating a new umbilicoplasty to get a deep esthetically shaped navel.

Methods: 168 patients ($16.66\text{kg/m}^2 \leq \text{BMI} \leq 20\text{kg/m}^2$) were performed abdominoplasty.

Liposuction is performed, especially on bilateral waist and the upper lateral region of the buttocks. The level of flap dissection extends to the external borders of the bilateral rectus abdominis muscles. “8” approach and corium fat junction suture (CFJ) was performed in umbilicoplasty after repairing the diastasis recti. Finally, modified fully buried progressive tension reduction suture was performed on the wound.

Results: The average excised skin size of 168 patients was $30.88 \pm 7.82\text{cm} \times 27.59 \pm 6.39\text{cm}$.

Complications occurred in 19 patients: One case of local skin flap infection, two umbilical skin necrosis, three cases of wound healing problem, six cases of unilateral or bilateral dog ear formation, three hypertrophic scars, four cases of small seroma and one case of subcutaneous hematoma. There were no severe complications, such as deep-vein thrombosis, fat embolism, skin flap necrosis, large hematoma or seroma.

Conclusion: Abdominoplasty based on personal improvements is more suitable for low BMI Asian patients which can retain intense abdomen, smooth waist-hip curveline and deep vertical navel with fewer complications.

Oral Presentation | Free paper (Aesthetic surgical procedures)

A08

Exploration of Visual Sculpture-Abdominal Sculpture of Chinese People

CHAO XIE

Hunan Prevention and Treatment Institute for Occupational Diseases

Background: More and more abdominal liposculpture surgeries are being performed in China, and conventional liposculpture methods under blind vision for shaping the abdominal muscles may lead to unevenness, stiff abdominal muscles lines that do not conform to the contour of the human body's own muscles, excessive bleeding, and serum swelling, resulting in many secondary repairs operation. In order to avoid or exercise the above-mentioned problems, ultrasound guided visual liposculpture technology can be used to shape Chinese abdominal muscles.

Objective: To propose the concept of visualized liposculpture and explore the effect of applying ultrasound guided technology to shape the abdominal muscles.

Methods: Preoperative ultrasound measurement of abdominal fat thickness, marking of muscle boundaries in the abdominal liposuction area, ultrasound guided visualization of injection of swelling fluid, ultrasound assisted emulsification of fat, and dynamic assisted liposuction, clearly demonstrating the anatomical shape of the abdominal muscles.

Results: Ultrasound-guided visualization technique was used to perform abdominal liposculpture on 124 patients, and postoperative exposure of the abdominal muscle was satisfactory. No serious complications such as burns, skin necrosis occurred. And under ultrasound guidance, two postoperative complication of seroma was treated.

Conclusion: The application of ultrasound guided visual liposculpture is safer, more accurate, and has a higher satisfaction rate compared to traditional blind liposculpture applied to the shaping of abdominal muscles in Chinese.

Oral Presentation | Free paper (Aesthetic surgical procedures)

A09

Safe and Effective Injection for Treating Pouches

YANLING WEN

Dr.Cui Boshi Li Medical Aesthetic Clinic, Yinchuan

Background: The current treatment for eye bags is mainly surgical, with bruising, swelling and a recovery period. With the change in modern lifestyles, candidates prefer minimally or non-invasive treatment, and being able to wash their face and put on make-up in 6 hours is what candidates are looking for. In the past, it was widely believed that pouches under the eyes formed due to herniation of orbital fat and surgery was the treatment of choice. After literature tracing and cadaveric dissection, it was found that there is almost no ligamentous laxity in the deeper parts. The superficial dermal ligaments show significant laxity and sagging due to factors such as compression of facial expression and age, and the ligamentous laxity in the deeper parts originates from loss of bony structural volume. The simultaneous modification of tiny anatomical subunits and tightening of the skin through injections can be effective in treating under-eye bags as well as depressions and unevenness in the infraorbital region.

Objective: Exploring the clinical application of injections in the treatment of pouches.

Methods: All patients were treated with injections to address the bags under the eyes.

Results: The combined injection method of hyaluronic acid and nutrient solution was used to treat pouches in 1000 patients, with no complications except for severe local redness and swelling in two cases.

Conclusion: The injection method of treating pouches is a safe and ideal method of rejuvenating the infraorbital region.

A10

Treatment Strategies for Post-Facial Fat Grafting Deformities

LINA LIU

Shanghai Basilica Clinic

Background: Facial fat grafting solves issues like facial depressions and aging, but it can also introduce new complications such as various post-procedure deformities.

Objective: This study explores different treatment strategies for these post-facial fat grafting deformities.

Methods: Post-facial fat grafting deformities can be broadly categorized into four types: 1. Overfilled facial regions; 2. Irregularities and unevenness post-filling; 3. Increased sagging and slackness post-filling; 4. Deformities in specific areas post-filling. Treatment strategies are tailored to each deformity: 1. Overfilling is generally corrected by liposuction; 2. Unevenness is improved through liposuction and localized fat transplantation; 3. Sagging and slackness are addressed with a combination of suction and radiofrequency, or suction coupled with thread lifting; 4. Specific areas like the tear trough or chin overfilled are managed with suction combined with fiber laser lipolysis.

Results: Follow-ups from 3 to 12 months post-surgery showed that patients experiencing deformities post-filling observed varying degrees of improvement in facial contours through the aforementioned treatments, with high satisfaction rates regarding the outcomes.

Conclusion: Different surgical strategies tailored to specific post-facial fat grafting deformities can effectively improve outcomes.

A12

The Application of Light-Shadow Aesthetics in Cosmetic Injections

YINAN ZHOU

The Medical School of Guangzhou

Background: There are some limitations in the traditional methods of facial assessment when it comes to cosmetic injections. Therefore, light-shadow detection is an useful complement for facial aesthetic problems that cannot be found by traditional examination methods. Moreover, light-shadow aesthetics is a tool to simulate the aesthetic expression of patients under various light sources in their daily work and life. Through the evaluation of light and shadow in the process of face consultation, a better communication and consensus can be achieved with doctors and patients. The level of satisfaction was considerably high in either postoperatively or long-term follow-up in patients concern.

Objective: To explore the application of light-shadow aesthetics in cosmetic injections, especially in Asian facial rejuvenation and facial contour remodeling.

Methods: Multiple light sources were used to detect the facial defects of patients, which later were adjusted by cosmetic injections. After adjustment, the results were scored by GAIS scale.

Results: The application of light-shadow aesthetics in the cosmetic injection operation can comprehensively improve the satisfaction of all patients after operation, and no obvious complication was discovered.

Conclusion: The application of light-shadow aesthetics is an efficient method in cosmetic injections.

Keywords: light-shadow, injection, facial rejuvenation.

Oral Presentation | Free paper (Non-surgery)

A13

Application of Collagen Combined with Botulinum Toxin in the Treatment of Periorbital Aging

SHUAIHUA LI

Hunan Liyang Medical Cosmetic Hospital

Background: Periorbital aging in the face is a common problem in older women. Procedures using collagen or botulinum toxin has some benefits in the treatment of periorbital aging.

However, there are few reports on the combination of the two treatments.

Objective: To investigate the efficacy, safety and tolerability of the combination of collagen and botulinum toxin in the treatment of periorbital aging.

Methods: 21 patients with periorbital aging and relaxation were treated with collagen injection and botulinum toxin type A injection in a single-center, self-controlled before and after study method. The efficacy and safety of collagen combined with botulinum toxin in the treatment of periorbital aging were compared based on the Grading assessment of periorbital aging and detection results of VISIA.

Results: All patients were followed up for 1 month, 3 months and 6 months, the effect of filling and slightly lifting was achieved immediately after injection, and the effect of tightening and lifting was obviously achieved after 1 month, the effect maintained after 3 months, the effect weakened after 6 months.

Conclusion: The combination of collagen injection and botulinum toxin A injection is effective in treating the patients with periorbital aging and relaxation, without obvious swelling and bruising, which is worth popularizing.

A14

Efficacy of early intervention using pulsed dye laser (PDL) for traumatic or postoperative scars improvement in Asian patients

Chang Cheng Chang¹, Han Yuan Chng²

¹ China medical university hospital

² Chang Gung memorial hospital

Background: Post-injury or -treatment is usually sought for symptom relief and alleviating cosmetic concerns. A pulsed dye laser (PDL, 585–595 nm) is commonly applied to such treatments alone or combined with ablative fractional CO₂ laser. However, laser initiation has no consensus.

Objective: This study was to evaluate the efficacy of early intervention using PDL for traumatic or postoperative scars improvement.

Methods: This retrospective study enrolled 70 patients in Asia with traumatic or post-operative scars who had received PDL treatment only or combination with an ablative fractional laser. The Vancouver scar scale (VSS) and the Manchester scar scale (MSS) were used before and after laser treatment with photo evaluation by two independent dermatologists. The patient and observer scar assessment scale and customer satisfaction index were collected.

Results: Among the 70 patients, 43 were successfully treated for at least 3 sessions with good outcomes. The correlation coefficients between week-to-treatment initiation and post-treatment MSS and VSS were 0.50 ($p < 0.001$) and 0.46 ($p = 0.002$), respectively. Using ≤ 10 weeks as the definition of early treatment, 22 and 21 patients were included in the early and late treatment groups, respectively. The early treatment group showed borderline significantly lower post-treatment MSS and VSS scores than the late treatment group (MSS: 7.5 ± 2.1 vs. 9.3 ± 2.5 , $p=0.011$; VSS: 2.8 ± 2.0 vs. 4.5 ± 2.3 , $p=0.011$). Furthermore, the early treatment group showed significantly greater improvement in both MSS and VSS post treatment (4.4 ± 1.6 vs. 3.2 ± 1.9 ; $p = 0.03$, and 3.8 ± 1.8 vs. 2.8 ± 1.4 ; $p=0.04$).

Conclusion: Early intervention using a PDL within 10 weeks of the injury achieved better outcomes in treating traumatic and postoperative scars based on both clinical and patient opinions.

A15

Factors Influencing Early Postoperative Swelling After Ptosis Surgery

Hiroko Ochiai¹, Aiko Oka¹, Shiho Watanabe¹, Mayuka Uchida¹, Rieko Shimizu²

¹ NHO Tokyo Medical Center, Department of Plastic and Reconstructive Surgery

² Keio University, Department of Plastic and Reconstructive Surgery

Background: Postoperative eyelid swelling is a primary concern for patients after ptosis surgery, significantly affecting their quality of life.

Objective: To identify the main factors influencing early postoperative swelling in patients undergoing bilateral ptosis surgery.

Methods: The study included 105 patients who underwent bilateral ptosis surgery between April 2020 and December 2022. Eyelid photos before surgery and on day 7 post-operation were analyzed by two non-operating plastic surgeons to evaluate swelling. Factors such as age, gender, underlying diseases, surgery duration, amount of skin removed, anterior displacement, intraoperative blood pressure, and antithrombotic medication intake were examined.

Results: The sample comprised 30 males and 75 females, with an average age of 72.9 years. Significant swelling was mainly influenced by extensive skin removal, followed by factors like diabetes and aging. Although antithrombotic medication was identified as a risk factor, its impact was not substantial. Factors like the amount of anterior displacement of the tendon and changes in marginal reflex distance (MRD) were not found to affect swelling.

Conclusion: Postoperative swelling is primarily exacerbated by increased vascular permeability due to inflammation, enhanced local blood flow, and microvascular damage, particularly in patients with extensive skin removal or underlying conditions like diabetes and arteriosclerosis. Cooling and compression were not effective in preventing swelling. Guidelines suggest continuing antithrombotic medication during superficial surgeries without needing to stop due to swelling risk. The relationship between the control of underlying diseases, postoperative management, and the extent of swelling requires further investigation.

Oral Presentation | TAAT Best paper session

A17

High Double Eyelid Fold Correction Composite Using Fat Strip Transplantation and Pretarsal Orbicularis Oculi Flap

Haihua Chen

Hangzhou First people's Hospital

Background: As the growing amount of unnatural-appearing upper eyelid after blepharoplasty, it's necessary to find suitable methods for secondary revision.

Objective: This study aimed to evaluate aesthetic outcomes of surgical correction of the high fold using a pretarsal orbicularis oculi flap with fat strip transplantation.

Methods: From January 2018 to September 2023, 50 patients with high and deep double eyelid folds underwent our fold-lowering procedure. All of these patients underwent surgical correction of high folds composite using fat strip transplantation and pretarsal orbicularis oculi flap, with postoperative follow-up ranging from 6 months to 2 years. All the Postoperative outcomes were recorded and reviewed.

Results: Using the composite technique, unnatural, high, and deep double eyelid folds were converted to lower and relative natural folds. Although prior high fold incision scars could be seen postoperatively on close examination, they were not easily visible. Complications included fold height asymmetry in 5 cases, persistence of the prior fold in 6 cases, and redundant upper flap skin that needed further excision in 3 cases.

Conclusion: Secondary blepharoplasty revision to correct the high fold is a challenging procedure for plastic surgeons. Using fat strip transplantation and pretarsal orbicularis oculi flap for correction of the high fold is relatively safe and effective. This provides a new treatment option in secondary revision techniques.

E-poster

A18

Global Interest in Glucagon-like Peptide-1 Agonists for Weight Loss and its Impact on Aesthetic Surgery

Austin Chen, Jorys Jorge-Martinez

Mayo Clinic, Rochester

Background: Glucagon-like peptide-1 (GLP-1) agonists Ozempic (Novo Nordisk, Bagsværd, Denmark), Wegovy (Novo Nordisk), and Mounjaro (Eli Lilly and Company, Indianapolis IN) have become popularized for weight loss in recent years.

Objective: The aim of this study is to assess with Google Trends (Alphabet Inc., Mountain View, CA) the popularity of these weight loss medications worldwide and its impact on public interest in related cosmetic weight loss procedures.

Methods: “Ozempic”, “Wegovy” and “Mounjaro”, along with terms for related aesthetic interventions such as “ozempic face”, “body lift” and “skin tightening” were analyzed with Google Trends across North America, South America, Europe, Asia and Africa, as represented by the most populated countries of each. Changes in relative search volume (RSV) over a 5-year period between the different medications and interventions were analyzed, across the different regions.

Results: There was a statistically significant RSV over time for GLP-1 searches worldwide, with R^2 0.902 and regression coefficient 0.938 ($p < 0.001$). This held true across all geographical locations. Ozempic was significantly more searched than Wegovy and Mounjaro ($p < 0.001$). In regards to weight loss related aesthetic or cosmetic procedures, there was not a statistically significant trend noticed in any across any of the geographic locations, apart from “ozempic face” with R^2 0.897 and regression coefficient 0.922 ($p < 0.001$).

Conclusion: The impact of ozempic is a global phenomenon, and plastic surgeons worldwide need to be prepared to address the subsequent effects. Although searches in weight loss related aesthetic interventions have not yet translated, there may be a time delay effect.

Oral Presentation | Free paper (Aesthetic surgical procedures)

A19

The Experience of Nasal Injection Therapy in 1981 Patients with Combination Materials about HA,PCL,CaHA and Thread

HSINKAI CHEN

Shanghai Gangli Beauty Medical Clinic

Background: Nasal aesthetics always is the commonest facial changes, and nasal plastic surgery is a way to solve the any problems.

Objective: However, due to the progress of biotechnology materials, many materials can be applied, such as HA, PCL, CaHA, collagen, thread, etc.

Methods: Among the combined formulas are HA, PCL, HA + PCL, HA + CaHA, HA + CaHA + thread, HA + PCL + thread. The results and complications are reported about the stratified injection of the combined application materials and the improved injection methods were shared.

Results: Summary of the injection experience of 1981 patients in 2022 to 2023. The common secondary injection problems will be reported and recommended injection methods.

Conclusion: Studies have proved that the combined therapy has less trauma and fewer complications, which is worthy of further clinical promotion and application.

Oral Presentation | TAAT Best paper session

A21

Improvement of visual acuity impairment in Poly-D,L-lactic acid injections by hyperbaric oxygen therapy

Tien-Chun Tsai, Chien-Liang Ho, Shin-Chen Pan

National Cheng Kung University Hospital

Background:

Poly-D,L-lactic acid (PDLLA) is a highly regarded dermal filler known for its biocompatibility, biodegradability, and enduring effects. Severe complications after PDLLA injections are rare.

Objective:

A healthy 38-year-old woman received PDLLA injection in the forehead experienced sudden right eye blurred vision and ptosis. Fluorescein angiography (FAG)/ indocyanine green angiography (ICGA), Optical Coherence Tomography (OCT) confirmed choroid ischemia and disc edema. Contrast brain MRI indicated ocular artery occlusion. MR angiography confirmed the diagnosis of posterior ciliary artery occlusion.

Methods:

Intraocular pressure lowering agents, aspirin, and a 14-session regimen of hyperbaric oxygen therapy (HBOT) was initiated within 24 hours.

A review of cases within 10 years involving visual impairment after facial filler injections treated with HBOT was done. Initial symptoms, injection site, initial visual acuity, treatments, best corrected visual acuity were compared.

Results:

At the two-month follow-up, the patient's ptosis and visual acuity improved from Snellen VA 0.03 to 0.9.

Among reviewed cases, treatments included intraocular pressure-lowering agents, globe massage, antithrombotic alongside HBOT. Only three cases showed improvement, with the best one achieving baseline vision after nine 90-minute daily HBOT sessions.

Conclusion:

Our case emphasized the possible severe adverse effect of PDLLA injection, highlights variable effectiveness of HBOT, and underscores its potential in restoring visual acuity post-PDLLA injection, offering important insights into managing such complications.

A22

Efficacy of 730nm Picosecond Laser on Acquired Dermal Melanocytosis in Asian Women

Kento Takaya^{1,2}

¹ Department of Plastic and Reconstructive Surgery, Keio University School of Medicine

² Etoile Regina Clinic

Background: Acquired dermal melanocytosis (ADM) is a pigmented lesion that occurs frequently in young to middle-aged women. It has been treated with Q-switch ruby laser and 1064 nm picosecond laser, but it is refractory and there is no certain consensus on treatment. We have introduced treatment with the more melanin-selective 730 nm wavelength.

Objective: To compare the efficacy of 730 nm and 1064 nm picosecond lasers.

Methods: Patients treated with picosecond laser (PicoWay, Cineron Candela) for ADM from April 2021 to May 2024 were studied: 730 nm (3 mm spot, 1.7-1.8 J/cm² or 2 mm spot, 2.5-3.25 J/cm²) and 1064 nm (3 mm spot, 3.1-4.0 J/cm²) picosecond laser spot irradiation. Two months after each treatment, patients were evaluated on a 4-point scale using a medical interview, gross findings, and skin analysis software (VISIA, Canfield Scientific). The results of the univariate and multivariate analysis of the factors involved in ADM treatment outcome were analyzed.

Results: 83 patients in the 730 nm group and 78 in the 1064 nm group were treated; after treatments, subjective symptoms, gross findings, and improvement on software analysis were all significantly higher in the 730 nm group, with no difference in the occurrence of pigmentation. The presence or absence of melasma was a factor related to treatment outcome.

Conclusion: The use of the 730 nm picosecond laser, which is highly melanin-selective and reaches relatively deep into the skin, suggests the possibility of effective treatment without increased complications compared to the conventional treatment.

Oral Presentation | Free paper (Non-surgery)

A23

A Cutting-Edge Strategy for Prevention the Severe Complications in Filler Injection and Fat Grafting

Ching-En Chen^{1,2}, TSAI-MING LIN^{1,2}

¹ Kaohsiung Medical University Hospital

² Charming Institute of Aesthetic and Regenerative Surgery

Background: The use of fillers and fat grafting has become increasingly popular in aesthetic and reconstructive surgery. However, these procedures carry risks of severe complications, including intra-vascular injection-induced skin necrosis, blindness, and cerebral vascular accidents. Advanced techniques, such as Micro-Autologous Fat Transplantation (MAFT), have been developed to enhance safety and outcomes.

Objective: To evaluate the effectiveness of MAFT and other advanced strategies in preventing severe complications associated with filler injection and fat grafting.

Methods: A comprehensive review of over 6000 cases using the MAFT technique for fat grafting was conducted. The techniques involved precise control of fat injection, systematic patient evaluation, and meticulous surgical planning. Follow-up evaluations were performed over an average period of three years to assess outcomes and identify any complications.

Results: The implementation of MAFT significantly reduced the incidence of severe complications, such as intra-vascular injection-induced skin necrosis, blindness, and cerebral vascular accidents. The precise control over fat parcel size and injection depth minimized the risk of unintended vascular injections, thereby preventing these catastrophic events. In the extensive series of over 6000 cases, there were no reports of these severe complications, underscoring the safety and efficacy of the technique. Patient satisfaction was high, with maintained results observed over the three-year follow-up period.

Conclusion: The MAFT technique, along with rigorous preoperative and intraoperative strategies, provides a robust approach to minimizing severe complications in filler injection and fat grafting. These advanced methods enhance patient safety, improve aesthetic outcomes, and offer a reliable solution for both aesthetic and reconstructive purposes. The absence of severe complications in over 6000 cases further highlights the safety of this technique. Future advancements in these techniques are anticipated to further refine safety protocols and clinical results.

Oral Presentation | TAAT Best paper session

A24

The Rejuvenating Effect of Fat Grafting: Fiction or Fact

I-Feng Sun¹, Wen-Hui Chen², Tsai-Ming Lin³

¹ Astrid Clinic, Kaohsiung, Taiwan

² Department of Dentistry, Eda hospital, Kaohsiung, Taiwan

³ Charming Institute of Aesthetic and Regenerative Medicine (CIARS), Kaohsiung, Taiwan

Background: Fat grafting has become a prominent technique in aesthetic and reconstructive surgery, particularly for its purported rejuvenating effects. This study aims to evaluate whether these claims hold up under scientific scrutiny by examining the biological mechanisms and clinical outcomes associated with fat grafting.

Objective: To investigate the efficacy of fat grafting in achieving rejuvenation, focusing on the biological basis and clinical evidence supporting its use in aesthetic medicine.

Methods: A review of clinical cases and scientific literature was conducted to assess the outcomes of fat grafting procedures. Emphasis was placed on the role of adipose-derived stem cells (ADSCs) and the stromal vascular fractions (SVFs) in tissue regeneration and rejuvenation. Data from over 6000+ cases of fat grafting procedures were analyzed, with follow-up periods extending up to ten more years.

Results: Fat grafting demonstrated significant rejuvenating effects, including improved skin texture, increased volume with sustainability, and enhanced tissue quality. The regenerative properties of adipose-derived stem cells (ADSCs) and the stromal vascular fractions (SVFs) were confirmed through histological analyses, showing increased collagen production and neovascularization. Patients reported high satisfaction rates, and long-term follow-ups indicated sustained improvements without major complications.

Conclusion: The rejuvenating effect of fat grafting is supported by both clinical outcomes and biological evidence. The integration of ADSCs and SVFs plays a crucial role in the observed benefits, making fat grafting a reliable method for aesthetic rejuvenation. Future research should focus on optimizing techniques to further enhance these effects and explore new applications in regenerative medicine.

Oral Presentation | TAAT APRAS award session 2

A27

Hair Regeneration Using Stem Cell-Conditioned Medium

JUN KARIBE

Kojimachi Dermatology & Plastic Surgery Clinic

Background: Various treatments for hair thinning, such as papule methods, dermarollers, mesotherapy, and mesoguns, have been developed. However, these methods often cause pain and have inconsistent results. This study investigates a new hair treatment method using a needle-free injector to administer stem cell-conditioned medium.

Methods: We measured the hair diameter, hair density, and patient satisfaction of those treated at our clinic. Additionally, we analyzed changes in hair volume and growth patterns according to gender and age.

****Results:**** The needle-free injector treatment caused minimal pain and resulted in high patient satisfaction. It was found to be highly effective for androgenetic alopecia and also beneficial for female pattern hair loss. Typically, treatment for female pattern hair loss requires several months due to the hair follicle cycle and hair growth rate. However, the stem cell-conditioned medium significantly accelerated the growth phase of hair, resulting in early treatment effects.

Conclusion: The hair treatment using a needle-free injector is minimally invasive, can be easily standardized for nurse administration, and is convenient, making it suitable even for patients with needle phobia. Stem cell-derived growth factors are known to possess equal or superior tissue regenerative abilities compared to stem cell transplantation. This study suggests that the induced growth of hair in the anagen phase, increased proliferation of dermal papilla cells and keratinocytes, and enhanced hair follicle growth contributed to the positive outcomes. Hair treatment using stem cell-conditioned medium is considered to lead to increased hair growth, providing significant improvement for patients with frontal hair thinning and moderate to severe vertex alopecia.

A28

Optimizing scarless double chin treatment: Systematic plan through combining surgical, energy based, and manual techniques

Dina M Badawi

Cairo university

Background: The importance of a tightened sculptured neck and submental region is highlighted nowadays in the trending selfie photos. Surgical liposuction of submental fat may address one component of the double chin problem, other components like loose skin and sluggish lymphatic circulation need attention.

Objective: Evaluating the impact of applying manual lymphatic massage and radiofrequency energy to the submental area following surgical liposuction on aesthetic outcome, patient's satisfaction, and safety.

Methods: A prospective study included patients seeking scarless treatment for double chin deformity. Our plan involved three subsequent steps: PAL of submental fat, manual lymphatic massage, and radiofrequency energy. Follow up continued for 6 months. At each visit, photos were taken, complications were recorded, and visual analogue scales were used to evaluate the pain and patient satisfaction.

Results: 42 patients were included, mean age 38.1. Complications reported were edema, pain and transient marginal mandibular nerve paralysis. The pain scores were highest on the first visit. The mean satisfaction score on the final visit was 8.76 (Fig.1). None of the patients asked for further surgical neck lift.

Conclusion: Adding manual lymphatic massage and radiofrequency energy to the submental area in the early post-liposuction period may be considered a satisfactory, simple, reproducible, rapid, and safe plan for scarless neck rejuvenation.

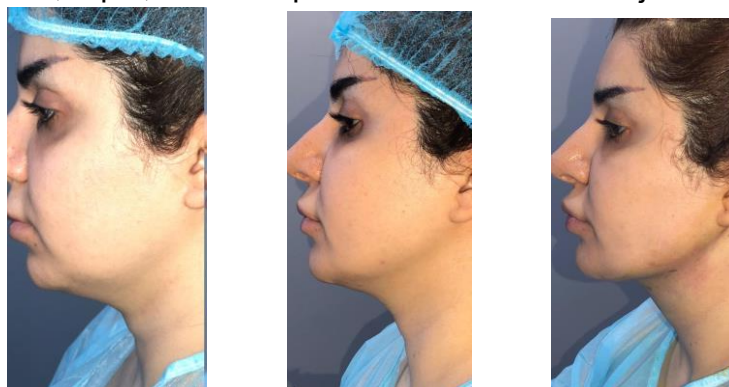


Fig. (1): A: Before liposuction of double chin. B: after performing PAL of submental fat. C: After completion of manual massage and radiofrequency

Oral Presentation | Free paper (Non-surgery)

A29

Peeling Back the Layers: A TikTok Analysis of Chemical Peel Content

Luis Antezana MD, Alexandre Meira Pazelli MD, Cole Holan MD, MBA, Basel Sharaf MD

Division of Plastic and Reconstructive Surgery, Mayo Clinic, Rochester, MN, 55902

Background

Chemical peels have seen a resurgence in popularity, with a fourfold increase in worldwide interest since 2010 based on Google Trends data.

Objective

This study analyzed chemical peel content on TikTok to investigate potential disparities in Fitzpatrick skin types represented, user engagement levels, and information dissemination.

Methods

The top 15 videos were reviewed for 13 popular chemical peel hashtags on TikTok, excluding non-English, unrelated, and duplicate videos. Data extracted included engagement metrics, chemical agents used, content types, and patient experiences. Appropriate statistical tests were conducted.

Results

195 videos were included, totaling nearly 199 million views and over 8 million likes. Full face (91.1%) was the most common treatment area. Phenol (17.4%), salicylic acid (11.3%), and TCA peels (11.3%) were most prevalent. Top treatment indications were pigmentation (24.7%) and acne scars (14.9%).

Patient experiences (35.6%), education (23.7%), and live peeling (23.2%) were the main content types. Less than one-third (31.6%) were by healthcare providers. Among providers, most were MDs (49), followed by DOs (5).

Patient experiences were largely positive (57.8%). The MD+DO subgroup had significantly higher engagement metrics than patients. Fitzpatrick scores >3 vs. <3 differed significantly for phenol peel content, with the <3 group more represented.

Conclusion

This overview of TikTok's chemical peel content reveals potential patient exposure and racial disparities within cosmetic treatment marketing.

Oral Presentation | Free paper (Non-surgery)

A31

An injection method that uses “HA” to improve perioral aging.

Zhao Hui Hui

Shenzhen Yixing Cosmetic Hospital

Background: Traditional anti-aging focuses only on aging around the eyes and sagging of the face, while problems around the mouth are gradually discovered after the eye area.

Objective: To improve the smoothness of the perioral flatness, intramucosal combined subcutaneous injection can be used to minimize pain.

Methods: Through the adjustment of the lip, mandibular angle, jaw line, “ogeen” line, piriform fossa “DMCF” and other structures. “MOV” injection partitions are proposed to track the effect of injections.

Results: According to the specific situation (“MOV” partition adjustment) analysis to adjust different schemes, the results showed that most patients had smooth perioral flatness and better coordination and natural coordination of skin and flesh during orotic orbuli muscle movement after one month after surgery, and had a high level of satisfaction.

Conclusion: Effectively improve the flatness of the perioral mouth, improve the perioral aging, and achieve effective dynamic anti-aging effect.

Keywords: Peroral aging, MOV, HA, Intramucosal injection

An improved injection method for non-painful abobotulinumtoxin A to lift the entire face

Xiang Wang

Hangzhou-Mylike Cosmetic Hospital

Background: In the past, traditional AbobotulinumtoxinA(AboBoNT-A) injection methods for facial lifting, which were used to inject the platysma, failed to achieve the desired lifting effect. Patients experienced significant pain, and the treatment outcomes were unsatisfactory, resulting in low satisfaction rates.

Objective: To achieve rapid and long-lasting facial lifting and clear jawline effects by improving the injection points, concentrations, and injection levels of AboBoNT-A, while reducing patient's pain during the injection process.

Methods: Through dynamic and static assessments, AboBoNT-A was injected into the platysma and other descending muscles, while preserving the lifting muscles. By enhancing the lifting force of the galea aponeurotica and relaxing the tension of the platysma, the facial soft tissues were lifted. The AboBoNT-A (produced by Galderma, 300su, diluted with 3ml of normal saline, with 5su injected at each point) was used, and the treatment outcomes were evaluated one month later.

Results: Most patients achieved good lifting effects, manifesting as a clear jawline, smoother facial contours, lifting of the soft tissues in the mid-to-lower face, reduced fatigue, and changes in face shape. Additionally, 80% of patients experienced a more comfortable injection process and had a high level of satisfaction.

Conclusion: The application of modified painless AboBoNT-A injection techniques for comprehensive facial lifting can achieve better facial lifting effects and reduced pain, significantly improving patient satisfaction.

Keywords: face lifting,Botulinum Toxin,AbobotulinumtoxinA,Non-Painful injection

Oral Presentation | TAAT APRAS award session 2

A33

Preliminary Outcome of Enhancing Transdermal Delivery of Autofluorescence Nanoparticles Assisted of Picosecond Laser and Fractional CO₂ Laser

Chang-Cheng Chang^{1,2,3}, Tzong-Yuan Juang², YU-CHUAN YANG³

¹ Division of plastic and reconstructive surgery, China Medical University Hospital, Taiwan

² Department of Cosmeceutics, China Medical University, Taiwan

³ Department of Medicine, China Medical University, Taiwan

Background: Picosecond laser could produce laser-induced optical breakdown, which might enhance transdermal drug delivery. Fractional CO₂ laser could induce vertically ablated channels that could also help transdermal drug delivery. In addition, we use a kind of self-assembled fucoidan nanoparticle that have autofluorescence to observe the effect of transdermal drug delivery.

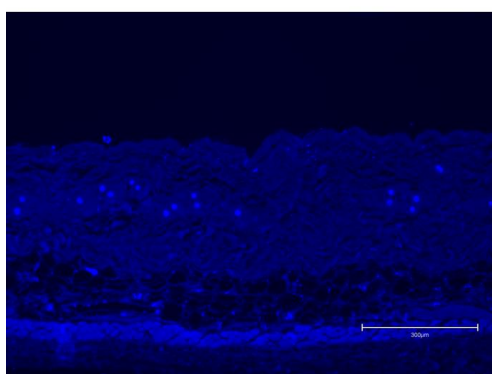
Objective: We want to investigate whether picosecond laser-induced cavitation can serve as a drug reservoir to help nanoparticles remain in the dermis for a longer period. At the same time, we want to know if the nanoparticles can diffuse from the channels induced by CO₂ fractional laser into the surrounding tissues rather than remaining within the channels.

Methods: C57BL/6 were divided into three groups: a picosecond laser group, a CO₂ laser group, and a control group. Each group was treated with nanoparticles self-assembled by dendrimer (PD-ET-12) and fucoidan.

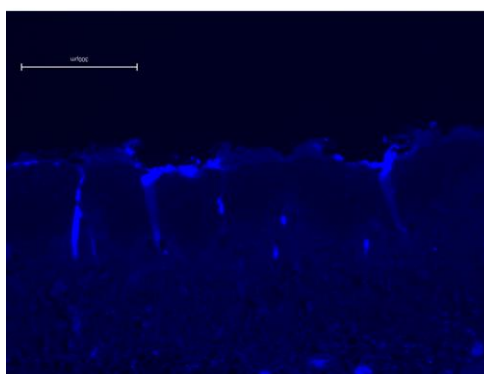
Results: At 0.5 hours, large fluorescent spots can be observed, which could reduce the number of nanoparticles remaining outside the dermis, minimizes drug wastage, and enhance drug delivery efficiency. At 2.0 hours, the fluorescent spots appear smaller but more numerous. At 2.0 hours, a clear contrast can be observed, with the coagulation zones appearing darker and the deeper layers exhibiting more fluorescence.

Conclusion: LIOB could serve as a drug reservoir to help nanoparticles remain in the dermis. Analysis of the fluorescence in tissue sections indicates that nanoparticles can penetrate deeper into the skin when assisted by CO₂ laser treatment.

picosecond laser group at 2.0 hours



CO₂ laser group at 2.0 hours



Oral Presentation | Free paper (Aesthetic surgical procedures)

A34

A treatment plan for orbital aging

Yu Hua

Guangzhou YuhuaMedical Beauty Clinic

Background: Exploration of treatment plans for Asian individuals with congenital flat brow arches, acceptable tightness of the forehead, and sagging upper eyelid skin.

Objective: A treatment method of double eyelid incision eyelid shaping and eyebrow arch filling for orbital aging.

Methods : From January 2022 to January 2024, 105 female patients underwent double eyelid incision eyelid shaping and eyebrow arch filling surgery, including improvement of ptosis of the eyelid tail, eyebrow, eyelid, and zygomatic curves.

Results : 105 patients recovered to normal 4-6 months after surgery, with concealed incisions and significant improvement in orbital aging.

Conclusion : Through double eyelid incision eyelid shaping and eyebrow arch filling surgery, ① reducing surgical incisions, concealing scars, and effectively reducing muscle integrity damage. ② Effectively improve skin laxity around the orbit and increase bone volume around the orbit. It is a safe and effective method of annual orbital rejuvenation treatment.

Oral Presentation | Free paper (Non-surgery)

A35

Bioactive glass in clinical applications

Qian Li, Mei shang

No. 111, Hengda Huafu, Wuling District, Changde City, Hunan Province, China 418000

Objective: Explore the clinical application of regenerative materials
(bioactive glass)

Methods: All patients were treated with bioactive glass and hyaluronic acid
mixture

Results: Using a bioactive glass mixture for treatment in 1500 cases, no
other complications occurred except in 8 cases due to insufficient dose

Conclusion: Bioactive glass is a safe and ideal bony filler

STRATAFIX[®] Spiral PDS PLUS[®]

Smooth and Secure

軟部組織縫合に適したSmoothな組織通過性と
Secureな組織保持をめざしたノットフリー縫合デバイス

高度管理医療機器 販売名: STRATAFIX Spiral PDS プラス 承認番号: 22900BZX00123000

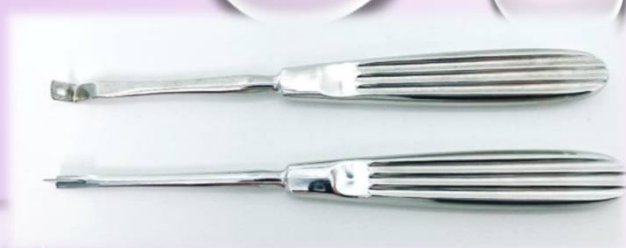ETHICON
Johnson & Johnson SURGICAL TECHNOLOGIES

製造販売元: ジョンソン・エンド・ジョンソン株式会社 メディカルカンパニー
〒101-0065 東京都千代田区西神田 3-5-2 TEL.0120-160-834

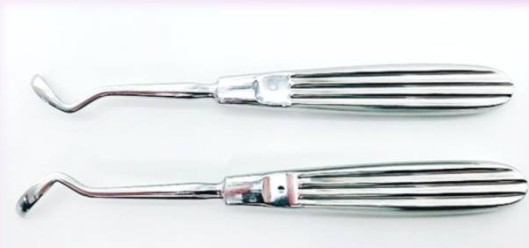Reimagining how we heal™

236310-221222
©J&JKK 2022

肋軟骨採取セット



FMI-000-18
オシレーティングリブカッター
FMI-001-18
レシプロケーティングリブカッター



FMH-200-R
肋軟骨用剝離子 右
FMH-200-L
肋軟骨用剝離子 左

鼻形成セット



M-010-19
直ヤスリ



鼻形成用剪刃




G-190-03
カンバース鉤




FPD-21 ピースエレベーターDナイフ



鼻用ナイフ

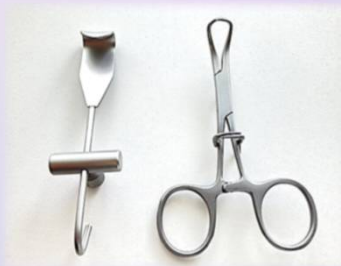

FMO-140-20
スケール



FMO-140-15
鼻用スケール

鼻用フックセット




FMG-250-01
鼻用フックセット

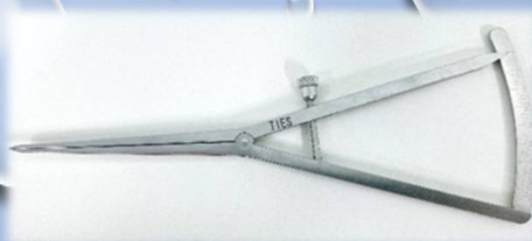

FMG-260-01
重り付き二爪鉤

ロングコンパス



O-011-17 顔面測定用ロングコンパス 曲 17cm



O-010-17 顔面測定用ロングコンパス 17cm

美容医療過誤賠償責任共済

JAAM共済

死亡または
重度の後遺障害の
補償だね



美容皮膚科や小手術、非観血的治療に

一事故
補償限度額

3,000万円



美容外科手術や麻酔行為をされる方に


一事故
補償限度額

1億～3億円 まで

※ 1. ワイドは死亡または後遺障害1～7級、免責100万円

2. ビッグは死亡または後遺障害1～3級、免責300万円

【ご加入条件】 公益社団法人日本美容医療協会への入会が必要です



資料請求・
お問い合わせ

公益社団法人日本美容医療協会 設立の
日本美容医療共済会 事務局

TEL:03-5577-4282
info@jaam-kyosai.jp



弁護士委任ができて
示談までサポート
してくれるのね

美容医療賠償責任保険

『出来栄えのクレーム』や『医療ミスの有無が不明』の場合も
弁護士委任ができる『弁護士費用保険』がセット

支払限度額

弁護士費用保険

1事故 100万円

(免責なし)

医療脱毛、ボトックス・ヒアルロン酸注射、しみ治療、
重瞼術、隆鼻術、上下眼瞼形成、豊胸手術時等の『医療ミス』や
『説明義務違反』による法律上の損害賠償責任を補償

支払限度額

賠償責任保険

1事故 1,000万円

(免責10万円)



資料請求・
お問い合わせ

ユニバーサル少額短期保険株式会社
関東財務局長(少額短期保険) 第33号

TEL:03-5875-1821
info@u-ssi.co.jp



これから鼻再建に取り組もうとしている方、
今まさに取り組んでいる方に！

外鼻の再建 選択肢と考えかた

著：小林誠一郎

定価 19,250 円

(本体 17,500 円＋税 10%)

診断から治療までを、
具体的にわかりやすくまとめました。



創傷治癒の専門家による解説、充実の43項目！

雑誌『形成外科』67巻増刊号

それぞれの 創傷治癒

編集：杠 俊介

定価 6,050 円 (本体 5,500 円＋税 10%)



患者家族目線から、一般医目線、
そして巨匠トリヤベ目線へ！

体験する手外科

第3巻 先天異常・小児疾患編

著：鳥谷部 荘八

定価 19,250 円 (本体 17,500 円＋税 10%)



大人気！！『形成外科』増刊号バックナンバー

66巻 (2023年) 増刊号 形成外科学界未来予想図

65巻 (2022年) 増刊号 今日からの診療に役立つ
ビジュアルでダイレクトに解説する
体表・軟部疾患の検査&臨床画像

64巻 (2021年) 増刊号 形成外科専攻医への推奨論文166選—原典に触れる—

63巻 (2020年) 増刊号 手外科必修ハンドブック
—専門医取得のためのファーストステップ—

62巻 (2019年) 増刊号 形成外科の治療指針 update 2019

既刊も好評発売中！！書籍情報は弊社HPへ

